

Transiliac Leg Lengthening in Poliomyelitis

Taghi Baghdadi*, Javad Gorji, Seyed Mohammad Javad Mortazavi, Mohammad Aref Mohammadi, and Soroush Baghdadi

Department of Orthopaedic, Imam Khomeini Hospital, School of Medicine, Tehran University of Medical Sciences, Tehran, Iran

Received: 1 May 2008; Received in revised form: 7 Jun. 2008; Accepted: 1 Jul. 2008

Abstract- The development and widespread use of a prophylactic vaccine significantly reduced the incidence of poliomyelitis. At present we more commonly encounter with poliomyelitis sequelae especially in developing countries. We evaluate the results of a modified innominate osteotomy for leg length discrepancy in poliomyelitis. Instead of triangular bone graft as in Salter's innominate osteotomy, a trapezoidal bone graft from the ilium is inserted in the site of osteotomy after gradual distraction of the limb. 25 patients (9 males and 16 females) with mean age of 25 years (17-37 years) were treated by this method. All of them had poliomyelitis with limb shortening. At a mean follow-up of 7 years (3 months to 17 years) an average of 3 cm (2.5-3.5) was achieved. Complication was seen in three patients including injury to the lateral cutaneous nerve of thigh and displacement of osteotomy in two patients. Except in one all of the patients satisfied with the operation. We believe this method is safe, effective and cost-benefit for treating of moderate shortening of the lower limb in poliomyelitis.

© 2009 Tehran University of Medical Sciences. All rights reserved.

Acta Medica Iranica 2009; 47(5): 399-401.

Key words: Transiliac leg lengthening, leg lengthening, limb length discrepancy, postural imbalance

Introduction

After introduction and widespread use of poliomyelitis vaccination the incidence of the disease markedly decreased; therefore we more commonly encounter with its sequelae today. Limb shortening is common in these patients. According to Mayer (1931) (1) and Millis and Hall (1979) (2) pelvic obliquity result from unequal leg length, contractures about the hips due to structural scoliosis or a combination of these. Obliquity of the pelvis as a result of limb-length inequality produce abnormality of stance and gait (3-5) that Millis and Hall termed it: postural imbalance in the transverse plane. In classic Salter's innominate osteotomy, an osteotomy through ilium is performed, the osteotomy is opened anteriorly and triangular graft from the same ilium is inserted into the osteotomy. Redirection of the acetabulum is achieved but minimal lengthening is obtained (6) (Figure 1.a). Transiliac leg lengthening first was reported by Millis and Hall (1979) and then by Barry, Mc Manus and O'Brien (1992) (7) who used a modified Salter's innominate osteotomy primarily for lengthening of non-paralytic disorders. Duk Yong Lee *et al.* (1993) used triple innominate osteotomy and transiliac leg lengthening

in 62 patients with unstable hip and limb shortening due to poliomyelitis (8).

In modified innominate osteotomy a trapezoidal bone graft is inserted in osteotomy site; this result in not only lengthening of hemipelvis but also redirection of acetabulum is possible (Figure 1).

We used this method for treating of limb length inequality in 25 patients with poliomyelitis.

To evaluate the limb length post-operatively, we use clinical assessment with blocks under the short leg until a balanced pelvis is obtained (Figure 2).

Results

In our study an average lengthening of 3 cm (2.5-3.5) was achieved.

All patients except one who experienced pin failure and subsequent surgery were satisfied. There were three complications.

The major complication that we encountered was pin failure and displacement of osteotomy. Pin failure and displacement occurred in a 28 years old woman who performed vigorous activity at the second week after operation finally she underwent the second surgery.

*Corresponding Author: Taghi Baghdadi

Department of Orthopaedic, Imam Khomeini Hospital, School of Medicine, Tehran University of Medical Sciences, Tehran, Iran
Tel:+98 21 61192767, Fax:+98 21 66935512, E-mail: taghibaghdadi@hotmail.com

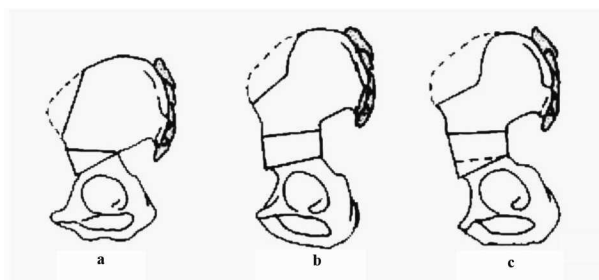


Figure 1. a) Triangular, b) Quadrangular, c) Trapezoidal



Figure 2. Blocks for iliac balance position

Injury to the lateral cutaneous nerve of thigh was seen in one patient that wasn't resolved during 1.5 year follow-up. Osteotomy was displaced in one patient. ultimately she gained 2.5 cm length. She is under follow-up.

There were no other complications such as wound infection, non-union of the osteotomy, osteonecrosis of femoral head and sacroiliac sublocation or dislocation at long-term follow-up.

The range of motion at the hip and knee were not affected. Gait of the patients was improved significantly.

Patients and Methods

Between 1988 and 2005, 25 patients with leg-length inequality operated with transiliac leg lengthening method. All patients had poliomyelitis. Including criteria was patients who had poliomyelitis, no fixed pelvic deformity and shortening of less than five centimeters. Their ages were from 17 to 37 years (average 25.4). There were 16 females and 9 males. The length of follow-up was between 3 months to 17 years (mean 7 years). Their leg-length inequality was measured clinically and by variable sized blocks. The different size block is put under the patients foot until the pelvic is leveled as shown by a balance over the iliac crest then

the measurement of the shortening was recorded (Figure 2).

Operative technique

A modified Salter's innominate osteotomy through modified Smith-Peterson approach was done. After complete of osteotomy, a lamina spreader is inserted into the osteotomy site to open it anteriorly as well as posteriorly and at the same time slow distraction on the limb is applied. A distally directed pressure also is exerted on the iliac crest to protect sacro-iliac joint further. Then trapezoidal shape graft from the same ilium is taken. The height of graft directly superior to center of hip joint should equal to the amount of shortening to achieved exact lengthening. The graft is secured to the ilium with at least two threaded Steinmann pin (3-3.5 mm). The hip is carried gently through its range of motion to rule out penetration of the joint. The wound is irrigated, a suction drain is applied and is closed in a usual manner. 48 hours later the drain is removed and the patient mobilized with crutches and non-weight bearing on the affected side. If it appear cooperative (Figure 3).

Discussion

Transiliac limb lengthening, a modification of Salter's innominate osteotomy is a simple and useful procedure in our hands. There are a number of advantages of this method. It allow immediate, one stage and effective limb-lengthening .because the osteotomy is carried out through cancellous bone, there is rapid healing and incorporation of bone graft. Long bone lengthening in the presence of acetabular dysplasia may decrease further the coverage of the femoral head and increased hip instability (9). In these patients transiliac leg lengthening not only increase the length but also redirect the acetabulum and decrease instability. By improved the patient's gait, the cosmetic effect of limb inequality disappeared.

Millis and Hall believed that up to three centimeters could be gained by transiliac leg lengthening in non-paralytic disorders and stated that iliopsoas tenotomy was mandatory to avoid complications due to excess pressure such as avascular necrosis of the femoral head, however after poliomyelitis the hip is often lax and hypermobile and considerable transiliac lengthening can be achieved safely without iliopsoas tenotomy. We believe there is no requirement for iliopsoas tenotomy in patients with poliomyelitis who undergo transiliac lengthening.

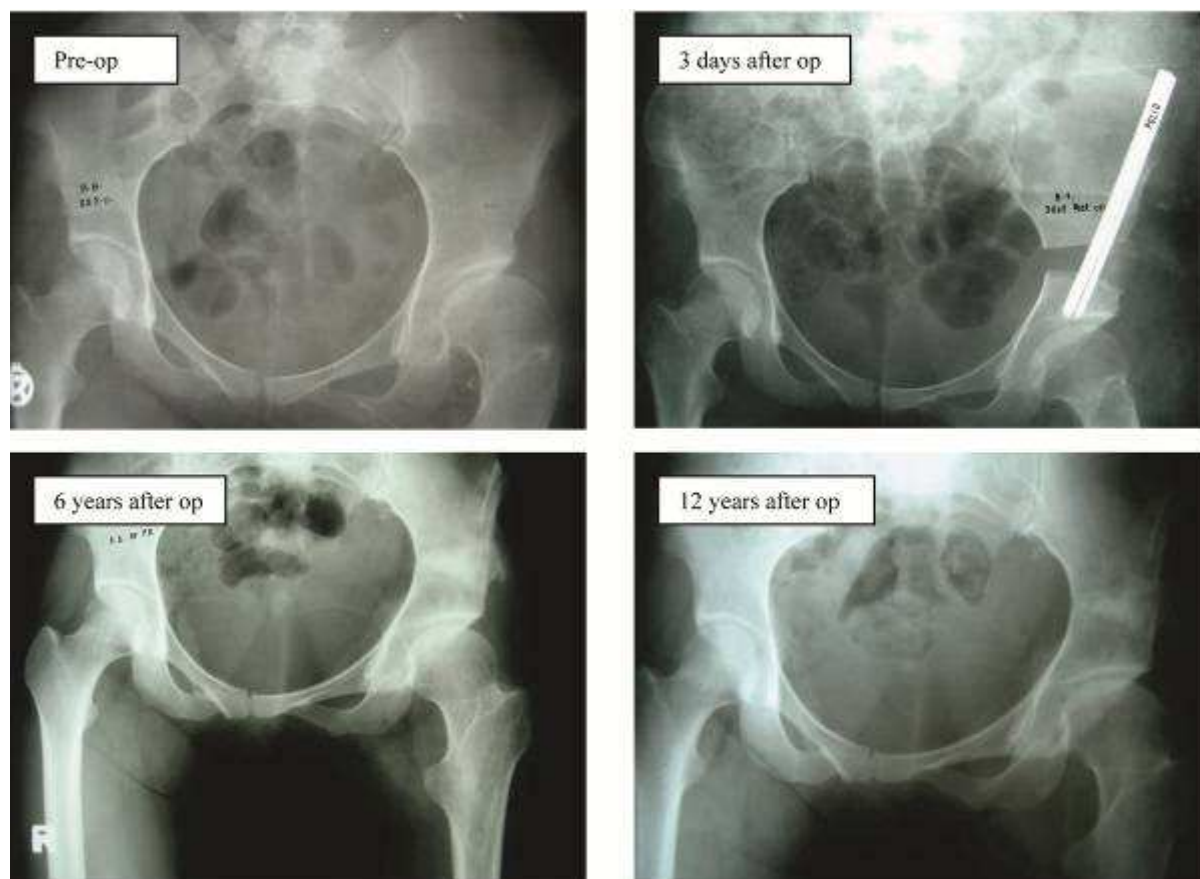


Figure 3. A 23-year old woman with 12 years follow-up

References

1. Mayer L. Fixed paralytic obliquity of the pelvis. *J Bone Joint Surg* 1931;13:1-15.
2. Millis MB, Hall JE. Transiliac lengthening of the lower extremity. A modified innominate osteotomy for the treatment of postural imbalance. *J Bone Joint Surg Am* 1979;61(8):1182-94.
3. Lau JH, Parker JC, Hsu LC, Leong JC. Paralytic hip instability in poliomyelitis. *J Bone Joint Surg Br* 1986; 68(4): 528-33.
4. Lee DY, Choi IH, Chung CY, Cho TJ, Lee JC. Fixed pelvic obliquity after poliomyelitis: classification and management. *J Bone Joint Surg Br* 1997;79(2):190-6.
5. O'Brien JP, Dwyer AP, Hodgson AR. Paralytic pelvic obliquity. Its prognosis and management and the development of a technique for full correction of the deformity. *J Bone Joint Surg Am* 1975;57(5):626-31.
6. Salter RB. The classic. Innominate osteotomy in the treatment of congenital dislocation and subluxation of the hip. *J Bone Joint Surg (Brit)* 1961;3:518.
7. Barry K, McManus F, O'Brien T. Leg lengthening by the transiliac method. *J Bone Joint Surg Br* 1992;74(2):275-8.
8. Lee DY, Choi IH, Chung CY, Ahn JH, Steel HH. Triple innominate osteotomy for hip stabilisation and transiliac leg lengthening after poliomyelitis. *J Bone Joint Surg Br* 1993;75(6):858-64.
9. Paley D. Current techniques of limb lengthening. *J Pediatr Orthop* 1988;8(1):73-92.