

Endoscopic Management of Unusual Metastasis of Renal Cell Carcinoma to the Sinonasal Area

Mohammad Shayani Nasab^{1*}, Mohammad Jafari², Seyed Habibollah Mosavi Bahar³, and Hamid Shayani Nasab³

¹ Department Otolaryngology, Besat Hospital, Hamadan University of Medical Sciences, Hamadan, Iran

² Department Pathology, Ekbatan Hospital, Hamadan University of Medical Sciences, Hamadan, Iran

³ Department Urology, Besat Hospital, Hamadan University of Medical Sciences, Hamadan, Iran

Received: 12 Mar. 2008; Received in revised form: 27 May 2008; Accepted: 1 Jul. 2008

Abstract- Metastatic tumors in the nose and paranasal sinuses are infrequent. The origin of this metastatic tumors are often renal cell carcinoma. We present one case of metastatic renal cell carcinoma to the nose and paranasal sinuses, 4 years after initial nephrectomy and diagnosis of stage T1N0M0 clear cell carcinoma. The patient complained of nasal obstruction and recurrent epistaxis who was treated with endoscopic sinus surgery and was successfully palliated after one year.

© 2009 Tehran University of Medical Sciences. All rights reserved.

Acta Medica Iranica 2009; 47(5): 419-421.

Key words: Metastasis, renal cell carcinoma, management

Introduction

Metastatic tumor to sinonasal region is exceptional. Most common organs responsible for this metastasis are kidney, lungs, breast, GI tract, urogenital tract and thyroid glands (1). Renal cell carcinoma with accounts for 2-3% of all adult malignant neoplasms and is the most lethal urogenital carcinoma. Renal cell carcinoma is frequently seen metastasis in the sinonasal region. Although renal cell carcinoma is notorious (together with malignant melanoma and choriocarcinoma) for metastasizing to the most unusual places, such as the nasal cavity, oral cavity, larynx, parotid, thyroid, heart and pituitary gland (2). According to the significant vascularizations of the tumor, epistaxis is the most common sign of metastasis to sinonasal area (3-5). This article is a report a rare case of metastatic renal cell carcinoma involving the nose and ethmoid sinus, four years after initial nephrectomy which was managed with sinonasal endoscopy.

Case Report

A 52 years old man who initially presented with recurrent nasal bleeding and obstruction. He had an abnormal right nasal mass that suggested tumor. In past medical history he had history of left radical nephrectomy 4 years ago because of renal mass (6 cm in greatest diame-

ter). Renal tumor had been limited within the renal capsule without lymphatic metastasis and vascular invasion (T1N0M0 staging). The diagnosis was clear cell carcinoma according to pathologic examination of the renal mass. To work-up the nasal mass, paranasal CT scan (without contrast) and nasal tumor biopsy was done. CT scan showed soft tissue mass with sinus expansion and destruction (Figure 1). First pathologic examination revealed malignant vascular tumor. Surgery was performed applying intranasal endoscopy and complete tumor resection for nasal bleeding.

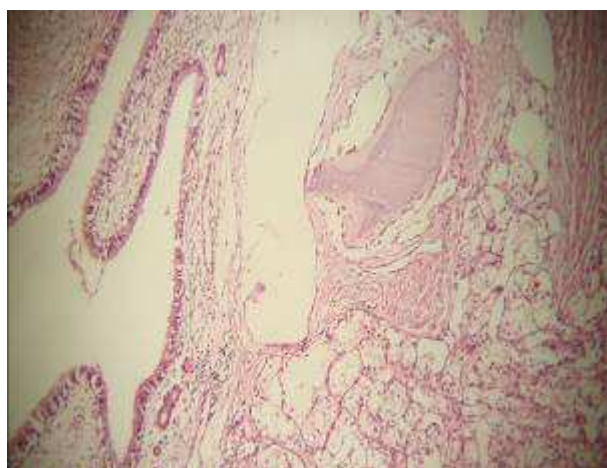


Figure 1. CT Scan of paranasal sinuses revealing right sinonasal mass

*Corresponding Author: Mohammad Shayani-Nasab

Department of Otolaryngology, Besat Hospital, Hamadan University of Medical Sciences and Health Services, Hamadan, Iran
Tel: +98 811 8233383, 918 8142279, Fax: +98 811 2640064, E-mail: drshayani@yahoo.com

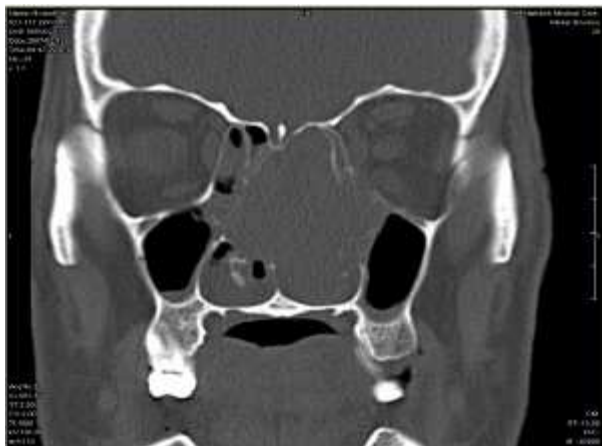

Figure 2. Pathologic finding revealing metastatic clear cell carcinoma in to the nasal wall.

Patient refused more treatment (radiotherapy or chemotherapy and or immunotherapy). Pathologic examination confirmed the diagnosis metastatic renal cell carcinoma since it histologically was similar to the renal cell carcinoma which was previously resected (Figure 2). He achieved a complete clinical response without any significant complication and recurrence of the tumor after 1 year follow up using with interanasal endoscopic examination and study in other organs for metastasis (brain, paranasal, chest and abdominal CT with contrast and bone scan).Nasal biopsy performed 1 year after treatment was negative for malignancy.

Discussion

Approximately one third of patients with renal cell carcinoma have metastatic disease at the time of initial diagnosis (synchronous metastatic disease) and 40-50% will develop distant metastasis after initial diagnosis (6). Renal cell carcinoma can metastasize to any location in the body .The most common sites of metastasis are the lungs, regional lymph nodes, bone and liver. Renal cell carcinoma is most common metastasis tumor to paranasal sinuses and nasal cavity although nasal metastasis is extremely rare (7-9) Renal cell carcinoma has also an occasional presentation as a head and neck mass without evidence of disease elsewhere. Thus renal cell carcinoma should be considered in the diagnosis of nose and paranasal tumors as an origin (10). When a morphologically unusual tumor, especially a glandular neoplasm is encountered in the nasal cavity and paranasal sinuses, the possibility of metastatic disease should be considered and excluded clinically (8). The metastatic deposits from renal cell carcinoma are vascular in nature and can

cause profuse bleeding. The 5-years survival rate after nephrectomy is approximately 60-75% and with multiple metastases is 0-5% (11). Treatment relates to tumor location, size and the general health of the patient. If a patient has a single sinonasal metastasis, surgery is probably the optimal treatment and with multiple metastasis, optimal treatment are radiotherapy, chemotherapy and immunotherapy (12). The clinical course of the primary tumor is often unpredictable, and primary tumors vary in their growth rate .Spontaneous regression has been noted, as has the occurrence of metastasis several years after the primary tumor has been resected (10, 12). Our patient had recurrent disease 4 years after nephrectomy while sinonasal metastatic tumor resection did not show recurrence after 1 year. If a metastatic hypernephroma to the sinonasal tract is the only clinical metastasis,a radical excision of the solitary metastasis, together with a nephrectomy is recommended (13). Although radiotherapy and immunochemotherapy are suggested for metastatic diseases, surgery is perfected in patient with bleeding .Even though many metastatic tumors originating from renal cancer develop multiple metastasis. Most metastatic tumors in the nasal or paranasal sinuses are single and treated surgically. However, even if multiple tumors are found in the nasal and paranasal region and other organs, surgery will be effective in preventing epistaxis and subsequent anemia, In such a situation, local excision of head and neck metastasis of renal cell carcinoma should be performed as a sound treatment regimen not a radical excision to prevent vital structures damage. Although the prognosis for metastatic renal cell carcinoma is poor, our patient had no recurrence during one year of follow-up.

References

1. Godley PA, Stinchcombe TE. Renal cell carcinoma. *Curr Opin Oncol* 1999;11(3):213-7.
2. Marlowe SD, Swartz JD, Koenigsberg R, Zwillenberg S, Marlowe FI, Looby C. Metastatic hypernephroma to the larynx: an unusual presentation. *Neuroradiology* 1993;35(3):242-3.
3. Cheng ET, Greene D, Koch RJ. Metastatic renal cell carcinoma to the nose. *Otolaryngol Head Neck Surg* 2000;122(3):464.
4. Ziari M, Shen S, Amato RJ, Teh BS. Metastatic renal cell carcinoma to the nose and ethmoid sinus. *Urology* 2006;67(1):199.
5. Bernstein JM, Montgomery WW, Balogh K Jr. Metastatic tumors to the maxilla, nose, and paranasal sinuses. *Laryngoscope* 1966;76(4):621-50.

6. Bukowski RM. Natural history and therapy of metastatic renal cell carcinoma: the role of interleukin-2. *Cancer* 1997;80(7):1198-220.
7. Som PM, Norton KI, Shugar JM, Reede DL, Norton L, Biller HF, et al. Metastatic hypernephroma to the head and neck. *AJNR Am J Neuroradiol* 1987;8(6):1103-6.
8. Gottlieb MD, Roland JT Jr. Paradoxical spread of renal cell carcinoma to the head and neck. *Laryngoscope* 1998;108(9):1301-5.
9. Boles R, Cerny J. Head and neck metastases from renal cell carcinoma. *Mich Med* 1971;70:616-8.
10. Terada N, Hiruma K, Suzuki M, Numata T, Konno A. Metastasis of renal cell cancer to the ethmoid sinus. *Acta Otolaryngol Suppl* 1998;537:82-6.
11. Motzer RJ, Mazumdar M, Bacik J, Berg W, Amsterdam A, Ferrara J. Survival and prognostic stratification of 670 patients with advanced renal cell carcinoma. *J Clin Oncol* 1999;17(8):2530-40.
12. Pantuck AJ, Zisman A, Belldegrun A. Gene and immune therapy for renal cell carcinoma. *Int J Urol* 2001;8(7):S1-4.
13. Sgouras ND, Gamatsi IE, Porfyrus EA, Lekka JA, Harkiolakis GC, Nikolopoulou SM, et al. An unusual presentation of a metastatic hypernephroma to the frontonasal region. *Ann Plast Surg* 1995;34(6):653-6.