

Detection of Human Papillomavirus Infection in Inverted Follicular Keratosis Lesions of the Eyelid by Immunohistochemistry Method

Fahimeh Asadi-Amoli, Azadeh Alain, Amir Behzad Heidari*, and Issa Jahanzad

Department of Pathology, Farabi Eye Hospital, School of Medicine, Tehran University of Medical Sciences, Tehran, Iran

Received: 17 Sep. 2008; Received in revised form: 2 Nov. 2008; Accepted: 24 Nov. 2008

Abstract- Inverted Follicular Keratosis (IFK) a benign tumor of skin appendages which is mostly presented as a solitary nodule with keratotic or scaling surface on the face of a middle aged or old patients but it can develop in other parts of the body. Different studies have lead to development of different theories about the role of human papillomavirus (HPV) in this kind of skin tumor. The purpose of this study is to determine the probable role of HPV in this lesion. In a cross-sectional study, we selected all the samples with the diagnosis of IFK referred to pathology department of Farabi Eye Hospital, from April 1995 to April 2006. All these samples were evaluated for histopathologic changes specific for HPV. Immunohistochemistry (IHC) staining was performed using antibody against HPV common antigen. The age range of the patients was 37 to 78 years (Mean=53). 18 patients (58%) were males and 13 patients (42%) were females. The lesion can develop in deferent areas of eyelid. Histopathologic changes regarding viral infection such as focal parakeratosis (80.6%), acanthosis (80.6%), papillomatosis (64.5%), hypergranulosis (67.7%), large keratohyaline granules (32.2%) and koilocytosis (16.1%) were evident within the lesions but HPV detection by IHC revealed positive result in any of the samples. The results about age, sex, anatomic site of the lesion and IHC staining were consistent with previous studies which consider no role for HPV in development of IFK lesions. Performing a more sensitive test such as PCR in order to strongly reject the role of HPV is recommended.

© 2009 Tehran University of Medical Sciences. All rights reserved.

Acta Medica Iranica 2009; 47(6): 435-438.

Key words: Human papillomavirus; keratosis; immunohistochemistry

Introduction

Human papilloma virus (HPV) can play a major role in many benign and malignant tumors of skin as well as other parts of the body such as cervix, anogenital area, oropharyngeal and lungs (1).

Inverted Follicular Keratosis (IFK) a benign tumor of skin appendages which is mostly presented as a solitary nodule with keratotic or scaling surface on the face of a middle aged or old patients but it can develop in other parts of the body. The size of the lesion is normally about 0.3-1 cm and is more frequent in men (2, 3).

Some dermatopathologists categorize it as a distinct lesion but others relate it to verruca vulgaris, seborrheic keratosis or trichilemmoma (4-9).

Histopathologically reveals as an endophytic tumor with large lobules or filiform projections of tumoral cells which progress toward the dermis. Exophytic growth is also detectable in some lesions and might be the dominant presentation of the disease. Each tumoral

lobule is made of basaloid and squamous cells the way that basaloid cells are located in periphery and larger keratinized cells in the central areas. A distinct microscopic feature is the squamous eddies in which whorled layers of squamous cells are evident and may lead to keratinization by producing keratohyalin or sometimes keratin spots in the center of these islands (2).

Different studies have lead to development of different theories about the role of HPV in this kind of skin tumor. Some of them believe in the role of HPV and others were unable to find it (3, 10-15).

HPV can have different cytopathic effects on the lesions it induce. These effects are usually seen in the cells of squamous layer as papillomatosis, acanthosis, focal parakeratosis especially on the tip of pappies, large keratohyaline granules and koilocytosis (3, 16).

In addition to evaluation of histopathologic effects of HPV on skin lesions, different methods such as immunohistochemistry (IHC), Insitu Hybridization (ISH), Polymerase chain reaction (PCR) and Electron Micro-

*Corresponding Author: Amir Behzad Heidari

Department of Pathology, Farabi Eye Hospital, School of Medicine, Tehran University of Medical Sciences, Tehran, Iran
Tel: +98 912 1150088, Fax: +98 21 88953010, E-mail: amirbehzad@yahoo.com

scope are used for its detection. Regarding the controversy about the role of HPV in different studies and also lack of such study in Iran, aside from evaluation of age, gender and histopathologic effects of HPV in IFK, we decided to detect the virus by IHC method.

Patients and Methods

In a cross-sectional study, we selected all the samples with the diagnosis of IFK referred to pathology department of Farabi Eye Hospital, from April 1995 to April 2006. We found 31 samples with diagnosis of IFK and adequate amount of material for IHC. All these samples were evaluated for histopathologic changes specific for HPV such as papillomatosis, acanthosis, and focal parakeratosis on the surface of papillae, large keratohyaline granules and koilocytosis. Then we provided some sections from paraffin embedded samples and IHC staining was performed for them. All the 31 samples were stained for IHC by avidin-biotin peroxidase complex method (using polyvalent HPV antibodies of rabbit, Signet Co.)

A sample of plantar wart and a sample of normal skin were chosen for control positive and negative respectively (Figure 1).

Results

The age range of the patients was 37 to 78 years, with a mean of 53 years. 3 patients (9.7%) were under 40 years, 22 patients (71%) were 40-60 and 6 patients (19.3%) were above 60. 18 patients (58%) were males and 13 patients (42%) were females.

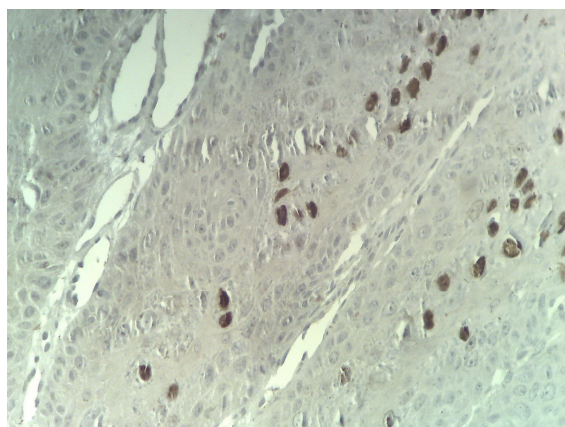


Figure 1. Common wart , a positive nuclear staining for IHC staining , $\times 400$

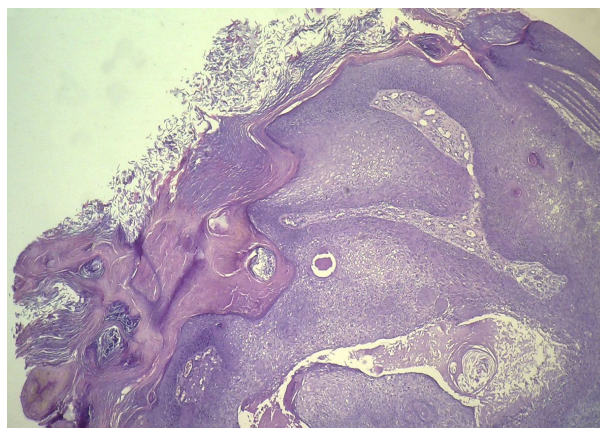


Figure 2. Inverted follicular keratosis of eyelid , H & E staining , $\times 100$

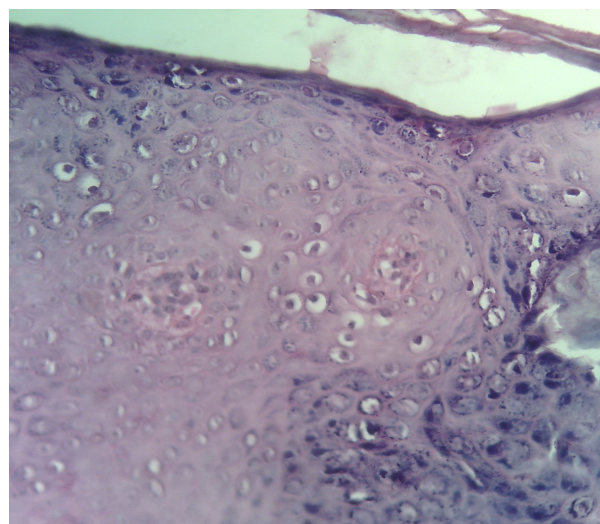


Figure 3. Viral infection changes in the epidermis , koilocytes , H & E staining $\times 400$

The anatomic site of the lesion on the lids was right upper lid in 8 (25.8%), right lower lid in 7 (22.6%), left upper lid in 5 (16.1%) and left lower lid in 7 (22.6%) patients. No data about the anatomic location of the lesion was found in the profiles of 4 (12.9%) of patients.

In histopathologic evaluation of the samples for changes regarding viral infection, 25 (80.6%) samples had focal parakeratosis especially on the surface of papillae, 25 (80.6%) acanthosis, 20 (64.5%) papillomatosis, 12 (67.7%) hypergranulosis, 10 (32.2%) large keratohyaline granules and 5 (16.1%) koilocytosis within the lesion (Figure 2 and 3). In HPV detection by IHC, positive result was found in none of the samples (Figure 4).

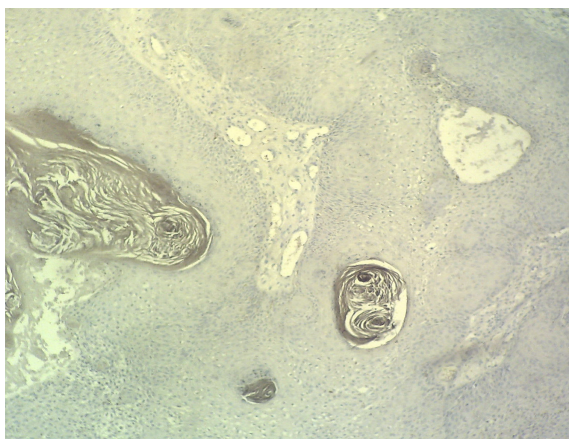

Figure 4. Negative staining for HPV infection, inverted follicular keratosis of eyelid (IHC staining $\times 100$)

Discussion

Generally IFK is a rare lesion (15, 17) and this is exactly the same for our samples (31 cases in 11 years). In age category there was an age range of 37-78 (mean = 53) which was the same as other studies (range=36-77 and mead=53) who relate the disease to middle and old age (2, 15, 16).

In the sex category 18 (58%) of patients were males and 13 (42%) were females which is the same as other studies who proved higher incidence in men (2, 15, 16).

Results about the anatomic site of the lesion prove that the lesion can develop in different sites of the eye lid and like other studies we are unable to prove any higher chance of incidence in a specific anatomic site.

According to different studies, IHC has a sensitivity of 52-87% for the detection of HPV (14, 18-20). Using IHC staining test we could detect HPV in none of the samples which was the same result as other studies (3, 13, 15). Based on current study and other studies we can suggest no role for HPV in development of IFK. But a study on 13 cases of condyloma acuminata and comparison of different HPV detection methods revealed 69% HPV detection for IHC, 77% for ISH and 100% for PCR. So regarding the all-negative result of current study and presence of HPV specific histopathologic changes in some cases (parakeratosis, papillomatosis, hypergranulosis, large hyaline granules and koilocytosis) we recommend to perform a more sensitive test such as PCR in order to strongly reject the role of HPV in IFK lesions.

References

1. Xu X, Erickson LA, Elder DA. Diseases caused by viruses. In: Elder DE, Elenitsas R, Johnson BL Jr, Murphy GF, edi-

- tors. *Lever's Histopathology of the Skin*. 9th ed. Philadelphia: Lippincott Williams and Wilkins; 2005. p. 661-79.
2. Weedon D. Tumors of cutaneous appendages. In: Weedon D. *Skin Pathology*. 2nd ed. Edinburgh: Churchill Livingstone; 2002. p. 867.
3. Ruhoy SM, Thomas D, Nuovo GJ. Multiple inverted follicular keratoses as a presenting sign of Cowden's syndrome: case report with human papillomavirus studies. *J Am Acad Dermatol* 2004;51(3):411-5.
4. Ackerman AB, De viragh PA, chonchitnant N. Inverted follicular keratosis. Neoplasms with follicular differentiation. Philadelphia: Lea and Febiger; 1993. p. 309-29.
5. Azzopardi JG, Laurini R. Inverted follicular keratosis. *J Clin Pathol* 1975 Jun;28(6):465-71.
6. Lever WF. Inverted follicular keratosis is an irritated seborrheic keratosis. *Am J Dermatopathol* 1983; 5(5): 474.
7. Lund HZ. The nosologic position of inverted follicular keratosis is still unsettled. *Am J Dermatopathol* 1983;5(5):443-5.
8. Spielvogel RL, Austin C, Ackerman AB. Inverted follicular keratosis is not a specific keratosis but a verruca vulgaris (or seborrheic keratosis) with squamous eddies. *Am J Dermatopathol* 1983;5(5):427-42.
9. Mehregan AH. Inverted follicular keratosis is a distinct follicular tumor. *Am J Dermatopathol* 1983;5(5):467-70.
10. Hori K. Inverted follicular keratosis and papillomavirus infection. *Am J Dermatopathol* 1991;13(2):145-51.
11. Boniuk M, Zimmerman LE. Eyelid tumors with reference to lesions confused with squamous cell carcinoma. II. Inverted follicular keratosis. *Arch Ophthalmol* 1963;69:698-707.
12. Reed RJ, Pulitzer DR. Inverted follicular keratosis and human papillomaviruses. *Am J Dermatopathol* 1983;5(5): 453-65.
13. Shih CC, Yu HS, Tung YC, Tsai KB, Cheng ST. Inverted follicular keratosis. *Kaohsiung J Med Sci* 2001;17(1):50-4.
14. Mehregan AH, Nadji M. Inverted follicular keratosis and verruca vulgaris. An investigation for the papillomavirus common antigen. *J Cutan Pathol* 1984;11(2):99-102.
15. Lee IW, Choi EH, Ahn SK, Lee WS, Lee SH, Lee DW. Clinical features and detection of human papillomavirus in inverted follicular keratosis. *Korean J Dermatol* 1997; 35(6):1074-81.
16. Elder DE, Elenitsas R, Johnson BL Jr, Murphy GF. Algorithmic classification of skin disease for differential diagnosis. In: Elder DE, Elenitsas R, Johnson BL Jr, Murphy GF, editors. *Lever's Histopathology of the Skin*. 9th ed. Philadelphia: Lippincott Williams & Wilkins 2005; p. 75-138.

Human papillomavirus infection in inverted follicular keratosis lesions

17. Mencía Gutiérrez E, Gutiérrez Díaz E, Ricoy JR, Gómez Ledesma I, Monescillo J, García Torre JP. Benign hair-follicle derived eyelids tumors in adults. *Arch Soc Esp Oftalmol* 2002;77(11):605-10.
18. Sehgal VN, Koranne RV, Srivastava SB, Gupta MM, Luthra UK. Clinicopathology and immunohistochemistry of genital warts. *Int J Dermatol* 1988;27(10):690-4.
19. Penneys NS, Mogollon RJ, Nadji M, Gould E. Papillomavirus common antigens. Papillomavirus antigen in verruca, benign papillomatous lesions, trichilemmoma, and bowenoid papulosis: an immunoperoxidase study. *Arch Dermatol* 1984;120(7):859-61.
20. Schadendorf D, Tiedemann KH, Haas N, Czarnetzki BM. Detection of human papillomaviruses in paraffin-embedded condylomata acuminata: comparison of immunohistochemistry, in situ hybridization, and polymerase chain reaction. *J Invest Dermatol* 1991;97(3):549-54.