

Clinical Feature of Extranodal Presentation of Non Hodgkin Lymphoma in Head and Neck

Ebrahim Razmpa* and Babak Saedi

Department of Otolaryngology, School of Medicine, Tehran University of Medical Sciences, Tehran, Iran

Received: 5 Jan. 2008; Received in revised form: 12 Jun. 2008; Accepted: 29 Jul. 2008

Abstract- Non Hodgkin lymphoma (NHL) constitutes 5% of all head & neck cancer. The incidence of it has been increased over the last four decades. One of main characteristic of NHL is extranodal presentation that has different pattern in various part of world. A retrospective was designed in a tertiary referral center. It has been done between January 1996 and March 2006. All clinical and pathological characteristics were evaluated. 129 patients were included in this study, 89 male and 49 female. The mean age was 49 year. The most common site of involvement was Waldeyer's ring and the most common presenting symptom was cervical mass. 48% of patients had lymphadenopathy and 12% had B symptom. The most common histologic type was diffuse large cell lymphoma. In our series male to female ratio was 2.2 that are more than other studies. It seems that extranodal presentation is more common in Iranian patients than other population.

© 2009 Tehran University of Medical Sciences. All rights reserved.

Acta Medica Iranica 2009; 47(6): 489-492.

Key words: Head & neck neoplasms; lymphoma; lymphoma, non-Hodgkin

Introduction

Lymphomas are a group of lymph proliferative disorders that can be classified in two main ways: histological and immunophenotypic. Histological classification subdivides lymphomas in the two main groups of Hodgkin's and non-Hodgkin's lymphomas, depending on whether the large multinucleated Reed-Sternberg cells are present (1). Reed-Sternberg cells are characteristic of Hodgkin's lymphoma. Non Hodgkin lymphoma (NHL) constitutes 5% of all head and neck cancer. The incidence of it has been increased over the last four decades. These diseases usually present with painless lymphadenopathy, the signs and symptoms of a non-Hodgkin's lymphoma may be similar to those of a head and neck squamous cancer, and only the distinction can be made by biopsy, but non-Hodgkin's lymphomas can present with extranodal masses, which most frequently occur in Waldeyer's ring (1) Salivary glands can also be affected, and non-Hodgkin's lymphomas may arise from aggregates of lymph tissue within the gland or from malignant transformation in a myoepithelial sialadenitis (2, 3). The localization of tumor presentation by site reveals tonsil to be the most common, followed by nasopharynx, oral cavity, salivary Glands, paranasal sinuses and base of tongue.

Long-term results in patients presenting with extranodal lymphomas in the head and neck area vary greatly, depending not only on histology, but also on sites of presentation although many studies describing the clinical and histopathologic features of PE-NHL had been published, there are still insufficient data about general characteristics and geographic variations of PE-NHL (3,4-6). These are defined as primary extranodal-NHLs (PE-NHLs) and constitute about 35% of NHLs with a considerable wide range of 24%–48%, which may reflect geographic variations.

So we designed a retrospective study to evaluate the clinical and histopathologic characteristics of patients with PE-NHL (extranodal presentation of non Hodgkin lymphoma) in Iran.

Patients and Methods

In the present study, the data from 129 consecutive cases of NHL registered in one tertiary referral center (Imam Khomeini hospital) between January 1996 and March 2006 were analyzed. The study design was retrospective. Patients with mycosis fungoides, Sezary's syndrome, acute lymphocytic leukemia and chronic lymphocytic leukemia were excluded. There has been some contro-

*Corresponding Author: Ebrahim Razmpa

Department of Otolaryngology, School of Medicine, Tehran University of Medical Sciences, Tehran, Iran
Tel: +98 21 66932288, Fax: +98 21 66932288, E-mail: info@razmpa.com

Clinical feature of non hodgkin lymphoma in head and neck

versy in the literature about the definition of PE-NHLs. We adapted Isaacson's definition for our cases (7, 8). According to that definition, lymphomas were considered to be extranodal if they presented with predominant disease at any extranodal site and needed direct treatment to that site. Waldeyer's ring, which constitutes the palatine, lingual, pharyngeal, and tubal tonsils, was considered to be an extranodal site. 15 patients with nodal first presentation or the head and neck presentation is secondary to other sites involvement was excluded. We used patients' history and pathologic notes for data collections. Our researched variables were age, sex, clinical presentation, first site of involvement, and pathologic type. Diagnosis was made of endoscopic and/or surgical biopsies. Histopathologic classification was done according to the Working Formulation All calculations were performed using the SPSS 6.0 for Windows statistical package. This research was approved with ethic committee of Tehran University and the patients' information will be confidential in this survey.

Results

129 patients were evaluated in this study. The mean age was 49 (SD = 8.7) with the range 5 and 88. The most common group was between 50 and 60. The disease was more common in man than women and male to female ratio was 69% to 31%, there was 89 male and 40 female in studied group. The most of our patients live in central part of country. Neck mass was the most common presentation in the studied group, the other presentations were summarized in the table 1.

The mean duration before diagnosis was 5.2 (SD = 1.3) month. 48% of them had lymphadenopathy and 12% had B symptoms (fever more than 38 °C, night sweating, and weight loss more than 10% in 6 month).

The most common sites of involvement in head and neck were waldeyer's ring, sinonasal, and salivary gland. 2 patients with NHL that presented in tonsil after a short period showed GI involvement and may be related to MALToma.

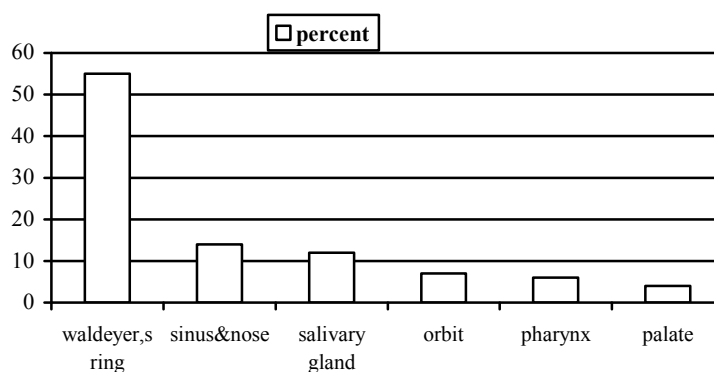


Figure 1. Site of involvement

Table 1. clinical presentation

Clinical presentation	percent	Clinical presentation	percent
Neck mass	31	Hearing loss	2.3
Throat bulging	26.4	Epistaxis	2.3
Cheek bulging	18.6	Hyper nasal speech	2.3
Dysphagia	16.3	Palatal mass	2.3
Nasal obstruction	13.2	Visual problem	2.3
Throat pain	11.6	Epiphora	2.3
Mandibular bulging	9.3	Airway obstruction	2.3
proptosis	7	Dysphonia	1.6
Otalgia	3.1	Tongue mass	0.8

Table 2. Pathologic type

Pathologic type	Percent
Diffuse large cell	64.3
Diffuse mixed cell	10.9
Diffuse small cell	9.3
Small lymphocytic	1.6
Immunoblastic	1.6
lymphoblastic	1.6
Immunocytic	0.8
Marginal zone	0.8
Burkitt	0.8

The most prevalent pathologic type was diffuse large cell lymphoma, and the other common pathological type was showed in table 2. 84% of patient had moderate degree of differentiation, 3.9% high grade, and 3.1% low grade.

70 % of researched group were in stage I, II at time of diagnosis and others in higher stage.

Discussion

This study analyzes epidemiologic characteristic, clinical presentation, histopathologic, and distribution of primary extra nodal lymphomas in one tertiary referral center in Iran In the first study, Waldeyer's ring was classified as a nodal site, but the second trial included them as PE-NHLs.

In the Middle East, PE-NHLs constitute more than 40% of all NHLs (9). One explanation for this relatively high incidence is increased frequency of gastrointestinal lymphomas in the Middle East. Primary gastrointestinal lymphomas comprise 46.5% of PE-NHLs in Lebanon, whereas this ratio is 20% to 36% in Western countries (1, 10). In our cases the percentage of primary gastrointestinal lymphomas was only 2 patients but because of limitation of this research we can not compare it to 61%, which is the usual rate in the Middle East. Within primary gastrointestinal lymphoma, gastric lymphoma is three times more common than small intestinal lymphoma in the West, whereas the reverse is true in the Middle East. There was only one case with small intestinal lymphoma developing secondary to IPSID.

The male/female ratio was about 2.2 in our cases. Female predominance was mentioned in some studies but in other reports were equal or a little more. This finding (M/F = 2.2) is inconsistent with the most data in the literature (9, 11).

Mean ages of the patients were 49 year but in other reports are 55, 58, and 77 the youngest cases in this study were the patients with testis lymphoma. It seems

that our patients at least 6 years younger than the other one(9) The most common group in our series was between 50 and 60 but this different in other studies that reported that twenty six to fifty years old was the most common age range (12, 13).

The most common clinical presentation in studied group was neck mass like other studies in literature, so we should consider lymphoma in differential diagnosis in every body that referred with neck mass (14, 15).

The incidence of lymphadenopathy in this group was 48% and in other research are 50% and 47% (22, 23) comparing B symptom in our patients and other studies show that these symptoms are less frequent. (12% and 15% -20%) (16, 17).

The most common extranodal presentation was waldeyer's ring involvement that is similar to other series.

Histopathologic examination revealed diffuse large cell lymphoma is the most common pathologic type. Diffuse large cell lymphoma was more common in other studies and so that is compatible with other results (18-20). 85% of our patients had moderate grading based on WF (working formulation); this data is very similar to other researches (9, 19, 20).

Based on patients' history 70% of NHL in our center treated in stage I or II, but this is more higher in other centers 75% (4, 21), 90% (3).

However, selection bias should be taken into account during the assessment of retrospective studies. The results of the ongoing prospective randomized studies might be more informative on the standard treatment of PE-NHLs.

References

- Freeman C, Berg JW, Cutler SJ. Occurrence and prognosis of extranodal lymphomas. *Cancer* 1972;29(1):252-60.
- Salem P, Anaissie E, Allam C, Geha S, Hashimi L, Ibrahim N, et al. Non-Hodgkin's lymphomas in the Middle East. A study of 417 patients with emphasis on special features. *Cancer* 1986;58(5):1162-6.
- Reddy S, Pelletiere E, Saxena V, Hendrickson FR. Extranodal non-Hodgkin's lymphoma. *Cancer* 1980;46(9):1925-31.
- Ree HJ, Rege VB, Knisley RE, Thayer WR, D'Amico RP, Song JY, et al. Malignant lymphoma of Waldeyer's ring following gastrointestinal lymphoma. *Cancer* 1980;46(7):1528-35.
- Duncan PR, Checa F, Gowing NF, McElwain TJ, Peckham MJ. Extranodal non-Hodgkin's lymphoma presenting in the testicle: a clinical and pathologic study of 24 cases. *Cancer* 1980;45(7):1578-84.

Clinical feature of non hodgkin lymphoma in head and neck

6. Shima N, Kobashi Y, Tsutsui K, Ogawa K, Maetani S, Nakashima Y, et al. Extranodal non-Hodgkin's lymphoma of the head and neck. A clinicopathologic study in the Kyoto-Nara area of Japan. *Cancer* 1990;66(6):1190-7.
7. Tondini C, Giardini R, Bozzetti F, Valagussa P, Santoro A, Bertulli R, et al. Combined modality treatment for primary gastrointestinal non-Hodgkin's lymphoma: the Milan Cancer Institute experience. *Ann Oncol* 1993;4(10):831-7.
8. Zinzani PL, Magagnoli M, Ascani S, Ricci P, Poletti V, Gherlinzoni F, et al. Nongastrointestinal mucosa-associated lymphoid tissue (MALT) lymphomas: clinical and therapeutic features of 24 localized patients. *Ann Oncol* 1997;8(9):883-6.
9. Arican A, Dinçol D, Akbulut H, Onur H, Demirkazik A, Cay F, et al. Clinicopathologic features and prognostic factors of primary extranodal non-Hodgkin's lymphomas in Turkey. *Am J Clin Oncol* 1999;22(6):587-92.
10. Economopoulos T, Asprou N, Stathakis N, Papageorgiou E, Dervenoulas J, Xanthaki K, et al. Primary extranodal non-Hodgkin's lymphoma in adults: clinicopathological and survival characteristics. *Leuk Lymphoma* 1996;21(1-2):131-6.
11. d'Amore F, Christensen BE, Brincker H, Pedersen NT, Thorling K, Hastrup J, et al. Clinicopathological features and prognostic factors in extranodal non-Hodgkin lymphomas. Danish LYFO Study Group. *Eur J Cancer* 1991;27(10):1201-8.
12. Zhou J, Wei L, Cao Y. Analysis on clinical and immunohistochemical characteristics of primary extranodular non-Hodgkin's lymphoma in otolaryngol head and neck. *Lin Chuang Er Bi Yan Hou Ke Za Zhi* 2003;17(12):724-6.
13. Goldwein JW, Coia LR, Hanks GE. Prognostic factors in patients with early stage non-Hodgkin's lymphomas of the head and neck treated with definitive irradiation. *Int J Radiat Oncol Biol Phys* 1991;20(1):45-51.
14. Enrique A, Quesada JL, Lorente J, López D. Hodgkin and Non-Hodgkin lymphomas in otorhinolaryngology. *Acta Otorrinolaringol Esp* 2004;55(8):387-9.
15. DePeña CA, Van Tassel P, Lee YY. Lymphoma of the head and neck. *Radiol Clin North Am* 1990;28(4):723-43.
16. Zucca E, Roggero E, Bertoni F, Conconi A, Cavalli F. Primary extranodal non-Hodgkin's lymphomas. Part 2: Head and neck, central nervous system and other less common sites. *Ann Oncol* 1999;10(9):1023-33.
17. Yuen A, Jacobs C. Lymphomas of the head and neck. *Semin Oncol* 1999;26(3):338-45.
18. Nayak LM, Deschler DG. Lymphomas. *Otolaryngol Clin North Am* 2003;36(4):625-46.
19. Ezzat AA, Ibrahim EM, El Weshi AN, Khafaga YM, Al-Jurf M, Martin JM, et al. Localized non-Hodgkin's lymphoma of Waldeyer's ring: clinical features, management, and prognosis of 130 adult patients. *Head Neck* 2001;23(7):547-58.
20. Yuen A, Jacobs C. Lymphomas of the head and neck. *Semin Oncol* 1999;26(3):338-45.
21. Sarpel SC, Paydas S, Tuncer I, Varinli S, Koksall M, Akoglu T. Non-Hodgkin's lymphomas in Turkey. *Cancer* 1988;62(8):1653-7.