

Dicrocoeliiasis with Signs of Chronic Diarrhea

Mohsen Mahmoodi¹, Ali Reza Zahraei Ramazani², Shahrokh Izadi*¹, and Jamshid Najafian³

¹ Department of Medical Parasitology and Mycology, Isfahan Health Researches and Training Center, Institute of Public Health, Tehran University of Medical Science, Isfahan, Iran

² Department of medical Entomology and Vector Control, Isfahan Health Researches and Training Center, Institute of Public Health, Tehran University of Medical Science, Isfahan, Iran

³ Amin Research Center, Isfahan University of Medical Science, Isfahan, Iran

Received: 17 Nov. 2008 ; Received in revised form: 9 Jan. 2009; Accepted: 16 Feb. 2009

Abstract- A case who was suffering from abdominal pain and chronic diarrhea referred to Isfahan Health Training and Research Center, Institute of Public Health. Current treatments for chronic diarrhea including a trial of gluten free diet were performed but these were not effective because he was infected by *Dicrocoelium dentriticum*. Then he was cured with parasitic treatment.

© 2010 Tehran University of Medical Sciences. All rights reserved.
Acta Medica Iranica 2010; 48(3): 198-199.

Key words : Dicrocoelium; Gluten sensitive enteropathy; diarrhea

Introduction

Dicrocoelium dentriticum (the lancet fluke) is ordinary in the bile ducts of most herbivorous animals e.g. cattle, sheep, goats and pigs and it is less common liver parasite in human. Adults inhabit bile duct while characteristic eggs pass in stools. The parasite is reported from most part of Europe and Asia and also has foci in North America and Australia. It's life cycle is similar to the other liver flukes such as *Fasciola hepatica* but it encysts in ant, the secondary intermediate host. True cases of human infection with the Lancet Fluke arise when people-accidentally or deliberately-eat ants. Most cases of *dicrocoeliiasis* are asymptomatic but in heavy infestations vague, abdominal complain, vomiting, diarrhea or constipation and biliary colic have been observed(1-5).

Case Report

His symptoms and signs were controlled by these drugs but after a trip to Southern regions of Iran diarrhea increased severely and did not respond to the previous drugs. The serum level of bilirubin was slightly raised to 1.14 mg/dl (<1.10 mg/dl) and the level of IgE was raised to 215 U/ml (<100 U/ml). There is not abnormality in other lab findings .At the first ,stool examination was negative for ova and parasite. Empirical treatment for

Giardia had no effect on clinical signs and symptoms. Barium enema was performed and a feathery appearance in the end of ileum was seen. Due to the patient refusing, endoscopy for mucous biopsy of the small bowel didnot achieved. A gluten free regime began and consequently the symptoms and signs decreased. After two months diarrhea was begun again and did not respond to this regime. The patient denied consumption of liver or liver products within the past weeks.Spurous infection due to eating infected liver could thus excluded. Then stool examination(three times) revealed dicrocoelium ova.

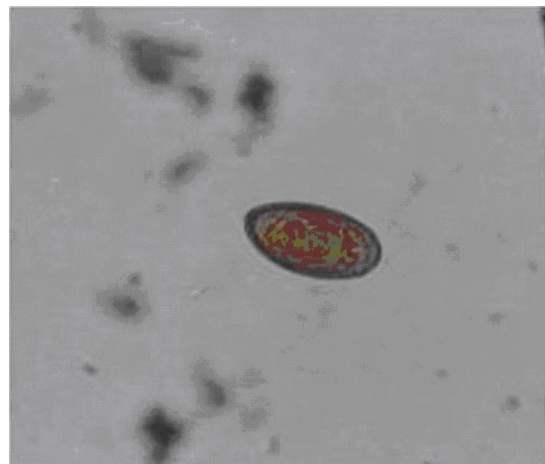


Figure 1. Microphotography of *Dicrocoelium* with signs of Chronic Gluten Sensitive Diarrhea in Isfahan city, central of Iran (High in magnification)

*Corresponding Author: Shahrokh Izadi

Department of medical Parasitology and Mycology, Isfahan Health Researches and Training Center, Institute of Public Health, Tehran University of Medical Science, Isfahan, Iran

Tel: +98 311 5512955, 913 1005233, Fax: +98 311 5512944, E-mail: Shahrokh_Izadi@yahoo.com

Treatment was begun with Bithionol (Praziquantel was not accessible) and then further stool examinations for parasites were negative and diarrhea was disappeared. The patient began to consume bread without any side effect. One year following up has not shown any clinical signs and symptoms of the disease

Discussion

Although most episodes of diarrhea are acute and completely resolve, diarrhea may persist and be associated with abdominal pain or other symptoms. If diarrhea lasts more than two weeks, such as our case, we call it chronic diarrhea. Chronic diarrhea is most likely to Inflammatory Bowel Disease (IBD). Other less common causes including ischemia of the gut, infections like viruses, bacteria and parasites and radiation therapy and colon cancer or polyps. Also one of the other important causes is Gluten Sensitive. Traveling to contaminated areas and eating contaminated foods ,such as vegetables and bread can result in exposure to pathogens and cause diarrhea.

Endoscopic examination of the colon with flexible sigmoidoscopy and colonoscopy is more specific than radiographic studies, including an upper GI series or barium enema, in detecting of chronic diarrhea. On account of this report, it should be better to perform a

parasitic examination to detection of pathogenic gastrointestinal parasites particularly in chronic Diarrhea before other paraclinical examinations.

Acknowledgements

The authors wish to thanks member of parasitology and mycology laboratory of Isfahan Health Researches and Training Center also we grateful to the patient and his family for their participation .

References

1. Arfaa F. Report of one human *Dicrocoelium* from Gonbad region, Iran. *Iran J Publ Health* 1977; 6:3-4.
2. Farid H. Human infection with *Fasciola hepatica* and *Dicrocoelium dendriticum* in Isfahan area, central Iran. *J Parasitol* 1971; 57:1
3. Roche P.J.L. Human dicrocoeliasis in Nigeria. *Trans Roy Soc Trop Med Hyg* 1948; 41: 819-20.
4. Rack J, Adusu E, Jelinek T. Human infection with *Dicrocoelium dendriticum*. *Deutsche Medizinische Wochenschrift* 2004; 129: 2538-40.
5. Schmidt GD, Roberts LS. *Dicrocoelium dendriticum*. *Foundation of Parasitology*. 4th ed. 1986.