

# Brain Single Photon Emission Computed Tomography in Anosmic Subjects after Closed Head Trauma

Hooshang Gerami<sup>1</sup>, Shadman Nemati<sup>1</sup>, Farzad Abbaspour<sup>2</sup>, and Roozbeh Banan<sup>1</sup>

<sup>1</sup> Department of Otolaryngology- Head & Neck Surgery, Guilan University of Medical Sciences, Guilan, Iran

<sup>2</sup> Department of Nuclear medicine, School of Medicine, Guilan University of Medical Sciences, Guilan, Iran

Received: 10 Dec. 2009; Received in revised form: 17 Jun. 2010; Accepted: 7 Oct. 2010

**Abstract-** Anosmia following head trauma is relatively common and in many cases is persistent and irreversible. The ability to objectively measure such a decline in smelling, for both clinical and medicolegal goals, is very important. The aim of this study was to find results of brain Single Photon Emission Computed Tomography (SPECT) in anosmic subjects after closed head trauma. This case-control cross sectional study was conducted in a tertiary referral University Hospital. The brain perfusion state of nineteen anosmic patients and thirteen normal controls was evaluated by means of the SPECT with 99mTc- ECD infusion- before and after olfactory stimulation. The orbitofrontal lobe of the brain was assumed as the region of interest and changes in perfusion of this area before and after the stimulations were compared in two groups. The mean of brain perfusion in controls before and after the stimulation was  $8.26\% \pm 0.19\%$  and  $9.89\% \pm 0.54\%$ , respectively ( $P < 0.0001$ ). Among patients group, these quantities were  $7.97\% \pm 1.05\%$  and  $8.49\% \pm 1.5\%$ , respectively ( $P < 0.004$ ). The difference between all the measures in cases and controls were statistically significant ( $P < 0.0001$ ). There were no differences in age and sex between two groups. The brain SPECT is an objective technique suitable for evaluating anosmia following the head trauma and it may be used with other diagnostic modalities.

© 2011 Tehran University of Medical Sciences. All rights reserved.

*Acta Medica Iranica*, 2011; 49(1): 13-17.

**Keywords:** Anosmia; Tomography, emission-computed, single-photon; Brain; Perfusion; Craniocerebral trauma

## Introduction

Olfactory sensation is an unknown-mysterious sense in human beings. It is extremely important in our social life, and its disorders may be accompanied with some lack of pleasure and even with some dangers (1, 2). Several quality of life studies have demonstrated decrease in life satisfaction among patients with decrease or lack of olfaction (i.e. hyposmia and anosmia, respectively) (2, 3). Also studies on adults with major or minor head traumas have shown 5-10% incidence of anosmia in this population (less common in children) (2, 4, 5). Generally, the degree of olfactory sensation loss is proportional to trauma severity; although sometimes even minor head traumas may cause complete anosmia. In addition, the location of trauma onto the skull is somehow important; for example trauma to the frontal region often leads to anosmia less commonly compared

with blows to the occipital or parietal regions (1, 5-8). Finally, the olfactory disorders subsequent to head trauma may raise medicolegal problems, especially after work accidents or traffic accidents (2, 6).

The main difficulty of current olfactory tests is their subjectivity, and these tests are not able to distinguish functional disorders from nonfunctional ones accurately (9, 10).

Few articles on neuroimaging techniques of central and peripheral olfactory pathways are presented in the literature (11, 12). Among several types of radiologic techniques which are currently in use, functional magnetic resonance imaging (fMRI) and positron emission tomography (PET) have been more promising in evaluating activated regions of the brain in response to olfactory stimulation. However, these modalities have their own caveats and drawbacks, like special artifacts, high costs, low availability and so on (10, 12, 13).

**Corresponding Author:** Hooshang Gerami

ENT-HNS Department and Research Center, Amiralmomenin Hospital, 17 Shahrivar Ave. Rasht, Guilan, Iran, Postal code: 41396-37459  
Tel: +98 911 1315787, Fax: +98 131 2227409, E-mail: hg\_gerami@yahoo.com

Recently some other modalities in nuclear medicine, such as Single Photon Emission Computed Tomography (SPECT) are assumed as imaging modalities with which olfactory disorders may be evaluated objectively and quantitatively (10, 11, 14, 15). Due to the fact that the PET machine and its radio isotopes are expensive, we proposed that the SPECT might be a reasonable alternative for it in anosmic cases evaluation. Also, SPECT may be better than fMRI in some parts of the brain such as orbitofrontal cortex that is near the skull base and may be harder to be seen by fMRI due to signal distortions (10). The aim of this study was to find results of brain SPECT in anosmic subjects after closed head trauma for responding an old question: how can we confirm claim of our clients who complain of anosmia after a closed head trauma?

### Materials and Methods

A cross-sectional controlled study on 20 cases with olfactory dysfunction after closed head trauma and 15 normal age and sex matched volunteers was performed from Nov.2007 to July 2008 in Amiralmomenin referral Hospital-Otolaryngology, Head and Neck Surgery Department and Research Center- Rasht, Guilan Province, Iran. The proposal of the research was approved by research office and ethics committee of Guilan University of Medical Sciences. All of the cases were referred from Forensic Medicine Institute of Guilan at least one year after head trauma. All of the cases and control subjects underwent thorough ENT and neurological examination, and subjective evaluation of olfactory sensation status was performed by use of standard current tests (i.e. Pennsylvania test with 40 odorants).

Those subjects with specific neurologic and systematic diseases, with previous rhinologic or skull base surgeries, with severe septal deviation and nasal masses and those who consumed vasoactive drugs or alcohol or cigarettes were excluded from study (one from cases and 2 from controls). All the cases had brain computed tomography (CT) scans that did not reveal any gross abnormality in olfactory tract and anterior cranial fossa.

After confirmation of olfactory disorder in the cases and normality of the sensation in controls, all of the subjects were referred for performing brain SPECT (to Morvarid Gamma Scan Center). The imaging was performed after fulfilling informed consent sheaths by the subjects, and then, the SPECT were performed in two sessions: the first session without olfactory stimulation and the second session (48 hours after the

first one) after olfactory stimulation with vanilla powder (while patients' eyes were closed). Brain perfusion SPECT was performed after injection of 30 mci (1110MBQ)  $^{99m}\text{Tc}$ -ECD (Ethylcysteinate Dimer, IOEA) in supine position via butterfly catheter followed by normal saline flush. The time between olfactory stimulation and radiotracer infusion was as low as 4 minutes, and images (before and after olfactory stimulation) were obtained one hour after each injection by dual head SPECT gamma camera (ADAC-Philips, Vertex plus, MCD-AC, Milpitas, CA) and acquisitions were performed in 360 degrees started in anterior view. The subjects were instructed to remain absolutely quiet during acquisition of images in the silent low-lighted room.

The nuclear medicine specialist was not aware of situation of olfactory sensation of the subjects while performing the procedure and analyzing the images. According to previous studies, the orbitofrontal region of brain was assumed as the region of interest, and its perfusion was compared with that of the whole brain (11, 14).

The results of pre- and post stimulation perfusion in two groups were analyzed by use of SPSS-17 software and statistical methods like paired t test.

### Dosimetry

The critical organ for  $^{99m}\text{Tc}$ -ECD is bladder wall and effective dose is 0.041 rem. or 0.011 mSv.

### Results

Between 19 patients (10 male and 9 female, mean age:  $37.5 \pm 8$  years old) and 13 normal subjects (7 male and 6 female, mean age:  $34.46 \pm 7.12$  years), there was no statistically significant difference in sex and age.

Mean score in University of Pennsylvania Smell Identification Test (UPSIT) among the cases was  $11.2 \pm 2.7$  and among the controls was  $36.7 \pm 3.2$  ( $P < 0.001$ ). Kolmogorov-Smirnov statistical test showed that data obtained from brain perfusion before and after olfactory stimulation had normal distribution; therefore we were able to use parametric tests for analysis.

The mean of brain perfusion before stimulation in case group was  $7.97 \pm 1.05\%$  and in control subjects was  $8.26 \pm 0.19\%$  ( $P > 0.05$ ). After olfactory stimulation, the mean of brain perfusion in case and control group was  $8.49 \pm 1.5\%$  and  $9.89 \pm 0.54\%$ , respectively ( $P < 0.001$ ).

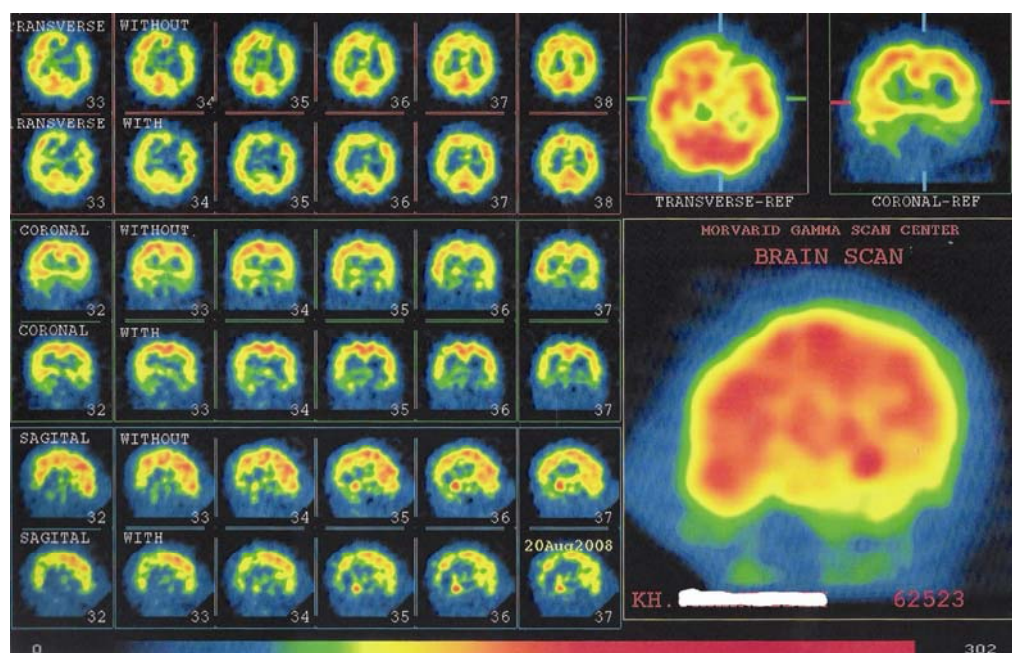
In each groups the difference between brain perfusion before and after stimulation was statistically significant (Table 1 and Figure 1).

**Table 1.** comparison between mean brain perfusion before and after olfactory stimulation in anosmic patients and normal controls.

Group	Mean score in UPSIT*	M. perfusion before stimuli (Mean $\pm$ SD)	M. perfusion after stimuli (Mean $\pm$ SD)	$\Delta$ Means (Mean $\pm$ SD)	Confidence interval 95%	P Value
Cases	11.2 $\pm$ 2.7	7.97 $\pm$ 1.05	8.49 $\pm$ 1.5	0.52 $\pm$ 0.69	0.19-0.86	P<0.004
Control	36.7 $\pm$ 3.2	8.26 $\pm$ 0.19	9.89 $\pm$ 0.54	1.62 $\pm$ 0.36	1.4-1.85	P<0.0001
P value	P<0.001	P>0.05	P<0.001	-	-	-

M=Mean SD=Standard Deviation  $\Delta$ : difference of

\*University of Pennsylvania Smell Identification Test (UPSIT)

**Figure 1.** SPECT images of one of the cases before (upper rows) and after (lower rows) olfactory stimulation. The brain perfusion images shows decreased tracer uptake in parasagittal area of the left lobe which shows no increased tracer accumulation after olfactory tract stimulation. These findings may represent olfactory tract impairment.

## Discussion

Olfactory sensation is an unknown sense in human being. In addition it is extremely important in our social life (2), and particularly in some societies and religions, for example in islamic countries, the importance of olfaction is very high, so the mulct of anosmia is equal to blood-money of a whole person; and this rule frequently leads to numerous medicolegal claims from persons who were involved in traffic or work accidents in these societies.

Obviously, this is not the only reason for having an objective test for detecting and documenting olfactory impairments. As we know, the main obstacle of current olfactory tests is their subjectivity. These tests are prone to false positive results and are not able to distinguish functional from nonfunctional smell disorders accurately (10).

Few articles on neuroimaging techniques in the study of central and peripheral olfactory pathways are present in the literature. Most of these researches are performed by PET and fMRI (10-13). Varney and colleagues showed that post traumatic impaired olfaction was closely associated with cerebral perfusion abnormalities (especially the orbitofrontal and medial prefrontal cortex) which was evident in cerebral positron emission tomography (PET) images (13).

SPECT is an imaging technique by which cortical perfusion increment after sensorial stimulation can be evaluated objectively and noninvasively (11, 15-17). In 1995 Furtak and colleagues in a preliminary report, presented 3 cases of mild head trauma diagnosed by CT, electroencephalogram and SPECT. They concluded that SPECT was more sensitive than CT and could detect brain perfusion abnormalities in agree with EEG (18).

In another study in 1995, Masdeu and colleagues reported that perfusion imaging with SPECT was more sensitive than CT or MRI in detecting brain abnormalities in patient with head trauma, and this was proved in other controlled studies (19, 20).

In an article in 1998, Lyczak and colleagues addressed brain perfusion SPECT scan that may be useful for medicolegal purposes after head trauma (21). Varney and Bushnell in a study for investigation quantitative neuro-SPECT findings in posttraumatic anosmia, selected 18 patients and 5 normal controls and showed 67 percent of anosmic patients had orbital frontal hypo perfusion significantly relative to the control subjects and relative to the other brain regions (such as inferior frontal pole, parasagittal region, etc) (1).

In the study of Di Nardo and colleagues on 5 posttraumatic anosmic patients and 10 healthy adults, brain SPECT by <sup>99m</sup>Tc-HMPAO was performed before and after olfactory stimulation and variable degrees of cortical activation were detected. Orbital frontal cortex (right: +26.6%, left: +25.6%), gyrus rectus (+24.5%) and superior temporal (right: +9.9%, left: +5.5%) areas were always activated, while only a slight increased perfusion was present in middle temporal (right: +3.2%, left: +2.1%) and parieto-occipital (right: +0.4%, left: +2%) regions. Post traumatic anosmic patients showed markedly less perfusion increments as low as 0.5% in every olfactory area. This study showed that SPECT could yield objective semi-quantitative information on brain perfusion and could be regarded as a promising contribution in the fields of olfaction neurophysiology and medicolegal queries (11).

In another study by a larger series of patients, Eftekhari and colleagues showed similar results (10). In this study 14 patients with post-traumatic impaired smell and 10 healthy controls underwent brain SPECT before and after olfactory stimulus. In most of seven regions of interest the post-stimulation quantitative values showed increased cortical perfusion, more pronounced in normal subject compared with the anosmic patients (except cerebellar areas and right occipital pole). Maximal activation was in orbito frontal regions (right: +25.45% and left: +25.47%). The main caveat of this study was inadequacy of measures in determining degree and type of smell loss in the cases. Also, the patients could see the vanilla powder at the examination, unlike our study in which the patients were examined by closed eyes and this may decrease interaction of visual or memory activities with brain perfusion.

Our study is in agreed with that of Dinardo and Eftekhari, but there are some differences between this and two above mention studies. For example Dinardo and colleagues used <sup>99m</sup>Tc-HMPAO radiotracer, while we used <sup>99m</sup>Tc-ECD that its uptake is significantly more linear with regard to cerebral blood flow. Thus, it has less back diffusion and better correlation with blood flow.

Also, in the Eftekhari's study, the degree and type of smell disorder were not accurately defined, the olfactory stimulation was performed by use of special pumps and in a complex-artificial manner, and the lag time between olfactory stimulation and IV injection of radiotracer was 7 minutes. Also they used mean activity in each region of interest in either hemisphere; but in our research, we tried to shorten the time between olfactory stimulation and radiotracer infusion as low as 4 minutes. Also we calculated the ratio of activity of each region of interest to activity of the whole brain because of attenuating baseline activity of the brain and its affects from olfactory memory, excitatory centers in limbic system and other regions of the brain that are excited during the examination.

We think this is the major advantage of our study comparing to the two above mentioned studies. Also our patients had brain CT scan and no one had encephalomalacy or brain atrophy. Finally, we calculated pre-and post-stimulation brain activity difference in normal subject as high as 1.4% and considered the difference lower than 1% abnormal and as an index for smell disorder.

In conclusion, brain SPECT is a valuable objective technique in evaluation of anosmic patients after head traumas and it may be used with other diagnostic modalities. It is better to perform brain SPECT in anosmic versus hyposmic patients, and also to compare PET or fMRI results with SPECT in future trials.

## Acknowledgements

Our special thanks to Dr. Hamidreza Bagheri, resident of otolaryngology who contributed in examination of the cases, and Dr. Kambiz Forghanparast who analyzed the data.

## References

1. Varney NR, Bushnell D. NeuroSPECT findings in patients with posttraumatic impaired smell: a quantitative analysis. *Head Trauma Rehabil* 1998;13(3):63-72.

2. Miani C, Bracale AM, Moreschi C, Codarini M, Ortolani F. Post-traumatic anosmia: description of a clinical case, proposal of a standardized protocol and medico-legal comments. *Acta Otorhinolaryngol Ital* 2002;22(3):142-9.
3. Miwa T, Furukawa M, Tsukatani T, Costanzo RM, DiNardo LJ, Reiter ER. Impact of olfactory impairment on quality of life and disability. *Arch Otolaryngol Head Neck Surg* 2001;127(5):497-503.
4. Jacobi G, Ritz A, Emrich R. Cranial nerve damage after paediatric head trauma: a long-term follow-up study of 741 cases. *Acta Paediatr Hung* 1986;27(3):173-87.
5. Zusho H. Posttraumatic anosmia. *Arch Otolaryngol* 1982;108(2):90-2.
6. Biacabe B, Norès JM, Bonfils P. Description and analysis of olfactory disorders after head trauma. Review of the literature. *Rev Neurol (Paris)* 2000;156(5):451-7.
7. Hendriks AP. Olfactory dysfunction. *Rhinology* 1988;26(4):229-51.
8. Doty RL, Yousem DM, Pham LT, Kreshak AA, Geckle R, Lee WW. Olfactory dysfunction in patients with head trauma. *Arch Neurol* 1997;54(9):1131-40.
9. Cain WS, Gent J, Catalanotto FA, Goodspeed RB. Clinical evaluation of olfaction. *Am J Otolaryngol* 1983;4(4):252-6.
10. Eftekhari M, Assadi M, Kazemi M, Saghari M, Fard Esfahani A, Fallahi Sichani B, et al. A preliminary study of neuroSPECT evaluation of patients with post-traumatic smell impairment. *BMC Nucl Med* 2005;5:6.
11. Di Nardo W, Di Girolamo S, Galli A, Meduri G, Paludetti G, De Rossi G. Olfactory function evaluated by SPECT. *Am J Rhinol* 2000;14(1):57-61.
12. Savic I. Imaging of brain activation by odorants in humans. *Curr Opin Neurobiol* 2002;12(4):455-61.
13. Varney NR, Pinkston JB, Wu JC. Quantitative PET findings in patients with posttraumatic anosmia. *J Head Trauma Rehabil* 2001;16(3):253-9.
14. Eftekhari M, Assadi M, Kazemi M, Saghari M, Mojtahedi A, Fard-Esfahani A, et al. Brain perfusion single photon emission computed tomography findings in patients with posttraumatic anosmia and comparison with radiological imaging. *Am J Rhinol* 2006;20(6):577-81.
15. Mann NM, Vento JA. A study comparing SPECT and MRI in patients with anosmia after traumatic brain injury. *Clin Nucl Med* 2006;31(8):458-62.
16. Warwick JM. Imaging of brain function using SPECT. *Metab Brain Dis* 2004;19(1-2):113-23.
17. Catafau AM. Brain SPECT in clinical practice. Part I: perfusion. *J Nucl Med* 2001;42(2):259-71.
18. Furtak J, Chmielowski K, Podgórski JK, Skrzyński S, Kadłubowski A, Małowidzka-Serwińska M. Cerebral blood flow changes after mild head trauma imaging with SPECT HMPAO. Preliminary report. *Neurol Neurochir Pol* 1995;29(3):401-7.
19. Masdeu JC, Abdel-Dayem H, Van Heertum RL. Head trauma: use of SPECT. *J Neuroimaging* 1995;5 Suppl 1:S53-7.
20. Abdel-Dayem HM, Abu-Judeh H, Kumar M, Atay S, Naddaf S, El-Zeftawy H, et al. SPECT brain perfusion abnormalities in mild or moderate traumatic brain injury. *Clin Nucl Med* 1998;23(5):309-17.
21. Lyczak P, Lass P, Sygitowicz M, Stepień-Koćmiel E, Mierzejewska E, Bandurski T, et al. Brain perfusion changes after head trauma assessed by cerebral SPECT with aminophylline test. *Neurol Neurochir Pol* 1998;32(5):1091-8.