

Tuberculosis of the Breast: A Case Report

Zohreh Azarkar¹, Mahmood Zardast², and Nahid Ghanbarzadeh³

¹ Department of Infectious Disease, School of Medicine, Birjand University of Medical Sciences, Birjand, Iran

² Department of Pathology, School of Medicine, Birjand University of Medical Sciences, Birjand, Iran

³ Department of Gynecology, School of Medicine, Birjand University of Medical Sciences, Birjand, Iran

Received: 30 Oct. 2008; Received in revised form: 30 Aug. 2009; Accepted: 8 Nov. 2009

Abstract- Primary tuberculosis of the breast is a rare disease. It usually occurs in female of reproductive age. Any form of tuberculosis mastitis may present with feature of malignancy. Diagnosis is mainly based on identification of tubercle bacilli. We report a 42-year-old woman with primary tuberculosis abscess of the breast, who underwent surgical resection. Fine needle biopsy failed to achieve specific diagnosis before surgical operation. She responded to anti-TB therapy postoperatively. In endemic area, tuberculosis should be considered in the differential diagnosis of breast tumors.

© 2011 Tehran University of Medical Sciences. All rights reserved.

Acta Medica Iranica 2011, 49(2): 124-126.

Keywords: Breast; Tuberculosis; Abscess; Mastitis

Introduction

Breast tuberculosis is a rare form of tuberculosis. It is mainly classified as primary and secondary form. Primary form is rare (1). In developing countries, where tuberculosis is endemic, the incidence is 0.25-4.5%. The diagnosis is difficult because of nonspecific clinical and radiological findings (2).

This paper reports a rare case of primary tuberculosis of the breast mimicking abscesses that was confirmed by microbiological and histological examination

Case Report

A 42 years old married women presented to surgery department with history of lump and erythem of skin in the breast for two months. She had no family history of breast carcinoma. The woman was febrile and there was no prominent history of fever or respiratory symptom .In physical examination she had a painful mass, 6 to 7cm diameter in the upper outer quadrant of right breast. There was no nipple discharge or skin retraction. There was no axillary or cervical lymphadenopathy. The examination was normal. Examination of abdomen revealed no evidence of any intra abdominal lump or ascites. Mantoux test was negative. She had not history of BCG vaccination.

WBC count was 7800 with polymorphs 54%, lymphocytes 42%, erythrocyte sedimentation rate (ESR)

was 70mm/hr, and hemoglobin was 7.6g/dl, Liver function tests were normal. Sputum was negative for mycobacterium tuberculosis. Chest X Ray was normal. Breast sonography showed a thick-walled cystic mass with heterogenous and asymmetric density. Ultrasound-guided aspiration revealed pus. Fine needle aspiration was done but revealed no evidence of malignancy. She underwent empiric antibiotic therapy after breast aspiration but these symptoms and sign did not improve.

Histology of the breast tissue showed necrosis, epitheloid cell, granulomas and langhan's giant cell (Figure 1).

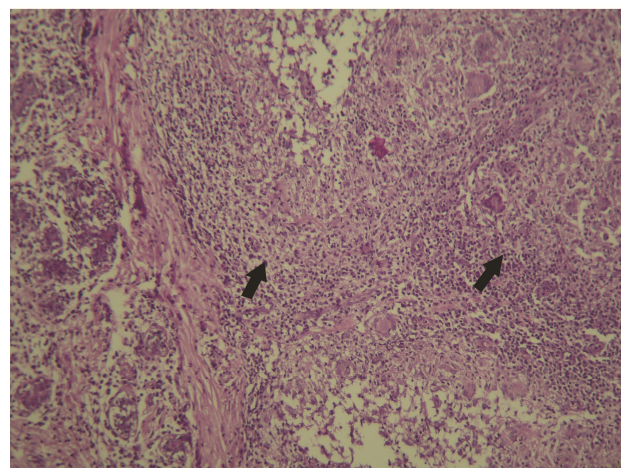


Figure 1. Breast tissue with granuloma of tuberculosis (×250, H.E staining)

*Corresponding Author: Zohreh Azarkar

Department of Infectious Disease, School of Medicine, Birjand University of Medical Sciences, Birjand, Iran
Tel: +98 915 1613920, Fax: +98 561 4445402, E-mail: drz.azarkar@yahoo.com

The result of pus culture was positive for acid fast bacilli. After confirmation of diagnosis, the patient received anti tuberculosis therapy. The six month treatment regimen comprise two months of intensive phase with four drugs (Rifampin, Isoniazid, Pyrazinamid and Etambutol), followed by four months of continuation phase with two drugs (Rifampin and Isoniazid). There has been no recurrence after 18 months follow up.

Discussion

Tuberculosis of the breast is an extremely rare form of extrapulmonary TB, which principally seen in women in reproductive age groups, especially affecting lactating females (3, 4).

Tuberculosis constitutes approximately 0.25-0.1% of all surgically treated breast disease and 0.1-0.5% of all tuberculosis cases (5, 6).

It is uncommon in western countries; but has higher incidence in developing countries (7).

Breast tissue is remarkably resistant to tuberculosis. This is due to the fact that like skeletal muscles and spleen it provides infertile environment for survival and multiplication of tubercle bacilli (8).

Breast involvement can be either primary without any extra-mammary focus, or secondary to pulmonary tuberculosis. The primary form of the disease is rare and probably occurs via infection through skin abrasions or through openings of the lacrimal ducts at the nipple. The secondary variety is more common and develops by either direct extension, retrograde lymphatic dissemination from the affected axillary, cervical lymph nodes or rarely from pulmonary disease (7).

Primary manifestation of TB is mostly seen in premenopausal age; however it's possible in young women between 20 and 40 (9).

Our patient did not have any focus of tuberculosis outside the breast, both on physical and radiological examination, and it may be considered to be primary form. The breast lesion can be classified into nodular, disseminated or sclerosing pattern. The principal clinical manifestation is the nodular form, which predominant in elderly patients and both clinically and radiological mimics carcinoma. In younger patients, the disease usually present as a pyogenic breast abscess (6, 10).

It is needed to exclude carcinoma or infections of other microorganisms, such as actinomycosis or fungus (11).

Mammography and ultrasonography are unreliable in differentiating mammary tuberculosis from carcinoma

(3, 12). Fine-needle aspiration cytology can be diagnostic in about three-fourth of patients with appearance of epithelioid granulomas or Langhans' giant cells. Other type of biopsy such as core needle or surgical biopsy can get higher accuracy in diagnosis (8).

Bacteriologic and histochemical studies of the sample may confirm the definitive diagnosis by identifying the presence of the bacillus, although culture and acid-fast staining are negative in most cases (1, 6).

Our patient had ultra sonography features of abscess; US-guided aspiration was done. In our reported case surgical resection was indicated because of indeterminate diagnosis after pre-operative diagnostic procedure or refractory or expected to be not amenable to medical control.

Histological and microbiological examination confirmed the diagnosis of tuberculosis of breast. As the patients did not have any other focus, the diagnosis was primary tuberculosis mastitis. She responded well to anti-TB therapy.

In conclusion, primary breast tuberculosis is a very rare disease, even in endemic countries.

The diagnosis must be considered in young patients presenting with a palpable lump, especially if they are lactating. Histological examination is required for confirmation. Treatment with anti-TB drugs is effective.

References

1. Da Silva BB, Dos Santos LG, Costa PV, Pires CG, Borges AS. Primary tuberculosis of the breast mimicking carcinoma. *Am J Trop Med Hyg* 2005;73(5):975-6.
2. Kaneria MV, Sharbidre P, Burkule D, Shukla A, Somani A, Nabar S. Bilateral breast tuberculosis: a rare entity. *J Indian Acad Clin Med* 2006; 7(1):61-3.
3. Tewari M, Shukla HS. Breast tuberculosis: diagnosis, clinical features and management. *Indian J Med Res* 2005;122(2):103-10.
4. Kakkar S, Kapila K, Singh MK, Verma K. Tuberculosis of the breast. A cytomorphologic study. *Acta Cytol* 2000;44(3):292-6.
5. Kalarç N, Ozkan B, Bayiz H, Dursun AB, Demirağ F. Breast tuberculosis. *Breast* 2002;11(4):346-9.
6. Rosen P. *Rosen's Breast Pathology*. 2nd ed. Philadelphia: Lippincot Williams and Wilkins; 2001: 70-9.
7. Madhusudhan KS, Gamanagatti S. Primary breast tuberculosis masquerading as carcinoma. *Singapore Med J* 2008;49(1):e3-5.
8. Luh SP, Hsu JD, Lai YS, Chen SW. Primary tuberculous infection of breast: experiences of surgical resection for aged patients and review of literature. *J Zhejiang Univ Sci B* 2007; 8(8):580-3.

Tuberculosis of the breast

9. Hughes LE, Mansel RE, Webster DYT, editors. *Benign Disorders and Diseases of the Breast: Concepts and Clinical Management*. London: WB Saunders; 2000. 90-2.
10. O'Reilly M, Patel RR, Cummins R. Tuberculosis of the breast presenting as carcinoma. *Mil Med* 2000;165(10):800-2.
11. Khanna R, Prasanna GV, Gupta P, Kumar M, Khanna S, Khanna AK. Mammary tuberculosis: report on 52 cases. *Postgrad Med J* 2002;78(921):422-4.
12. Zandrino F, Monetti F, Gandolfo N. Primary tuberculosis of the breast. A case report. *Acta Radiol* 2000;41(1):61-3.