

Metopism: As an Indicator of Cranial Pathology; A Good Example from Iranian Plateau

Mohammad Mehdi Tavassoli

Department of Archaeology, Sistan and Bluchestan University of Medical Sciences, Zahedan, Iran

Received: 7 Apr. 2009; Received in revised form: 23 Jan. 2010; Accepted: 12 Mar. 2010

Abstract- Metopism had been observed as a genetic trait. Recent studies have brought to light that it can get as an indicator of cranial pathology. An example of this pathology has been studied by this author on an Iranian skeletal sample. The purpose of this paper is to provide basic information on the subject and thereby to create awareness among Iranian anthropologists and archaeologists of this new line of evidence as well as to pathologists.

© 2011 Tehran University of Medical Sciences. All rights reserved.

Acta Medica Iranica 2011; 49(6): 331-335.

Keywords: Metopism; Iranian skeletal sample; Iranian anthropologists; Cranial Pathology

Introduction

The frontal bone at birth is divided bilaterally by a metopic suture. The metopic suture in fancy extends from the nasofrontal suture superiorly along the midline to bregma. This suture usually closes between the first and second year considered to be anomalous (1). While a metopic suture may rarely persist throughout life as a discrete suture separating the frontal bone, it more commonly manifests suture (2). The remnant suture seldom penetrates deeper than the outer table of the frontal bone, or it may not penetrate the outer table at all. Often it is so indistinct as to be very difficult to detect. This remnant, as with the inferior portion of a complete metopic suture, is very tortured in its path. Only this torturous portion tends to persist as a remnant supranasal suture, the more nearly straight part being the portion which is obliterated in almost all skulls.

The purpose of this paper is to provide basic information on the subject and thereby to create awareness among Iranian anthropologists and archaeologists of this new line of evidence as well as to pathologists. As attempt is made to describe the etiology of cranial pathologies seldom seen on archaeological specimens (throughout the world) and to illustrate the potentials of such evidence in understanding the health status of extinct populations in the area. Literature of metopic suture is abundant (LeDouble 1903, Bryce and Young 1916, Bolk 1917, Sullivan 1922, Malovskie 1927, Augier 1928, Schultz 1929, Akabori 1934,

Montagu 1937, Comas 1942, Hess 1946, Woo 1949, Urison 1959, Ossenser 1969, El-Najjar and McWilliams 1978, and Zivanovic 1982) (4,5). Limson (2) reported a higher male incidence. Hess (9) defined a "metopica syndrome" of correlated cranial and finger anomalies, probably genetically determined. Montagu (2) based on a survey of the literature concerning metopism in man and other primates, came to the same conclusion. Torgersen (2) studied the trait radiographically in the living and concluded that the presence of the suture is due to a dominant gene with varying penetrance. Ossenberg (9) concluded that the trait is presence slightly more often in females than in males, a condition also found by Akabori (9).

A comprehensive and well illustrated account of the metopic suture observed of the frontal bone, and as a trace of disease is given by Zivanovic (11). He stated that the metopic suture, in certain circumstances, does not ossify in the second half of the first year of life but remains a suture throughout life. This believed as asserts in scientific literature, that the existence of this suture in the adults skulls is due to genetic influences and not a question of any abnormality, but the consequence of the process of brachycephalization, in other words, shortening of the skull. This process which began in Palaeolithic times has continued to the present day. The dolichocranial skull has slowly, in the course of centuries, become shorter and heads have become more and more rounded in shape, or brachycephalic (11). He also stated that some scholars have thought that

Corresponding Author: Mohammad Mehdi Tavassoli

Department of Archaeology, Sistan and Bluchestan University, Zahedan, Iran

Tel: +98 541 8052947, 912 3055173, Fax: +98 541 233100, E-mail: Tavassoli54@yahoo.com

Metopism: as an indicator of cranial pathology

metopism was due to increase in the volume of the frontal bones of the brain, or even the reduction of the pressure exercised by the muscles in the temporal region. Others have considered it as a matter of an endocrine disorder. But the fact is that metopism appears more frequently among women than men and was more prevalent in medieval times than is today. It also occurred more often in a population whose average life expectancy was low. Here it is undoubtedly a question of disorder in the ossification process due to the action of some biochemical factor, most probably a lack of calcium. The main manifestation suffering from malnutrition or amongst women who have become pregnant and have given birth immaturely. For this, it emerges that metopism is not merely an interesting morphological fact, or even a racial or genetic characteristic, but an indication of a definite pathological of the process of ossification and is a specific biochemical disorder, the consequence of malnutrition due to intrinsic or extrinsic factors. The fact that the metopic suture is frequently associated with supernumerary wormian bones supports this view-point (11).

Prevalence of metopism in Iran

A very good example of metopic suture from the Iranian skeletal population comes from Safavid monument called Carvansara Mohammadabad Kharreh (dated to 1500 A.D.), belonging to the Islamic period (Tavassoli 1999: 136). Mohammadabad is a road side village on Qazvin-Saveh road (Iranian Plateau) and is about 40 km away from Qazvin city, Iran. Carvansara Mohammadabad Kharreh (Carvansara: is a Persian word for a large house for travelers in Safavid period), adjacent to the village, is now an official centre for archaeological activities being carried out under the Department of Archaeology, Tehran University. The centre includes a small museum of Qazvin Plain findings such as pottery, stone tools and human skeletal remains. Material belonging to the Islamic period from Carvansara is also housed in this museum. The skeletal material which included seven skulls preserved in good condition were recovered from beneath the northern wall of the monument. This collection has been studied anthropologically and pathologically by the present author during August-September 1993, and restudied in July 2007.

Description of cranial bones of Carvansara sample: Important morphological observations are as follows:

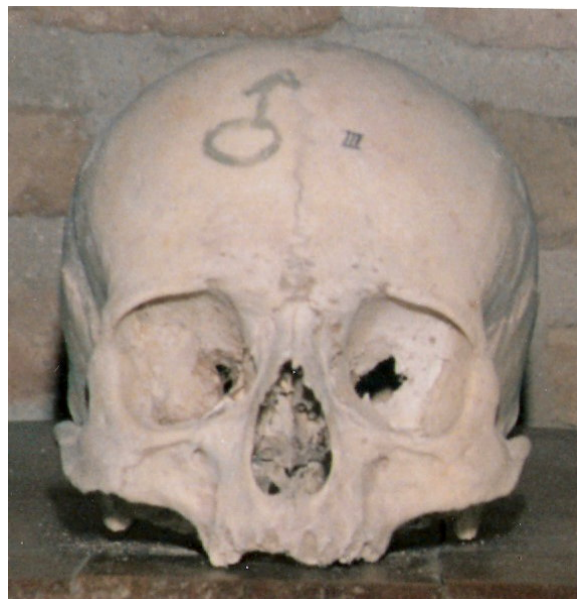

Figure 1. Norma frontalis (9)

Norma frontalis: The metopic suture (Figure 1) is still open. Because of adolescence of the individual, the skull looks squarish.

Norma lateralis: The forehead is almost straight. The temporal line is marked. The nasal spine is rather elevated. Prognathism and arcade rugose are not seen in this specimen. The mastoid processes are developed (Figure 2).

Norma verticalis: The skull is oval shaped and the parietal bones are fairly prominent.

Norma occipitalis: The nuchal lines are moderate.

Norma basalaris: The foramen magnum is moderate and the occipital condyles are prominent. The styloid process is well developed. The glenoid fossae are deep (Figure 3).

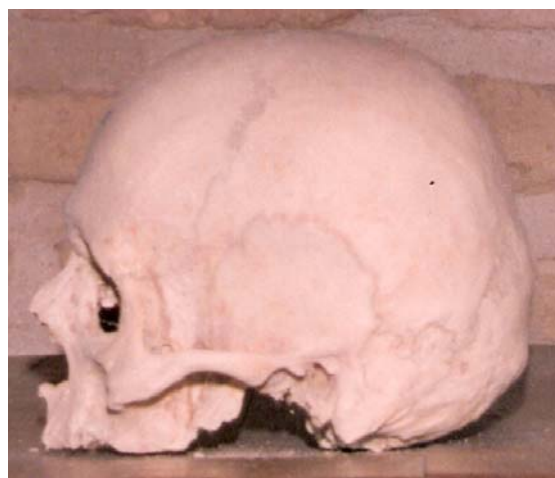

Figure 2. Norma lateralis (9)

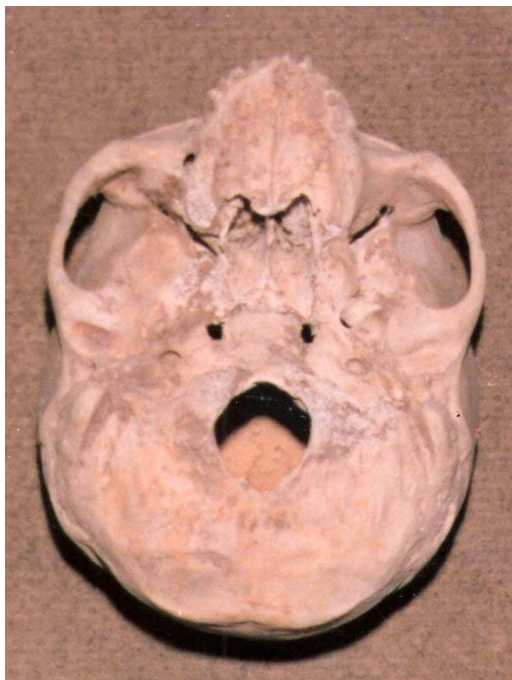

Figure 3. Norma basalaris (9)

No evidence of metopism has been reported so far, from Iranian Plateau or Zagros mountain ranges. None of Tepe Hissar skeletal series (dated 4000 B.C. to 2000 B.C.), studied for pathologies by Krogman (7), nor Sialk skeletal materials (6000 B.C. to 4000 B.C.), studied by Vallois (1938), nor even Shahr-e Sokhta skeletal population (2900 B.C. to 2000 B.C.), studied by Pardini and Sarvari-Negahban (8) have exhibited such evidences.

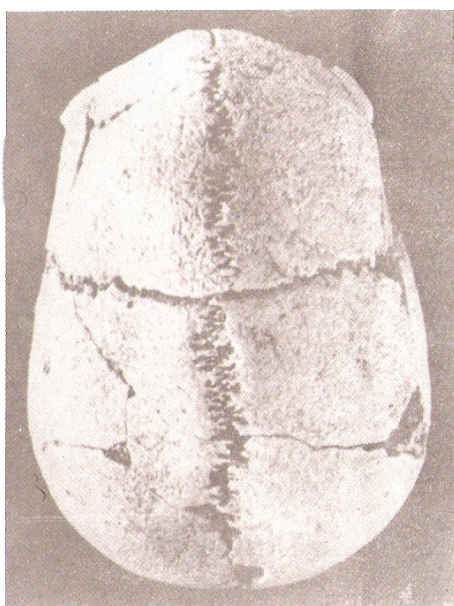


Figure 4. Mtopism (3)

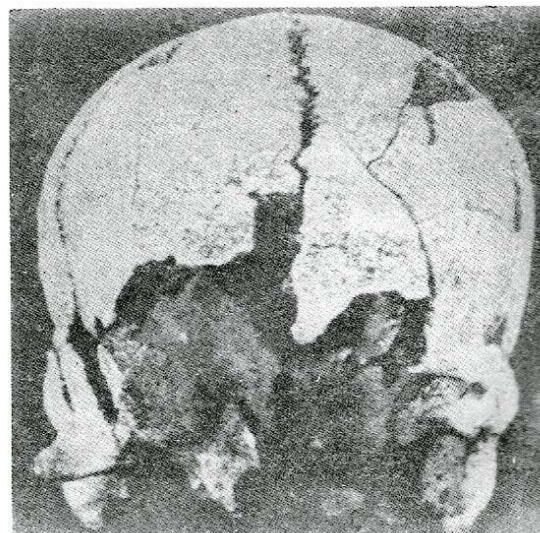


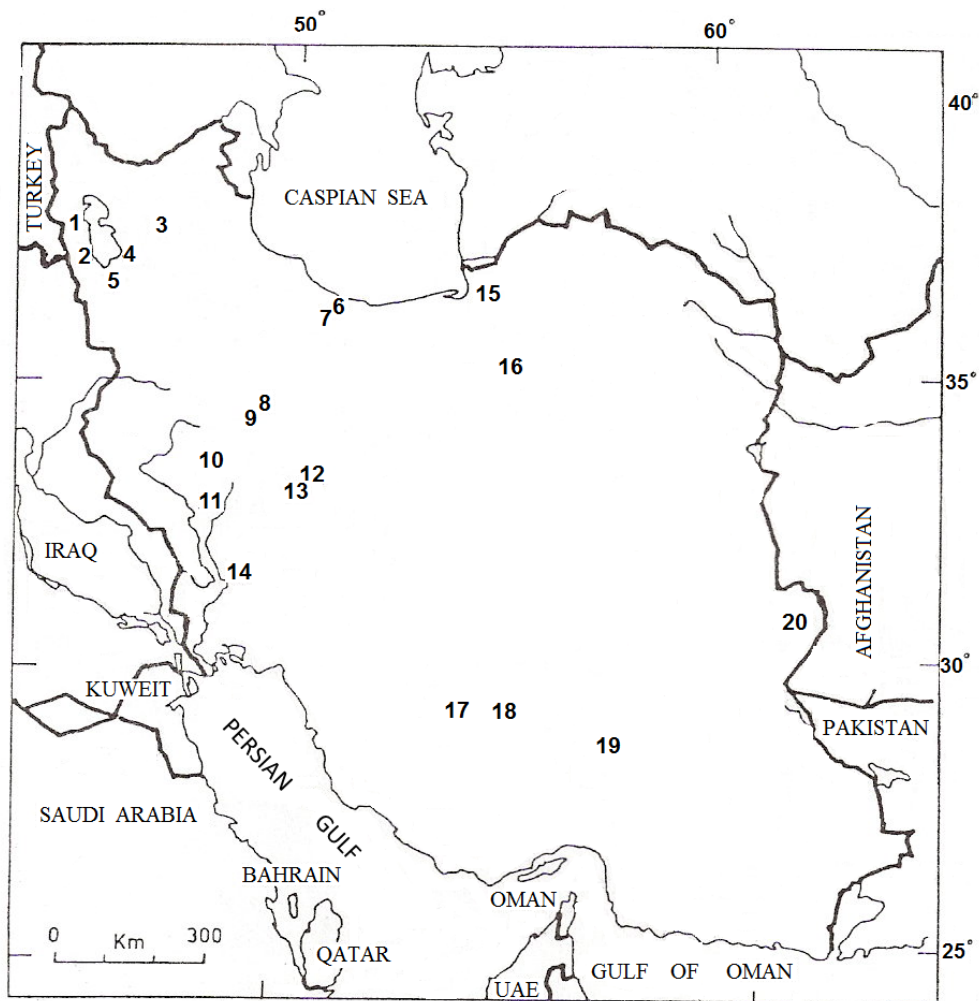
Figure 5. Mtopism (3)

While there exists scanty data available on metopic suture in the Iranian Plateau and Zagros mountain regions, it has been observed on a few individuals (5 in number) from Alborz mountain regions (3). Ikeda (3) reported that although there is no evidence of metopism during the Islamic period and the Parthian period, it was exhibited by one individual (Figure 4) from the Iron Age Dailaman skeletal series (dated 600 B.C. to 400 B.C.), and also exhibited by four specimens belonging to the Prehistoric Dailaman population.(Figure 5, 6) It is not out of place to mention that here the earlier sample (from Iron Age) was dolichocranic, with an average of between 26 to 29 years old. Three of the four later individuals were brachycranial and the other was dolichocranial with an average age of 30-32 years. Of these 5 individuals, two mentioned are females and the others are indeterminate. There was no hints to pathologies for these individuals by Ikeda.

Discussion

However, it is an accepted fact that on the basis of available data and published reports, and also scientific literature, the Carvansara sample is unique amongst the Iranian Plateau skeletal series. On the said, the sample appears probably a trace of disease and perhaps with a racial characteristic or genetic phenomenon, holding this point of view it is necessary for anthropomorphological restudy of Northern Iranian skeletal material and Iranian Plateau skeletal series.

Metopism: as an indicator of cranial pathology



- | | |
|------------------|--------------------|
| 1. Haftavan Tepe | 11. Babajan |
| 2. Geoy Tepe | 12. Nushi Jaan |
| 3. Dinkha Tepe | 13. Giyan |
| 4. Dalma Tepe | 14. Sargarab |
| 5. Hasanlu | 15. Shah Tepe |
| 6. Dailaman | 16. Hissar |
| 7. Marlik | 17. Tall-i Malyan |
| 8. Seh Gabi | 18. Tall-i Nokhodi |
| 9. Godin Tepe | 19. Tepe Yahya |
| 10. Siabid | 20. Shahr-e Sokhta |

Figure 6. (9)

References

| | |
|--|---|
| 1. Breathnach AS. Frazer's Anatomy of the Human Skeleton. 6 th ed. London: Churchill Livingstone; 1965. | Iran Archaeological Expedition Report 9, 1968", in (4)Anthropological Studies of West Asia, II (9). Tokyo, The University of Tokyo, The Institute for Oriental Culture; 1968. |
| 2. El-Najjar MY, McWilliams KR. Forensic Anthropology: The Structure, Morphology and Variation of Human Bone and Dentition. Springfield, IL: Charles C Thomas; 1978. | 4. Jarco S. (ed) Human Palaeopathology. New Haven: Yale University Press; 1966. |
| 3. Ikeda J, editor. Anthropological Studies of West Asia II. Human Remains from the Tombs in Dailamanistan. "Iraq- | 5. Kennedy ARK, Possehl GL. Studies in the archaeology and palaeoanthropology of South Asia. New Delhi: Oxford and IBH Publishing Co.;1984. |

6. Krogman WM. The skeletal and dental pathology of an early Iranian site. *Bull Hist Med* 1940;8(1):28-48.
7. Krogman WM. The people of early Iran and their ethnic affiliation. *Am J Physical Anthropology* 1940;26(1):269-308.
8. Pardini E, Sarvari-Negahban AA. Craniologia degli inumati di Shahr-e-Sokhta (Sistan, Iran). *Studio Preliminare, Archivio Per L'Antropologia e la Ethnologia, Firenze*, 1976;106:273-321.
9. Tavassoli MM. *Paleoanthropology of Iran*. Rawalpindi (Pakistan): ST Printers; 1999.
10. Vallois HV. 1938; *Les Ossements Humains de Sialk, Contribution a l'Etude de l'Historie Raciale de l'Iran Ancien*, in *Fouilles de Sialk Pres de Kashan 1933, 1934,1937* (R.Girshman Ed.), vol.II. pp.113-171. Paris, Geuthner; 1938.
11. Zivanovic S. *Ancient diseases: the elements of paleopathology*. New York: Pica Press; 1982.