

Diffuse Myelitis after Treatment of Cerebral Aspergillosis in an Immune Competent Patient

Reza Mollahoseini and Mahdi Nikoobakht

Department of Neurosurgery, Firoozgar Hospital, Tehran University of Medical Science, Tehran, Iran

Received: 31 Jan. 2010; Received in revised form: 2 Jul. 2010; Accepted: 18 Aug. 2010

Abstract- Presentation of an unusual case of cerebral aspergillosis in an immune competent patient who was treated successfully but symptoms and signs of a demyelinating process following initial recovery has been occurred. A 29-year-old male with focal seizure. Brain MRI revealed small multiple hemispheric and dural lesions. An open biopsy was conducted. Histological evaluation revealed hyphe-like structure in the necrotic area, within vessel walls, and lumina, suggestive aspergillus fumigatus . Furthermore, branched hyphae in potassium hydroxide 15% and colonies on Sabouraud dextrose agar were observed. Based on the above findings the patient underwent anti fungal therapy. The patient recovered and continued a normal life however a follow up MRI was performed after 3 months from recovery. No significant abnormality was observed from the MRI procedure. One month later the patient developed signs and symptoms of spinal cord involvement which seemed to be the result of myelitis. A brain MR showed no abnormalities .Therefore it seemed reasonable to administer corticosteroid as a treatment for suspected active demyelinating process. During the above treatment, signs and symptoms of myelopathy disappeared and a whole spine MRI showed remarkable improvement.

© 2011 Tehran University of Medical Sciences. All rights reserved.

Acta Medica Iranica 2011; 49(6): 402-406.

Keywords: *Aspergillus fumigatus*; Aspergillosis; Myelitis

Introduction

Aspergillus, an ubiquitous species of fungus, is normally pathogenic among patients with impaired immune defenses (1). Aspergillosis should be considered in cases manifesting with acute onset of focal neurologic deficits resulting from a suspected vascular or space-occupying lesions especially in immunocompromised hosts. Infection with *Aspergillus* is rare in immune competent patient (2). Post infectious myelitis is a demyelinating syndrome that often occurs in association with a systemic infection and classifies as a subtype of inflammatory demyelinating diseases of the central nervous system (3,4). The present study presents an unusual case of cerebral aspergillosis in an immune competent patient who was initially treated successfully but symptoms and signs of a major neurologic problem followed the initial recovery.

Demyelination can be regarded as either primary or secondary. The primary form may either destroys/damages myelin or myelin-forming cells; whereas axons are relatively normal, at least in the early

stages. Secondary demyelization, on the other hand, follows damage to neurons or axons, followed by breakdown of myelin. Many pathological processes such as infectious diseases, infarcts, hemorrhages, trauma and tumors result in breakdown of both primary and secondary demyelinating (10,11).

Case Report

In 2007, a 29-year-old male patient was admitted to the department of neurosurgery in a hospital in Tehran, Iran with a history of transient episodes of focal seizures since 2005. The type of seizure has been jerky-like movements in the right upper limb. A Magnetic Resonance Imaging (MRI) scan both with and without contrast was performed and results revealed small multiple hemispheric and dural lesions that enhanced heterogeneously with IV contrast and (Figure 1).

The patient underwent open biopsy and Histological evaluation revealed multiple areas of granuloma showing epithelioid cell granulomas with Langhans type giant cells and central necrosis.

Corresponding Author: Mahdi Nikoobakht

Department of Neurosurgery, Firoozgar Hospital, Tehran University of Medical Science, Tehran, Iran
Tel: +98 88051573, 912 2029419, Fax: +98 21 88942622, E-mail: mnikobakht@gmail.com

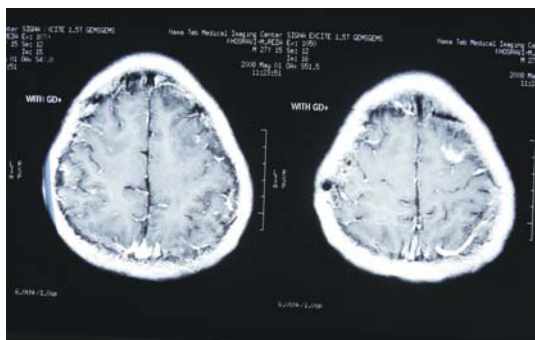


Figure 1. Multiple small hemispheric and dural lesions that enhanced heterogeneously with IV contrast

Moreover, the small vessel showed expansion and perivascular lymphoma cell infiltrations (Figure 2a). Periodic acid shiff (PAS) stain showed hyphe-like structure in the necrotic area, within vessel walls, and lumina. Furthermore, brancheal hyphae was observed in potassium hydrxide15%; and colonies on sabourud dextrose agar grew, indicating aspergillus fumigatus as shown in Figure 2b. The patient underwent an anti fungal therapy using amphotricin B and itraconazol in a standard dose and for a prescribed duration. The patient recovered gradually and a follow up MRI was conducted three months after the termination of anti fungal therapy. This test revealed no significant abnormality, neither an abnormal signal intensity in both hemispheres; a clear indication of the patient’s recovery (Figure 3).

The immunologic system was evaluated with the following tests: (i) CBC with differential smear, (ii) serum immunoglobulin levels (IgG, IgM ,IgA ,IgD ,IgE), (iii) quantification of blood mononuclear cell populations by immunofluorescence assays employing

monoclonal antibody markers, (iv) complement(CH50, C3, C4), and (v) HIV test. All results were normal.

Nine months after termination of treatment both upper and lower limbs became progressively weak and was unable to walk, along with sphincter problems including urinary and fecal incontinency. During a physical examination spastic quadriparesis and hyper-reflexia were present. The patient underwent Magnetic Resonance Imaging of both brain and pan spine. It showed ill defined iso to hyposignal T1W, hypersignal T2W cord substance lesions involving cervical, thorasic, lumbar segments and conus medullaris that enhanced partially with IV contrast (Figure 3).

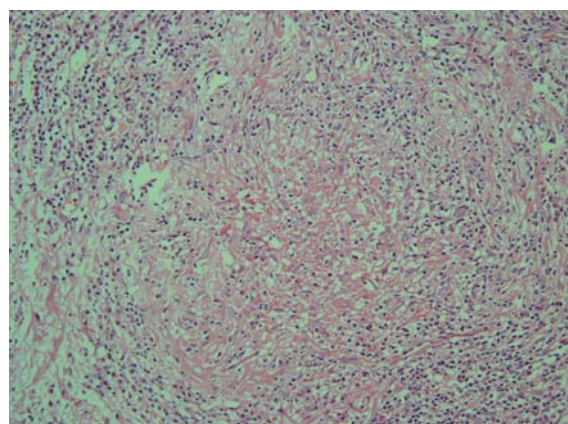


Figure 2a. Multiple areas of granuloma showing epithelioid cell granulomas with langhans type giant cells and central necrosis. Moreover the small vessel show expansion and perivascular lymphoma cell infiltrations

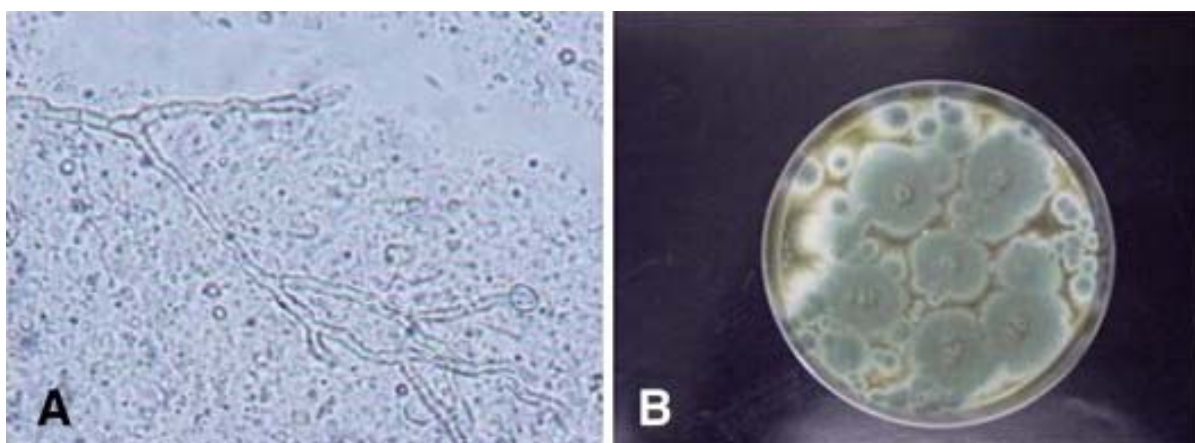


Figure 2b. A) brancheal hyphae in potassium hydroxide viewed *400. B) colonies en sabouroud dextrose agar

Diffuse myelitis after treatment of cerebral aspergillosis

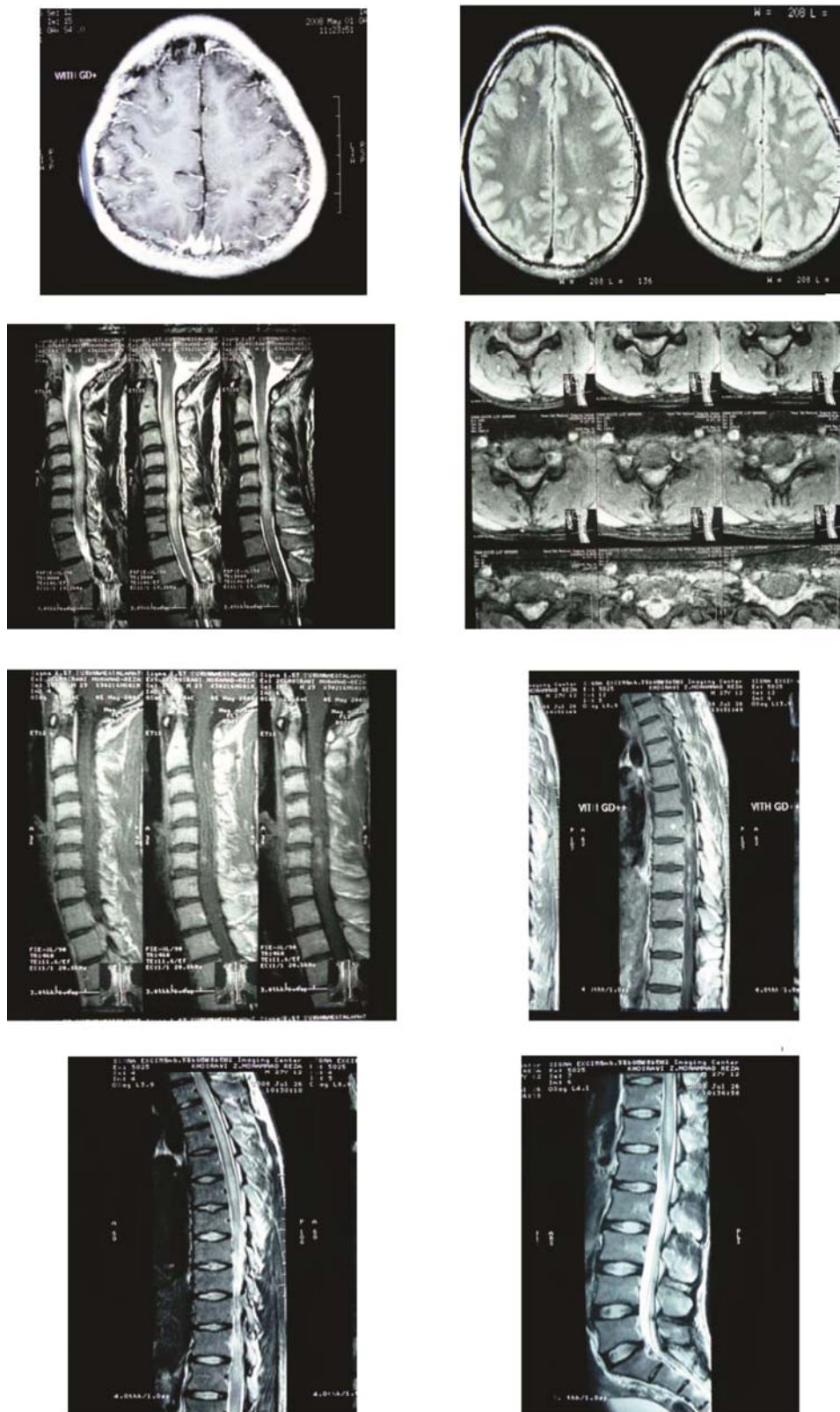


Figure 3. Magnetic resonance imaging of brain and pan spine that showed ill defined iso to hypo signal T1W, hypersignal T2W cord substance lesions involving cervical, thoracic, and lumbar segments and conus medullaris that enhanced partially with IV contrast, and normal brain MRI

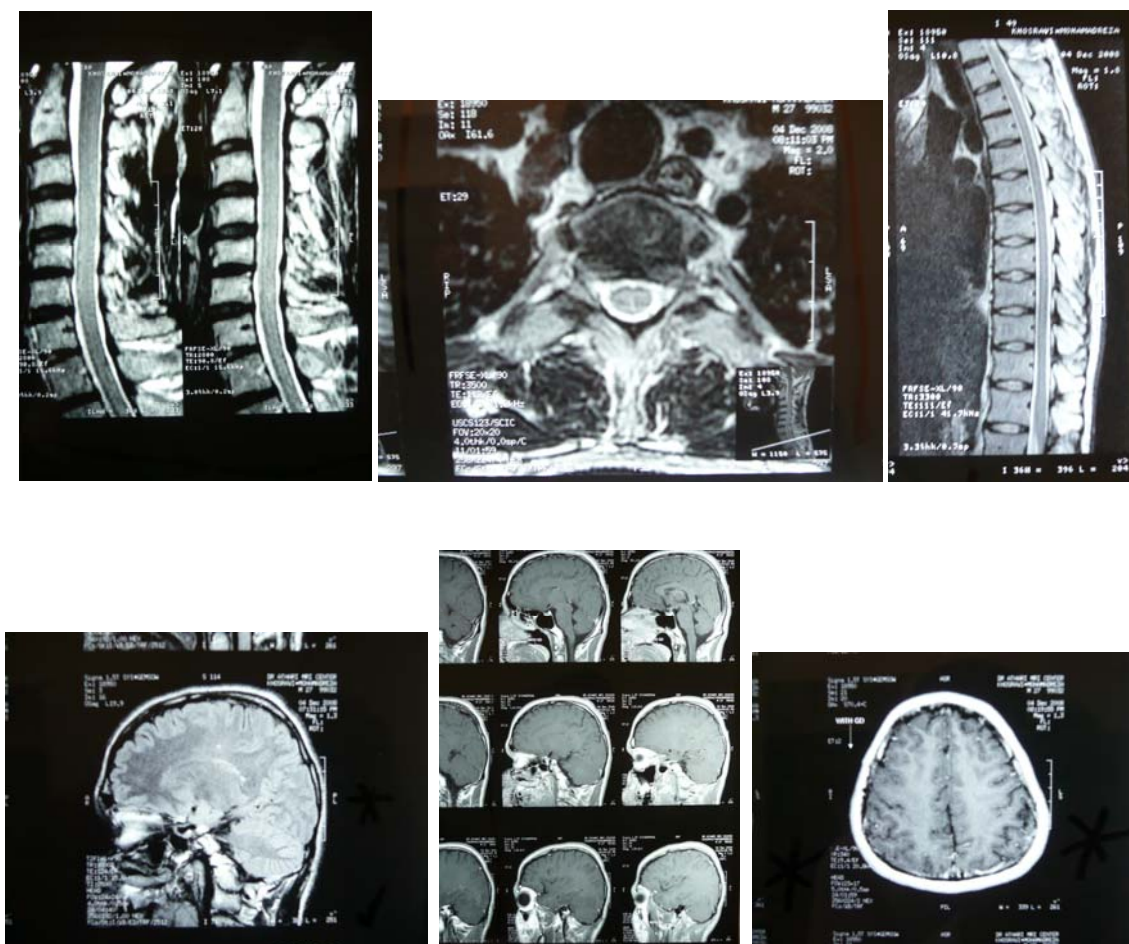


Figure 4. Brain and whole spine MRI after corticosteroid therapy show marked improvement with a few non specific hyperintensities in juxta cortical white matter

Both the usual CSF formula pressure as well as the cell count showed normal, however a moderate increase in protein was observed. Diffuse involvement of neuroaxis formed the opinion that post infectious demyelinating process may be the major cause of this involvement. The reason for such opinion formation was that primary aspergillosis had already been treated successfully and the patient was immune competent so pulse methylprednisolone 1gm/daily 3 days immediately was prescribed followed by oral corticosteroid 1mg/kg. After one week prednisolone gradually tapered that took one month to stop. During the above treatment signs and symptoms of significant recovery was observed to the extent that he was able to walk and control urination and defecation. After that, another brain and whole spine MRI was conducted that revealed marked improvement with the exception of a few non specific hyperintensities in juxtacortical white matter. No further actions were taken after this stage.

Discussion

Aspergillosis is a ubiquitous mold normally found in soil, water or decaying vegetation. Although this species may exist in mycelial or hyphal form, the hyphal form predominates at room temperature. It is an opportunistic infection affecting mainly those with immunodeficiency (5). It accounts for 5% of all intracranial fungal infections (6). The patient was immunologically competent individual because there were no underlying risk factors. There was no evidence of systemic fungal infection. His routine X-ray chest was normal. Despite the clinical evidence of immune competence, this patient developed locally invasive CNS aspergillosis. The mechanism causing invasiveness of aspergillosis in immune competent hosts remains unclear. This maybe due to either qualitative cellular or sub cellular immunodeficiency that is unrecognized or poorly characterized. Regarding mechanism of damage at the

cellular level in cerebral aspergillus lesions, recent in vitro studies have implicated secretion of various necrotizing factors with toxic and lytic activity toward neurons and glial cells (6).

Brain aspergillosis usually manifests with acute onset of focal neurological deficits resulting from a suspected vascular or space-occupying lesions. The symptoms frequently encountered include headache, vomiting, convulsions, hemiparesis, fever, cranial nerve deficits, paralysis, and sensory impairment of varying degree. Furthermore, features typical of meningitis and subarachnoid hemorrhage resulting from mycotic aneurysms may also manifest (7,8). But strangely enough, the patient did not show any signs of common presentations as mentioned above; and focal seizure was the only symptoms that presented in the patient. This represents one of the major findings of the current case.

Post infectious myelitis is an inflammatory demyelinating process that is generated as a result of an autoimmune response. Such inflammatory demyelinating disorder generally means a related disorder of acute disseminated encephalomyelitis (9); however, acute disseminated encephalomyelitis (ADEM) is a demyelinating syndrome that often occurs in association with an immunization or vaccination or systemic viral infection (post infectious encephalomyelitis). But in the present case demyelination occurred after cerebral aspergillosis. The current case reports one of the rarest causes of secondary demyelination.

Three reasons, including anti fungal drugs, products of fungus, activated autoimmune process may be causes of myelitis.

No study was found in the literature that shows the role of anti fungal drugs such as amphotericin B or itraconazole in induction of myelitis. Demyelinating process that occurred in the patient can be explained as being a secondary reactive inflammatory demyelinating process that triggered by a fungal infection. Results reported in this study suggest that there may be a basic propensity to autoimmune demyelinating process such as Multiple Sclerosis. The idea that demyelinating syndromes even multiple sclerosis may have an infective etiology is of long standing. A variety of pathogens including virus, bacteria, spirochetes, and fungal infection have been implicated in the past (12). Since no prior cases were found in the current literature, more studies are needed for validation of the results reported in the current study.

References

1. Cortet B, Richard R, Deprez X, Lucet L, Flipo RM, Le Loët X, Duquesnoy B, Delcambre B. Aspergillus spondylodiscitis: successful conservative treatment in 9 cases. *J Rheumatol* 1994;21(7):1287-91.
2. Walsh TJ, Hier DB, Caplan LR. Aspergillosis of the central nervous system: clinicopathological analysis of 17 patients. *Ann Neurol* 1985;18(5):574-82.
3. Lucchinetti C, Brück W, Parisi J, Scheithauer B, Rodriguez M, Lassmann H. Heterogeneity of multiple sclerosis lesions: implications for the pathogenesis of demyelination. *Ann Neurol* 2000;47(6):707-17.
4. Pittock SJ, Mayr WT, McClelland RL, Jorgensen NW, Weigand SD, Noseworthy JH, Weinschenker BG, Rodriguez M. Change in MS-related disability in a population-based cohort: a 10-year follow-up study. *Neurology* 2004;62(1):51-9.
5. Khoo TK, Sugai K, Leong TK. Disseminated aspergillosis. Case report and review of the world literature. *Am J Clin Pathol* 1966;45(6):697-703.
6. Siddiqui AA, Shah AA, Bashir SH. Craniocerebral aspergillosis of sinonasal origin in immunocompetent patients: clinical spectrum and outcome in 25 cases. *Neurosurgery* 2004;55(3):602-11; discussion 611-3.
7. Hall WA. Neurosurgical infections in the compromised host. *Neurosurg Clin N Am* 1992;3(2):435-42.
8. Saravia-Gomez J. Aspergillosis of the central nervous system. In: Vinken PJ, Bruyn GW, editors, *Handbook of Clinical Neurology*. Holland: North-Holland Publishing Company; 1978. p. 395-400.
9. Seres JL, Ono H, Benner EJ. Aspergillosis presenting as spinal cord compression. Case report. *J Neurosurg* 1972;36(2):221-4.
10. Craner MJ, Newcombe J, Black JA, Hartle C, Cuzner ML, Waxman SG. Molecular changes in neurons in multiple sclerosis: altered axonal expression of Nav1.2 and Nav1.6 sodium channels and Na⁺/Ca²⁺ exchanger. *Proc Natl Acad Sci U S A* 2004;101(21):8168-73. Epub 2004 May 17.
11. McDonald WI. Mechanisms of functional loss and recovery in spinal cord damage. *Ciba Found Symp* 1975;(34):23-33.
12. Macgregor JD, MacDonald J, Ingram EA, McDonnell M, Marshall B. Epidemic measles in Shetland during 1977 and 1978. *Br Med J (Clin Res Ed)* 1981;282(6262):434-6.