

A 75-Year Old Man Complaining of Flank Pain and Obstructive Urinary Symptoms: A Case Report

Mohammad-Ghasem Mohseni¹, Morteza Hamidi¹, Alborz Salavati¹, Nazir Rangzan¹, and Farid Kowsari²

¹ Department of Urology, Tehran University of Medical Sciences, Tehran, Iran

² Department of Pathology, Tehran University of Medical Sciences, Tehran, Iran

Received: 12 Jul. 2010; Received in revised form: 15 Jul. 2010 ; Accepted: 19 Jul. 2010

Abstract- Benign renal cystic adenoma with out malignant features is a very rare entity. A 75 year old male with obstructive Lower tract symptoms and vague flank pain was admitted and planned for nephrectomy of non functional kidney -due to long term nephrolithiasis- intra operative finding was a cystic hydronephrotic kidney filled by thick mucous secretions which turned out to be a cyst adenoma of kidney with no malignant features.

© 2011 Tehran University of Medical Sciences. All rights reserved.

Acta Medica Iranica 2011; 49 (7): 483-486.

Keywords: Muconephrosis; Mucinous; Renal; Benign; Tumor

Introduction

As mentioned by Campbell- Walch Urology, urothelial tumors of upper urinary tract contribute to 5-7% of all upper tract tumors, including renal pelvis tumors. They are more frequently seen in elderly and affect men more than women (1).

Although there have been several breakthroughs in the field of cytogenetics and DNA amplification techniques which led to better differentiation of vast variety of renal neoplasms according to their special chromosomal defect and mutations in different oncogenes, about 5-7 percent of renal malignancies remain in unclassified group (2). Renal tumor are grossly classified to two renal cell and epithelial groups comprising of collecting duct carcinoma, sarcomatoid RCC, Unclassified RCC, multilocular cystic RCC, Papillary adenoma, Renal medullary carcinoma, Translocation carcinoma, Mucinous tubular and spindle cell carcinoma, Carcinoma associated with end-stage renal disease, Oncocytoma and urothelial tumors (transitional cell, squamous cell) and etc (2). Among this entities there are certain mucin producing tumors mainly consisting of papillary renal cell carcinomas (2,3).

According to histological finding in this patient which has been neoplastic cells with fine papillary formation covering all epithelial surface of renal pelvis in up to 3-4 layers, it's difficult to name an exact classification for such benign looking mucin producing neoplasm. In the

small group of urothelial tumors of renal pelvis, benign entities are rare (1,2). Villous adenoma with mucin production isn't a frequent urologic malignancy although frequently present in GI tract (1,2,4), on the other hand common mucin producing neoplasms of urinary system are mainly the mucinous adenocarcinomas with definite malignant features (2). This patient share some features with each of tumors mentioned formerly, but doesn't fit in any classification completely.

Case Report

A 75-year old man presented with 4 year history of vague episodic unspecific right flank pain and mild obstructive but no irritative urinary symptoms & history of urolithiasis since his twenties; On examination revealed a RUQ mass & a prostate of 30 cc volume at DRE. On ultrasonography a large cystic pouch of 223*128 mm with fine and smooth walls was visible at the right kidney's site containing a 44 mm stone. Renal DTPA scan showed differential peak absorption of 92% and 8% for left and right kidneys.

Patient had undergone CT scan +/- IV contrast at another center which showed a hydronephrotic non-secreting right kidney containing a staghorn stone (Figure 1). Laboratory studies including urine analysis were normal. Patient was scheduled for right side nephrectomy.

Corresponding Author: Alborz Salavati

Department of Urology, Sina Hospital, Tehran University of Medical Sciences, Tehran, Iran
Tel: +98 21 66348500-9, Fax : +98 21 66737741, E-mail: alb_salavati@razi.tums.ac.ir

Flank pain and obstructive urinary symptoms

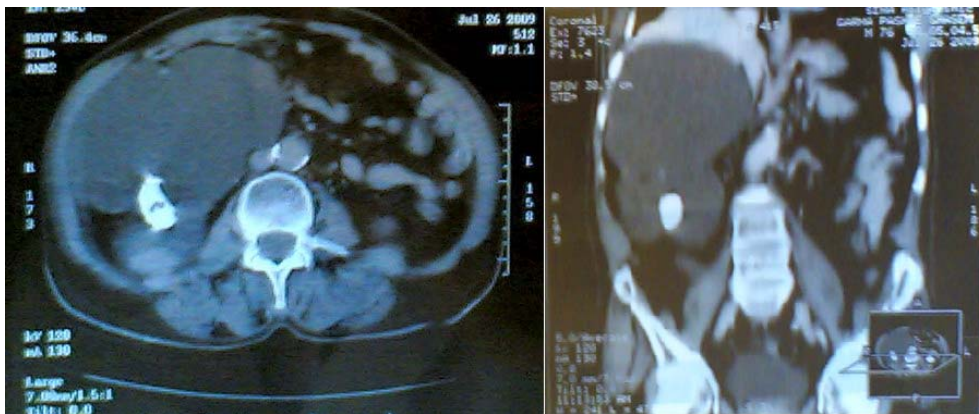

Figure 1. Abdominopelvic CT-scan

After initiation of anesthesia bladder was catheterized but surprisingly thick clear urine was encountered which wouldn't drain freely through a 16 Fr Folly catheter and was negative for protein. Through right flank incision, the right kidney was severely hydronephrotic with no palpable parenchyma, a gelatinous clear colorless to yellowish fluid had filled the cystic kidney, an extended right nephroureterectomy was performed. Cyst fluid analysis revealed undetectable glucose concentration, protein

concentration high as 650 ml/dl; cytology study of fluid was unremarkable (Figure 2).

In microscopic evaluation neoplastic mucinous epithelium full of goblet cells was lining the pelvis; papillary projections were frequent up to 2-3 layers. Whole pyelocaliceal surface was covered with neoplastic tissue (Figure 3). No atypia, mitotic forms or pleomorphism was noted in neoplastic cells. There was no stromal invasion. Final diagnosis was made as papillary mucinous cystadenoma of kidney.

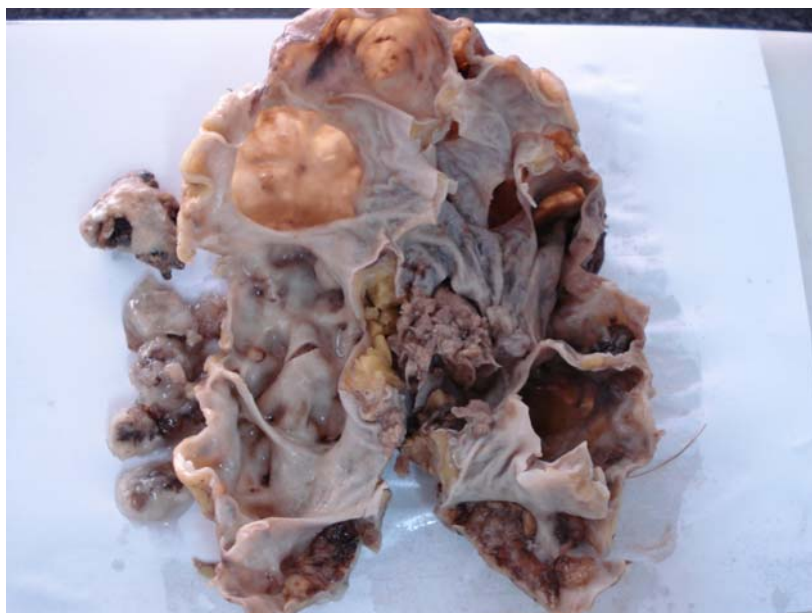

Figure 2. Gross pathology of right kidney

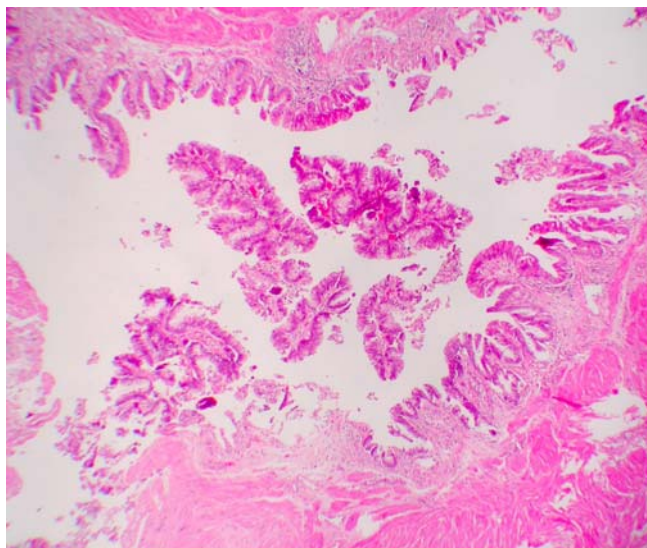


Figure 3. Layer of tall columnar cells covering pyelocaliceal system

Discussion

A cystadenoma arising from the renal pelvis is a rare neoplasm and, so far only few cases has been reported in published literature; first going back to 1985 in a middle aged woman (3) another cystadenoma plus adenocarcinoma in a middle-aged woman with ureteral involvement⁴ was reported. A 69 year old man had been nephrectomized for a renal cystic mass in 1997 had the mucinous cystadenoma of renal pelvis with malignant transformations (5). A case of mucinous cystadenoma originating from renal parenchyma had been reported in 2005 (6) and another female of her 60's has been recently reported from India who had malignant transformation in tumor (7).

There is a report (8) of 7 mucinous renal tumors that couldn't be classified according to UICC & AJCC classification² and were named as tubular low grade mucinous carcinomas of which one has invaded perirenal fat, and there has been clinical recurrence but now metastasis has been reported. Similar findings are noted by Parwani *et al.* (9) in 4 cases of low malignancy potential renal neoplasms with tendency to form tubuloid and cordlike form, all of patients were female in 2 latter studies. The only similar finding is reported in a study of mucin staining in 93 renal tumors that only 4 of them turned out positive for mucin (10).

Majority of cases were women and had malignant transformations toward adenocarcinoma. This rare case of a mucinous cyst adenoma arose from renal pelvis covering whole urothelial surface with no pleomorphism or mitotic activity. Besides this patient had this tumor

developed in a non-functioning, completely obstructed kidney due to a pelvis stone, but exact chronological sequence of stone obstruction and renal failure and tumor formation could not be evaluated. The misleading cystic radiological appearance of this entity had been once mentioned in previous literature (6) and there is another report of kidney that was nephrectomized for a xantogranulomatose pyelonephritis that turned out to be a case of muconephrosis (11). The unique characteristic of this patient is the benign microscopic findings in this neoplasm as previously mentioned. Yet the malignancy potential cannot be determined and patient's advised to anticipate follow up sessions closely. Even though this entity is very rare one must have on mind that such benign neoplasm do exist in kidney although exact natural history of tumor is yet to be further evaluated.

References

1. Flanigan RC. Urothelial tumors of the upper urinary tract. In: Wein AJ, Kavoussi LR, Novick, AC, Partin AW, Peters CA, editors. Campbell-Walsh Urology. 9th ed. Philadelphia, PA: WB Saunders; 2007. p. 1638-52.
2. Störkel S, Eble JN, Adlakha K, Amin M, Blute ML, Bostwick DG, Darson M, Delahunt B, Iczkowski K. Classification of renal cell carcinoma: Workgroup No. 1. Union Internationale Contre le Cancer (UICC) and the American Joint Committee on Cancer (AJCC). Cancer 1997;80(5):987-9.
3. Ross DG, D'Amato NA. Papillary mucinous cystadenoma of probable renal pelvic origin in a horseshoe kidney. Arch Pathol Lab Med 1985;109(10):954-5.

Flank pain and obstructive urinary symptoms

4. Arakawa M, Jimi A, Ootomi M, Ooyabu Y, Samejima H. A mucin-producing cystadenoma, borderline malignancy, of the renal pelvis and ureter: a case report. *Gan No Rinsho* 1989;35(4):499-504.
5. Toyoda H, Mabuchi T, Fukuda K. Mucinous cystadenoma with malignant transformation arising in the renal pelvis. *Pathol Int* 1997;47(2-3):174-8.
6. Akan H, Dalva I, Yildiz O, Kutluay L, Gündoğdu S, Güngen Y. Mucinous cystadenoma mimicking simple renal parenchymal cyst in a horseshoe kidney. *Int J Urol* 2005;12(5):493-6.
7. Mardi K, Sharma J, Mahajan P. Mucinous cystadenoma of the renal pelvis with malignant transformation: a case report. *Indian J Pathol Microbiol* 2006;49(4):595-6.
8. Rakozy C, Schmahl GE, Bogner S, Störkel S. Low-grade tubular-mucinous renal neoplasms: morphologic, immunohistochemical, and genetic features. *Mod Pathol* 2002;15(11):1162-71.
9. Parwani AV, Husain AN, Epstein JI, Beckwith JB, Argani P. Low-grade myxoid renal epithelial neoplasms with distal nephron differentiation. *Hum Pathol* 2001;32(5):506-12.
10. Val-Bernal JF, Pinto J, Gómez-Román JJ, Mayorga M, Villoria F. Papillary adenoma of the kidney with mucinous secretion. *Histol Histopathol* 2001;16(2):387-92.
11. Park S, Meng MV, Greenberg MS, Deng DY, Stoller ML. Muconephrosis. *Urology* 2002;60(2):344.