

The Diagnostic Accuracy of High Resolution Ultrasound Imaging for Detection of Secondary Hyperparathyroidism in Patients with Chronic Renal Failure

Hassan Anari¹, Bahman Bashardoust², Masoud Pourissa³, and Soheila Refahi^{4,5}

¹ Department of Radiology, Ardebil University of Medical Sciences, Ardebil, Iran

² Department of Dialysis, Ardebil University of Medical Sciences, Ardebil, Iran

³ Department of Radiology, Neurosciences Research Center, Tabriz University of Medical Sciences, Tabriz, Iran

⁴ Department of Medical Physics, Faculty of Medicine, Ardebil University of Medical Sciences, Ardebil, Iran

⁵ Departments of Physics and Medical Engineering, Faculty of Medicine, Tehran University of Medical Sciences, Tehran, Iran

Received: 27 Jul. 2010; Received in revised form: 3 Dec. 2010; Accepted: 17 Jan. 2011

Abstract- Ultrasound is one of the preferred modalities for evaluation of the parathyroid glands. This study was undertaken to determine the accuracy of high resolution ultrasound for secondary hyperparathyroidism in patients with chronic renal failure. From March 2008 to March 2009, ninety-one hemodialysis patients were examined by high resolution ultrasound (14 MHz) of the parathyroid glands in comparison to parathyroid hormone level. 43.9% of patients showed enlarged parathyroid glands with an average of 8.7 mm. The mean parathyroid hormone level of patients with enlarged parathyroid glands on sonography was 503 ± 450 pg/ml. We observed a significant correlation between parathyroid hormone level and enlarged parathyroid glands ($P < 0.0001$). Sensitivity and specificity of sonography for detection of secondary hyperparathyroidism were 62.5% and 85.7% respectively. In conclusion, our study showed that high resolution sonography is a useful noninvasive method for the evaluation of secondary hyperparathyroidism in patients on hemodialysis and that sonographically enlarged glands may be a measure of severity of secondary hyperparathyroidism.

© 2011 Tehran University of Medical Sciences. All rights reserved.

Acta Medica Iranica 2011; 49(8): 527-530.

Keywords: High resolution ultrasound; Secondary hyperparathyroidism; Chronic renal failure; Hemodialysis

Introduction

Secondary hyperparathyroidism (sHPT) is one of the main features of bone disease seen in chronic dialysis patients. This abnormality is characterized by the high-turnover bone disease caused by excess parathyroid hormone (PTH) secreted from hyperplastic parathyroid glands (1). Imaging of the parathyroid can be performed with nuclear medicine, ultrasound, CT, and MRI. Indications for parathyroid imaging studies have recently changed. The availability of experienced endocrine surgeons, as well as the development of accurate laboratory tests, fine-needle aspiration (FNA) biopsy, and high-resolution ultrasound, has dramatically influenced the evaluation of parathyroid disease (2). The accuracy of imaging techniques is directly related to the examiner experience, equipment available, and parathyroid pathology involved (3). Severity of sHPT

has been evaluated mainly by the level of PTH. It is now well established that serum PTH is the gold standard for diagnosis of secondary hyperparathyroidism. However, parathyroid size can be an alternative marker (4). The objective of the present approach was to assess the sensitivity, specificity, and positive and negative predictive values of high resolution sonography for the diagnosis of sHPT.

Patients and Methods

High-resolution sonography of the neck was performed in 91 patients undergoing renal dialysis to determine the usefulness of sonography in the evaluation of sHPT. This study was conducted within the Department of Radiology at Imam Hospital, Ardebil University of Medical Sciences (northwest of Iran) between March 2008 and March 2009. All ultrasound examinations

Corresponding Author: Soheila Refahi

Department of Medical physics, Faculty of Medicine, Ardebil University of Medical Sciences, Ardebil, Iran

Departments of Physics and Medical Engineering, Faculty of Medicine, Tehran University of Medical Sciences, Tehran, Iran

Tel: +98 451 5513428, 914 4142689, Fax: +98 451 5510057, E-mail: s.refahi@arums.ac.ir, refahi@razi.tums.ac.ir

were performed by an expert sonologist with 12 years of experience using a high resolution real time linear ultrasound unit (model ultrasonix SP) with 10-14 MHz multi frequency probe. Sonographic studies were performed without knowledge of the patients' symptoms or the results of PTH assays. Patients were positioned with their necks hyperextended so that the entire neck could be evaluated from the mandible to the thoracic inlet. The neck in the area of the thyroid was examined first. If no enlarged parathyroid gland (EPTGs) was detected, further evaluation of the neck above and below the thyroid was performed. Parathyroid glands were evaluated for size. PTH levels were measured in all patients by electrochemiluminescence immunoassay (ECLIA), E170/Elecyc2010 model (Roche). Comparison of the sonographic findings and PTH was performed and data were analyzed. The sensitivity, specificity, and positive and negative predictive values were determined for sonographic assessment, for predicting the presence of sHPT.

Results

A total of ninety-one patients who underwent renal dialysis were analyzed. 30/91 (33%) were women and 61/91 (67%) patients were men. Average age of patients was 53.6 ± 16.1 (age range 15-83) years. The sonograms in 40/91 (43.9%) patients showed EPTGs, with an average size of 8.7 mm. Ultrasound image representative of EPTG is shown in Figure 1. The mean PTH level of patients was 283 ± 366 pg/ml (rage: 2 to 1755pg/ml). The PTH level in patients with and without EPTGs on

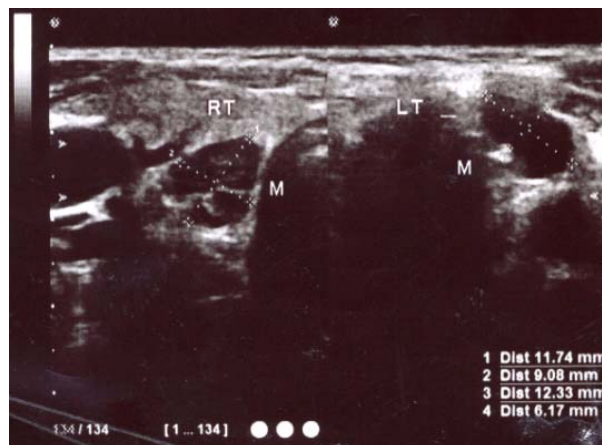


Figure 1. Enlarged parathyroid gland in secondary parathyroidism caused by chronic renal failure

sonography is presented in Table 1. There was a statistically significant difference in PTH levels between two groups using t-test ($P=0.0001$).

Comparison of the sonographic findings and laboratory test of PTH level are demonstrated in Table 2.

The sensitivity of sonography for diagnosis of EPTGs was 62.5% ($CI_{95\%}$: 52.6%-72.4%), the specificity was 85.7%, the positive predictive value (PPV) 87.5%, the negative predictive value (NPV)58.8%, the positive likelihood ratio (LR^+) was 4.37, and the negative likelihood ratio (LR^-) was 0.43.

Sonographic findings were inconsistence from laboratory test of PTH level in 26 of 91 patients. A correct sonographic diagnosis was obtained in 65 of 91 patients yielding a sensitivity of 71.4% ($CI_{95\%}$: 62.2%-80.6%).

Table 1. Summary of PTH level of patients with chronic renal failure (n=91)

Results on sonography	No (%)	Mean (pg/ml)	SD (pg/ml)
Present EPTGs	40 (43.9)	503	450.03
Absent EPTGs	51 (56.1)	117	143.22

Table 2. Comparison of results as assessed by sonography and PTH level

Sonography	PTH level		Total
	Positive (≥ 65 pg/ml)	Negative (< 65 pg/ml)	
Positive (present of EPTGs)	35	5	40
Negative (absent of EPTGs)	21	30	51
Total	56	35	91

Discussion

High-resolution real time sonography performed by using a 7.5 or 10 MHz transducer can provide better images of small parts in superficial organs (5). The progression of chronic renal failure (CRF) is associated with presence of bone disease and hyperplasia of parathyroid glands (6). A large population of patients maintained on long-term dialysis exists who develop severe sHPT (7). Hyperparathyroidism is a relatively common disease, especially among patients suffering from chronic renal failure (CRF) (8). In CRF insufficiency secondary hyperparathyroidism occurs as a result of parathyroid cell hyperplasia with enlargement of the parathyroid glands (9). Prolonged renal failure decreases ionized-calcium levels and increases retention of serum phosphate (10, 11). This directly stimulates the parathyroid glands to secrete more parathyroid hormones in the body (12). sHPT means that external factors stimulate the parathyroid glands to increase the production of PTH (13). The most common condition causing sHPT is CRF, an insidious disease that develops early in the course of the chronic kidney disease and increases in severity as the glomerular filtration rate deteriorates. Basically, imaged-based localizing tests depend on gland size; therefore, because patients with sHPT tend to have large glands, the specificity and positive value of sonography is much greater for sHPT than for primary hyperplasia (14). Sonography has been useful for the screening and follow up of patients with sHPT and may contribute to indication for surgery by estimating the size of enlarged glands. It has a reported sensitivity of 45-70% (13). It has been well documented in the literature that high resolution gray scale sonography is highly accurate in localizing EPTGs (15). Some more invasive methods have a good sensitivity and should be used in the event of reoperations such as intravenous PTH sampling (16, 17). Based on our results sensitivity, specificity and PPV of high resolution sonography for diagnosis of EPTGs was 62.5%, 85.7%, and 87.5%, respectively. Similar study by Aysum *et al.*, documented that in sHPT sonography had sensitivity of 60%, a specificity of 91%, PPV of 92% (18). Another study by Nidal *et al.*, indicated that the sensitivity of ultrasound is 39%, PPV 64%. Their findings were comparable with the results of our study (39%, 62.5%), respectively. It seems to be because of glandular size, weight, experience of physician and sensitivity of the probe (19). Arnold *et al.*, in their work demonstrated that sensitivity and specificity using high resolution real time sonography (7.5 MHz) for

evaluation of parathyroid glands is 57%, 96%, respectively (20). Comparison of our approach to others indicated that sensitivity of high resolution ultrasound (14 MHz) is higher than the 7.5 MHz. In conclusion, our results show that high resolution ultrasound is an effective noninvasive method in diagnosis of sHPT in patients with CRF and that sonographically enlarged glands may be a measure of severity of secondary hyperparathyroidism.

References

1. Malluche H, Faugere MC. Renal bone disease 1990: an unmet challenge for the nephrologist. *Kidney Int* 1990; 38(2):193-211.
2. Hopkins CR, Reading CC. Thyroid and parathyroid imaging. *Semin Ultrasound CT MR* 1995; 16(4):279-95.
3. Renato Roithmann, Shia Salem, Joel C Kirsh, Edward E Kassel, Irving B Rosen, Arnold M Noyek. Parathyroid imaging. *Operative Techniques in Otolaryngology-Head and Neck Surgery* 1994;5(2):84-90.
4. Fukagawa M, Kurokawa K. Pathogenesis and medical treatment of secondary hyperparathyroidism. *Semin Surg Oncol* 1997; 13(2):73-7.
5. Takebayashi S, Matsui K, Onohara Y, Hidai H. Sonography for early diagnosis of enlarged parathyroid glands in patients with secondary hyperparathyroidism. *AJR Am J Roentgenol* 1987; 148(5):911-4.
6. Muros MA, Bravo Soto J, López Ruiz JM, Rodríguez-Portillo M, Ramírez Navarro A, Bellón Guardia M, Perán F, Llamas-Elvira JM. Two-phase scintigraphy with technetium 99m-sestamibi in patients with hyperparathyroidism due to chronic renal failure. *Am J Surg* 2007; 193(4):438-42.
7. Robert Udelsman. Secondary hyperparathyroidism. *Operative Techniques in General Surgery* 1999;1(1):62-70.
8. Obregón LM, Taylor MF, Mir G, Pereyra CA, Pianzola H, Petrone H, Baran M, Menna ME. Parathyroidectomy for parathyroid carcinoma in renal transplantation. *Transplant Proc* 2005; 37(2):973-6.
9. Jevtic V. Imaging of renal osteodystrophy. *Eur J Radiol* 2003; 46(2):85-95.
10. DiTella PJ, Lang GR. Parathyroid dysfunction end stage renal disease. *Otolaryngol Clin North Am* 1980; 13(1):193-201.
11. Peacock M. Primary hyperparathyroidism and the kidney: biochemical and clinical spectrum. *J Bone Miner Res*. 2002; 17 Suppl 2:N87-94.
12. Canellos HM, Cooper J, Paek A, Chien J. Multiple calcified deposits along the eyelid margins secondary to chronic renal failure and hyperparathyroidism. *Optometry* 2005; 76(3):181-4.

Accuracy of high resolution ultrasound imaging in diagnosis of hyperparathyroidism

13. Thierry Defechereux, Michel Meurisse. Renal hyperparathyroidism: Current therapeutic approaches and future directions. *Operative Techniques in Otolaryngology-Head and Neck Surgery* 2009;20(1):71-8.
14. Sancho J, Sitges-Serra A: Metabolic complications of secondary hyperparathyroidism, in Clark O, Duh Q, Kebebew E (eds): *Textbook of Endocrine surgery*. Philadelphia, Elsevier. Saunders, 2005, pp502-509
15. Ozcan UA, Oktay I. Assessment of parathyroid glands in hemodialysis patients by using color Doppler sonography. *Eur Radiol* 2009; 19(11):2750-5.
16. Seehofer D, Steinmüller T, Rayes N, Podrabsky P, Riethmüller J, Klupp J, Ulrich F, Schindler R, Frei U, Neuhaus P. Parathyroid hormone venous sampling before reoperative surgery in renal hyperparathyroidism: comparison with noninvasive localization procedures and review of the literature. *Arch Surg* 2004;139(12):1331-8.
17. Reidel MA, Schilling T, Graf S, Hinz U, Nawroth P, Büchler MW, Weber T. Localization of hyperfunctioning parathyroid glands by selective venous sampling in reoperation for primary or secondary hyperparathyroidism. *Surgery* 2006; 140(6):907-13.
18. Sukan A, Reyhan M, Aydin M, Yapar AF, Sert Y, Canpolat T, Aktas A. Preoperative evaluation of hyperparathyroidism: the role of dual-phase parathyroid scintigraphy and ultrasound imaging. *Ann Nucl Med* 2008; 22(2):123-31.
19. Younes NA, Hadidi AM, Mahafzah WS, Tarawneh ES, Al-Khatib YF, Sroujeh AS. Accuracy of single versus combined use of ultrasonography or computed tomography in the localization of parathyroid adenoma. *Saudi Med J* 2008; 29(2):213-7.
20. Arnold J, Krubsack, Stuart D, Wilson, T. L. Lawson, B. David Collier, Robert S. Hellman and Ali T. Isitman. Prospective comparison of radionuclide, computed tomographic, and sonographic localization of parathyroid tumors. *World Journal of Surgery*, 1986;10(4).