

Immunohistochemical Expression of Vascular Endothelial Growth Factor and Its Correlation with Tumor Grade in Breast Ductal Carcinoma

Maryam Ghasemi¹, Omid Emadian¹, Farshad Naghshvar¹, Ahmadreza Bekhradnia²,
Saeid Abediankenari³, Laleh Vahedi Larijani¹, and Roghaieh Moghimpour¹

¹ Department of Pathology, Mazandaran University of Medical Sciences, Sari, Iran

² Department of Chemistry, Mazandaran University of Medical Sciences, Sari, Iran

³ Department of Immunology, Mazandaran University of Medical Sciences, Sari, Iran

Received: 30 Jul. 2011; Received in revised form: 2 Sep. 2011; Accepted: 29 Sep. 2011

Abstract- Breast cancer is the most common cause of cancer-related death in female, after lung cancer. Angiogenesis is essential for tumor growth and metastasis; therefore, antiangiogenesis strategies for treatment of cancer are currently an issue of interest. The role of vascular endothelial growth factor that assumed to be most potent angiogenesis factor is ambiguous in breast cancer. This study described the correlation between vascular endothelial growth factor expression and tumor grade, to define the breast cancer patients who responder to anti-vascular endothelial growth factor therapy. In this research, 200 cases of histological proved invasive ductal breast carcinomas analyzed for vascular endothelial growth factor expression by immunohistochemical staining via cross-sectional descriptive study. Vascular endothelial growth factor expressed in 72.54% of the breast cancers. The VEGF was more detectable in grade I (78.5%) than grade II (77.4%) and grade III (56.2%). There is a significant correlation between tumor grade and VEGF expression ($P < 0.05$). According to this study, VEGF often expressed in invasive ductal breast carcinomas and inversely correlated with tumor grade. Anti-vascular endothelial growth factor postulated more convenience for tumor progression suppression in low grade tumor than high grade tumor.

© 2011 Tehran University of Medical Sciences. All rights reserved.

Acta Medica Iranica, 2011; 49(12): 776-779.

Keywords: VEGF; Breast neoplasms; Angiogenesis

Introduction

Breast cancer is the most problematic malignancy in women resulting to death in about one-fourth of cases. To date, many efforts performed to identify prognostic factors and their relevant therapeutic agents (1). Angiogenesis is essential for tumor growth and invasiveness (2-6). Thus, assessment of malignant tumors capacity to producing new vascular channels provide a key prognostic factor of survival (2,3). Currently angiogenesis factors and anti- angiogenesis strategies for treatment of breast cancer are a subject of scientific interest (2,3,6,7-18).

Vascular endothelial growth factor (VEGF) plays a main role in angiogenesis and metastasis (2,5). However, in breast cancer tumor, microvessels density is now known as an independent factor for predicting metastasis and overall survival rate (2,3,11,13). The prognostic value of immunohistochemical (IHC)

analysis of direct VEGF expression by tumor cells is not yet clarified (2,7,8,13,17-20). Previous studies have reported large varied VEGF expression in breast cancer (2,12,13,19). The relations of VEGF with other clinicopathologic features of breast cancer remain uncertain (2,12,13,17,18). There is some molecular evidence of high VEGF mRNA levels in invasive breast ductal carcinomas (IBDCs) (6). Although gene study is a sensitive technique, it lacks specificity to distinguish among different cells, and it may be contaminated by other cells such as macrophages (20). In addition, gene profile analysis is complex and inconvenient for routine clinical use (6). The correlation of tumor VEGF expression with tumor grade is unclear and controversial (2,15-18,21).

Information about the effect of bevacizumab, an antibody targeting VEGF, is limited in breast cancers (21-23). The relationship of serum VEGF Concentration due to contamination by platelet derived VEGF with

breast cancer outcome have remained inconclusive (2). We analyzed VEGF expression and its correlation with grade of IDBCs, the most common malignancy of breast, by using IHC staining a reliable and convenient method for practical use to introduce the patients more responsive to anti-VEGF agents before their cancer progression.

Materials and Methods

This descriptive cross-sectional research included 200 paraffin-embedded blocks of histological proved IDBCS that diagnosed in university-affiliated pathology department during 2001 till 2006.

All blocks were submitted for sectioning with 4 μ m thickness. The tumor grade was determined by histological examination of hematoxyline and eosin stained slides according to modified Bloom-Richardson system (1). The additional sections of tumors were stained by IHC method for VEGF. IHC staining was performed by using VEGF antibody (Novus biological, USA) according to established streptavidin-biotin-peroxidase technique and the positive immune reaction visualized by diaminobenzidine.

Prostatic adenocarcinoma and normal mammary tissue were considered as positive and negative control

respectively. The immunostained slides were examined by light microscopy according to manufacture advice. IF 10% or more tumor cells demonstrated intense or moderate cytoplasm staining, the case was considered positive for VEGF.

Statistical analysis

We processed data with SPSS software version17. Chi-square test was used for the statistical analysis of gathered data. *P* value below 0.05 was considered statistically significant.

Results

This study was performed on 200 cases of IDBCS. The mean age of breast cancer patients were 53.50 ± 20.32 at the time of their cancer diagnosed. 14% of tumors were classified as grade I, 61% Grade II and 25% grade III.

VEGF was detected by IHC staining in 72.5% (145 numbers) of IDCBS (illustrated by figure 1). VEGF more expressed in tumors grade I (78/5%), than grade II (77.4%) and grade III (56.2%) (Figure 2). There was a meaningful inverse correlation between VEGF expression and microscopic grade of IDBCS ($P < 0.05$). VEGF expression was unrelated with patient's age.

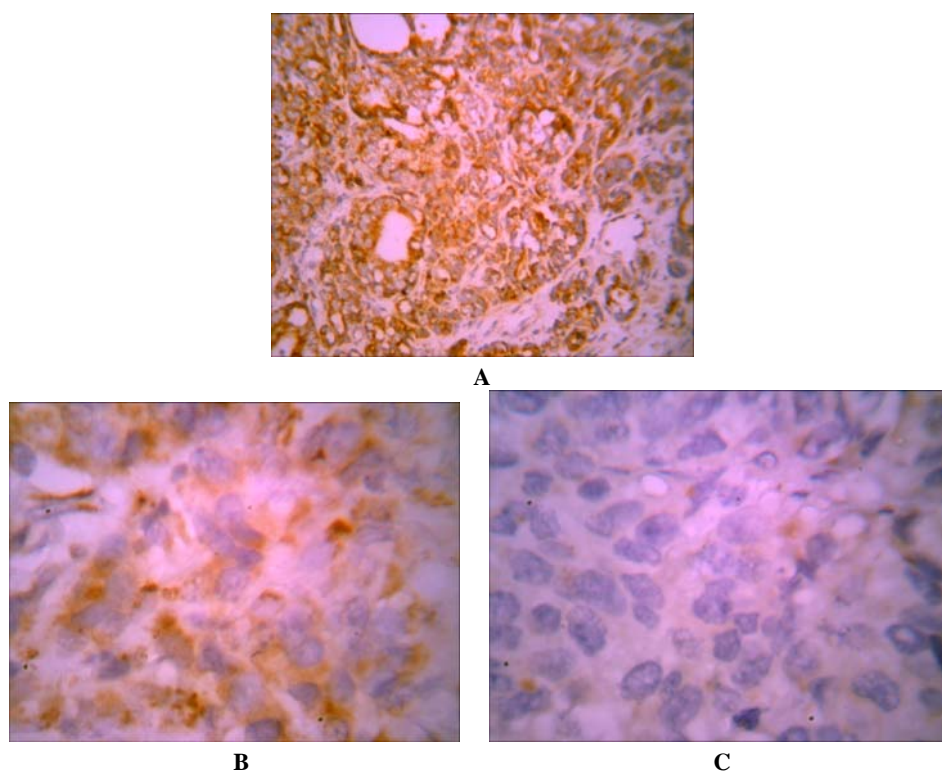


Figure 1. VEGF expression is illustrated by IHC. A: positive prostatic adenocarcinoma as control, B: positive Breast cancer case, C: Negative mammary Tissue as control.

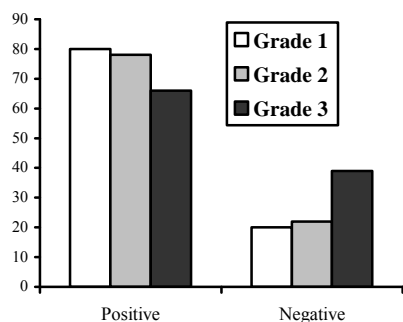


Figure 2. VEGF expression frequency (%) according to tumor grade

Discussion

Breast cancer is an ominous malignancy compromise the most common malignancy only second to skin cancers among female (1).

Despite to early diagnosis, it is the most common cause of cancer-related deaths in this gender after lung cancer (1); therefore, assessment of factors promoting tumor progression is warranted (1,2).

Angiogenesis is essential for tumor growth and invasiveness. VEGF is presumed to be the most potent stimulant and key regulator for angiogenesis (2,5).

Antiangiogenic agents targeting VEGF signaling pathway has been suggested as a promising approach for cancer treatment. However, information about immunohistochemical tumor expression of VEGF and its correlation with microscopic grade is still limited and controversial in IDBCS.

This study analyzed VEGF expression by IHC in a large Iranian sample of IDBCS based on the recent report indicating genetic polymorphism influences its characters (24).

We detected VEGF in 72.5% of IDBCS which is more than cases were reported by in Hoar *et al.* (12). There are some controversies about correlation between VEGF expression and tumor grade. Direct or no correlation have been shown by some studies (15-18), however in consistence with Adams *et al.* report (2), our results showed an inverse correlation, as well.

As reported by several studies, the high grade tumor have more microvessels density compared to more differentiated low grade tumors (2,3,10,13,14). We presumed the observed lower level of VEGF content in high grade tumors might be due to consumption of this factor during their growth and angiogenesis.

Acknowledgement

This study was supported by grant from Mazandaran University of Medical Sciences. We thank Dr. Alireza Khalilian and Mrs. Zarrabian contributed to this work.

References

1. Lester SC. The breast. In: Kumar V, Abbas AK, Fausto N, Aster JC, editors. Robbins and Cotran Pathologic Basis of Disease, 8th Edition. Philadelphia: Elsevier Saunders; 2010. p. 1066-94.
2. Adams J, Carder PJ, Downey S, Forbes MA, MacLennan K, Allgar V, Kaufman S, Hallam S, Bicknell R, Walker JJ, Cairnduff F, Selby PJ, Perren TJ, Lansdown M, Banks RE. Vascular endothelial growth factor (VEGF) in breast cancer: comparison of plasma, serum, and tissue VEGF and microvessel density and effects of tamoxifen. *Cancer Res* 2000;60(11):2898-905.
3. Rykala J, Przybylowska K, Majsterek I, Pasz-Walczak G, Sygut A, Dziki A, Kruk-Jeromin J. Angiogenesis markers quantification in breast cancer and their correlation with clinicopathological prognostic variables. *Pathol Oncol Res* 2011;17(4):809-17.
4. Wu S, Wu X, Zhu W, Cai WJ, Schaper J, Schaper W. Immunohistochemical study of the growth factors, aFGF, bFGF, PDGF-AB, VEGF-A and its receptor (Flk-1) during arteriogenesis. *Mol Cell Biochem* 2010;343(1-2):223-9.
5. Wilgus TA, Matthies AM, Radek KA, Dovi JV, Burns AL, Shankar R, DiPietro LA. Novel function for vascular endothelial growth factor receptor-1 on epidermal keratinocytes. *Am J Pathol* 2005;167(5):1257-66.
6. Hu Z, Fan C, Livasy C, He X, Oh DS, Ewend MG, Carey LA, Subramanian S, West R, Ikpat F, Olopade OI, van de Rijn M, Perou CM. A compact VEGF signature associated with distant metastases and poor outcomes. *BMC Med* 2009;7:9.
7. Allred DC, Harvey JM, Berardo M, Clark GM. Prognostic and predictive factors in breast cancer by immunohistochemical analysis. *Mod Pathol* 1998;11(2): 155-68.
8. Fox SB, Generali DG, Harris AL. Breast tumour angiogenesis. *Breast Cancer Res* 2007;9(6):216.
9. Zhang XH, Huang DP, Guo GL, Chen GR, Zhang HX, Wan L, Chen SY. Coexpression of VEGF-C and COX-2 and its association with lymphangiogenesis in human breast cancer. *BMC Cancer* 2008;8:4.

10. Wülfing P, Kersting C, Tio J, Fischer RJ, Wülfing C, Poremba C, Diallo R, Böcker W, Kiesel L. Endothelin-1-, endothelin-A-, and endothelin-B-receptor expression is correlated with vascular endothelial growth factor expression and angiogenesis in breast cancer. *Clin Cancer Res* 2004;10(7):2393-400.
11. Zhu L, Loo WT, Louis WC. PTEN and VEGF: possible predictors for sentinel lymph node micro-metastasis in breast cancer. *Biomed Pharmacother* 2007;61(9):558-61.
12. Hoar FJ, Chaudhri S, Wadley MS, Stonelake PS. Co-expression of vascular endothelial growth factor C (VEGF-C) and c-erbB2 in human breast carcinoma. *Eur J Cancer* 2003;39(12):1698-703.
13. Nakamura Y, Yasuoka H, Tsujimoto M, Yang Q, Tsukiyama A, Imabun S, Nakahara M, Nakao K, Nakamura M, Mori I, Kakudo K. Clinicopathological significance of vascular endothelial growth factor-C in breast carcinoma with long-term follow-up. *Mod Pathol* 2003;16(4):309-14.
14. Li YS, Kaneko M, Amaty VJ, Takeshima Y, Arihiro K, Inai K. Expression of vascular endothelial growth factor-C and its receptor in invasive micropapillary carcinoma of the breast. *Pathol Int* 2006;56(5):256-61.
15. Guo XJ, Chen L, Lang RG, Fan Y, Fu L. Relationship between lymph node metastasis and pathologic features of invasive micropapillary carcinoma of breast. *Zhonghua Bing Li Xue Za Zhi* 2006;35(1):8-12.
16. Guo X, Chen L, Lang R, Fan Y, Zhang X, Fu L. Invasive micropapillary carcinoma of the breast: association of pathologic features with lymph node metastasis. *Am J Clin Pathol* 2006;126(5):740-6.
17. Al-Dissi AN, Haines DM, Singh B, Kidney BA. Immunohistochemical expression of vascular endothelial growth factor and vascular endothelial growth factor receptor-2 in canine simple mammary gland adenocarcinomas. *Can Vet J* 2010;51(10):1109-14.
18. Longatto Filho A, Martins A, Costa SM, Schmitt FC. VEGFR-3 expression in breast cancer tissue is not restricted to lymphatic vessels. *Pathol Res Pract* 2005;201(2):93-9.
19. Kamath A, Helie M, Bifulco CB, Li WW, Concato J, Jain D. Lack of immunohistochemical detection of VEGF in prostate carcinoma. *Appl Immunohistochem Mol Morphol* 2009;17(3):227-32.
20. Bellamy WT, Richter L, Sirjani D, Roxas C, Glinsmann-Gibson B, Frutiger Y, Grogan TM, List AF. Vascular endothelial cell growth factor is an autocrine promoter of abnormal localized immature myeloid precursors and leukemia progenitor formation in myelodysplastic syndromes. *Blood* 2001;97(5):1427-34.
21. Ferrara N, Hillan KJ, Gerber HP, Novotny W. Discovery and development of bevacizumab, an anti-VEGF antibody for treating cancer. *Nat Rev Drug Discov* 2004;3(5):391-400.
22. Jain RK, Duda DG, Clark JW, Loeffler JS. Lessons from phase III clinical trials on anti-VEGF therapy for cancer. *Nat Clin Pract Oncol* 2006;3(1):24-40.
23. Burstein HJ, Chen YH, Parker LM, Savoie J, Younger J, Kuter I, Ryan PD, Garber JE, Chen H, Campos SM, Shulman LN, Harris LN, Gelman R, Winer EP. VEGF as a marker for outcome among advanced breast cancer patients receiving anti-VEGF therapy with bevacizumab and vinorelbine chemotherapy. *Clin Cancer Res* 2008;14(23):7871-7.
24. Mohammadi M, Day PJ. The influence of immunosuppressive drugs on vascular endothelial growth factor production in relation to VEGF -1154 g and -2578 C genotypes. *Iran J Immunol* 2010;7(4):217-25.