

Incidence of Incomplete Excision in Surgically Treated Cutaneous Squamous Cell Carcinoma and Identification of the Related Risk Factors

Mostafa Mirshams¹, Mahmood Razzaghi², Pedram Noormohammadpour¹,
Zahra Naraghi³, Kambiz Kamyab³, and Sara Sabouri Rad¹

¹ Department of Dermatology, Razi Hospital, Tehran University of Medical Sciences, Tehran, Iran

² Department of Plastic Surgery, Razi Hospital, Tehran University of Medical Sciences, Tehran, Iran

³ Department of Pathology, Razi Hospital, Tehran University of Medical Sciences, Tehran, Iran

Received: 24 Nov. 2010; Received in revised form: 9 Aug. 2011; Accepted: 29 Aug. 2011

Abstract- Squamous cell carcinoma (SCC) is the second most common type of skin cancer with potential risks for metastasis and recurrence if left untreated or incompletely excised. This case series study was designed to determine the frequency of incompletely excised SCCs and the related risk factors. A total of 273 SCCs (253 patients) excised in Razi dermatology hospital of Tehran from 2006-2008, were evaluated and were analyzed by Chi-square or t-test. The incidence of incomplete excision was 17.58 % and deep margin involvement was observed in 73% of lesions. Risk factors associated with incomplete excision of SCCs were being female, location of the tumors (in particular the lesions on lateral canthus, upper lip, foot, forehead, cheek, neck, nose and ear), large lesions and grafting method of repair. There was no statistically significant difference for the age, degree of histological differentiation, childhood history of radiotherapy for tinea capitis and the type of anesthesia. More care should be taken for high risk SCCs as complete excision avoids potential risk of recurrence and metastasis.

© 2011 Tehran University of Medical Sciences. All rights reserved.

Acta Medica Iranica, 2011; 49(12): 806-809.

Keywords: Cutaneous squamous cell carcinoma; Incomplete excision

Introduction

Squamous cell carcinoma (SCC) is the second most common type of skin cancer with potential risks for metastasis and recurrence if left untreated or incompletely excised (1,2). The incidence of incomplete excision is reported to be between 6.3-15.9% in previous studies (1-3). There are a few studies with focus on the incidence of incomplete incision of SCC and most studied have not evaluate SCC separately (1-6). This study was designed to identify the frequency of this problem and related risk factors in Razi dermatology hospital (Tehran, Iran). These findings help surgeons to recognize the high risk tumors and consider wider excision margin.

Materials and Methods

This case series study was performed in Razi dermatology hospital of Tehran (Iran) during 2006-2008 and the surgically treated SCCs were evaluated. Punch,

shave and incisional biopsies and incomplete data were excluded. All patients were visited by a dermatologist and a plastic surgeon in this center and data required were completed by them including age, sex, tumor site and size, history of childhood radiotherapy for tinea capitis, method of repair and type of anesthesia. Chi-square test was used for statistical analysis. The mean of age was compared with t-test. *P*-values less than 0.05 were considered significant. Excised samples were sent to the department of pathology and were assessed by a pathologist. The histology report contained the histological subtype and details of excision. An incomplete margin was defined by the pathologist as the presence of tumor at the surgical margin.

Results

During the three years, 273 SCCs excised from 253 patients with incomplete excision rate of 17.58% (48 lesions). The deep margin was involved in 73% of samples (Figure 1).

Corresponding Author: Sara Sabouri Rad

Department of Dermatology, Razi Hospital, Tehran University of Medical Sciences, Tehran, Iran

Tel: +98 21 55618989, 915 3041833, Fax: +98 21 55618989, E-mail: dr.sabori@yahoo.com

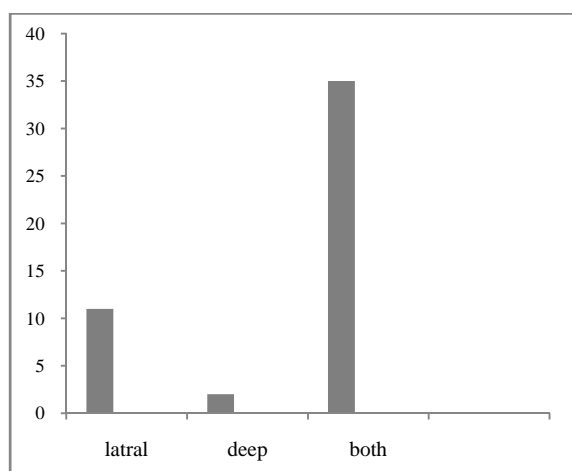


Figure 1. Frequency of the involved margin in the incompletely excised group

The mean age of completely excised group was 66.1 years and the mean age of incompletely excised group was 63 years which was not statistically significant.

The rate of incomplete excision was 27.1% for women and 15.1% for men. This difference was statistically significant with P -value of 0.049 (Table1).

The percentage of incomplete excision was 17.6% for head and neck and 17.8% for the limbs. All the SCCs excised from body had free margins. Statistically significant differences were not observed. The most common sites of incomplete excision were lateral canthus, upper lip, foot, forehead, cheek, neck, nose and ears with incomplete excision percentage of 66.7%, 40%, 37.5%, 33.3%, 25%, 25%, 19.2% and 18.2% respectively. These differences were statistically significant ($P=0.004$) (Figure 2). The rate of incomplete excision was 37% for low differentiated SCCs, 24.1% for moderately differentiated SCCs, 15.2% for well

differentiated ones and 7.7% for *in situ* lesions. Statistically significant association was not observed. There existed three groups according to size parameters. There were statistically significant differences for incomplete excision in size of lesions greater than 20 mm (27.4%), lesions between 10-20 mm (15.9%) and lesions smaller than 10 mm (5%) with P -value of 0.031. Incomplete excision rate was 9.1% for a positive personal history of childhood radiotherapy for tinea capitis and 19.2% for negative one. This was not statistically significant. There was a significant difference (0.044) in the rate of incomplete excision among grafting (29.9%), flapping (13.3%) and direct closure (16%) (Table2). Percentages of incomplete excision among general anesthesia, sedation (with local anesthesia), spinal block and local anesthesia were 26.4%, 16.1%, 8.3% and 0% respectively. These differences were not statistically significant.

Table 1. Percentage of incomplete excision by sex

Sex	Free	Involved	Total
male	174(84.9%)	31(15.1%)	205(100%)
female	35(72.9%)	13(27.1%)	48(100%)
total	209(82.6%)	44(17.4%)	253(100%)

Pearson Chi-Square test($P=0.049$)

Type of closure	Free	Involved	Total
graft	47(70.1%)	20(29.9%)	67(100%)
flap	131(86.7%)	20(13.3%)	151(100%)
direct closure	42(84%)	8(16%)	50(100%)
unknown	5(100%)	0(100%)	5(100%)
total	225(82.4%)	48(17.6%)	273(100%)

Pearson Chi-Square test ($P=0.044$)

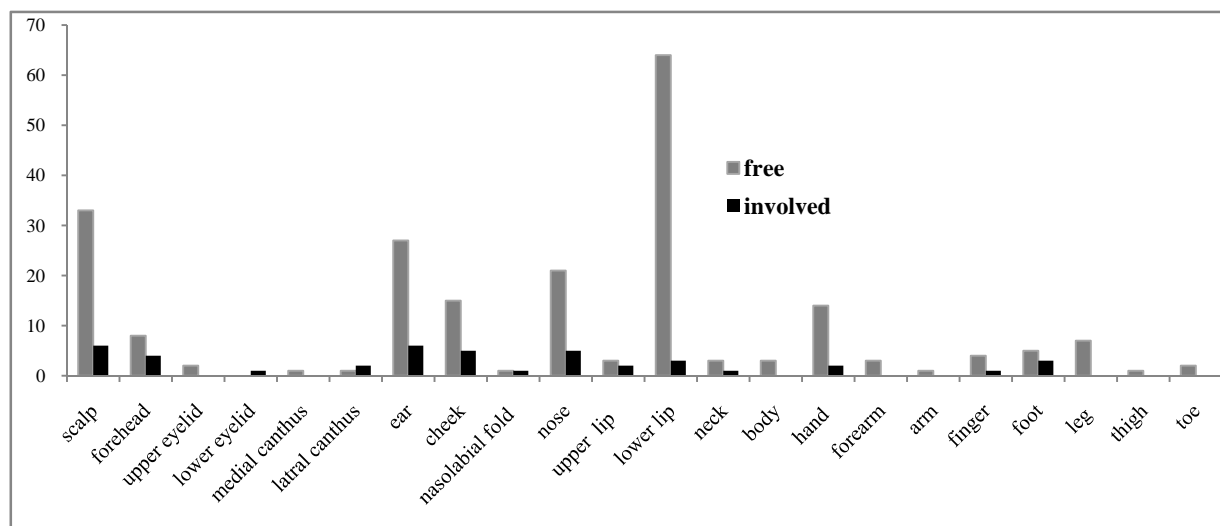


Figure 2. Frequency of incomplete excision by location of tumor

Discussion

The aims of all treatments are directed against a non-melanoma skin cancer removal or destruction of the primary tumor mass and in the case of SCCs, the prevention of metastasis. Among a broad range of therapeutic options, surgery is the modality of choice (7). In excising SCC, the surgical margin that is wide enough to completely remove the tumor and narrow enough to minimize removal of excessive normal tissue must be selected (8). Comprehensive knowledge of the risk factors related with incomplete excision of SCCs was the aim of our study. Incidence of incomplete excision was 17.58% which was more than other data published with a range of 5.8-15.9% (1-3). Deep margin was involved in 73% of them. Vertical invasion depth and involvement of subcutaneous fat is a very important factor as there is greater risk of metastasis (9-16). The mean age of two groups (patients with completely and incompletely excised lesions) was nearly similar like other studies (1-3). We found gender as a significant variable contrary to other studies (1,2). In Ang *et al.*, study, being male was associated with incomplete excision but this rate was 27.1% for women and 15.1% for men in our study (3). This might be a reflection of cosmetic problems which is more considered in women. Incomplete excision were significantly associated with the location of tumors in the lateral canthus, upper lip, foot, forehead, cheek, neck, nose and ears that is nearly similar to 2. Bogdanov-Berezovsky *et al.*, study (2). Ang *et al.* stated that tumors located on the genital and lower limbs were associated with a high risk of having an

incomplete excision (3). The rate of incomplete excision was 37.5% for foot tumors in our study which was high and might be related to difficulty with surgical closure. In Tan *et al.*, study lesions on the ear were associated with a high incomplete excision rate (1). Degree of cell differentiation was not a statistically significant factor for incomplete excision like Bogdanov-Berezovsky *et al.*, study although there are studies that imply low differentiated tumors require a larger margin for complete removal (2,8,11). Larger lesions were associated with a higher rate of incomplete excision similar to Ang *et al.*, study but tumor size was not a statistically significant risk factor in other series (1-3). SCCs larger than 20 mm in diameter are at a greater risk of metastasis (9-13).

Radiotherapy used to be a treatment modality for tinea capitis and it is one of the most important risk factors for non-melanoma skin cancers (17). It was not a statistically significant risk factor for incomplete excision. Incomplete excision rate was higher in lesions repaired by grafting (19.6%). This might be due to repairing complex lesions by this method. Grafting had the highest percentage of incomplete excision in Tan *et al.*, study but it was not statistically significant (1). We did not find the type of anesthesia a statistically significant factor for incomplete excision like Tan *et al.*, study although general anesthesia had the highest rate of incomplete excision in both studies (1). In conclusion, more care should be taken for high risk SCCs and considering complete excision versus conservative narrow margins prevents the potential risk of recurrence and metastasis range from 5.7% to 8.1% and 5% to 47%

respectively. Thus, complete excision is the goal of surgery and re-excision is recommended for all patients with incompletely excised SCCs (3,4,11,12,18-20). In this study gender, location and size of tumors and the method of repair were the statistically significant variables associated with incomplete excision.

References

1. Tan PY, Ek E, Su S, Giorlando F, Dieu T. Incomplete excision of squamous cell carcinoma of the skin: a prospective observational study. *Plast Reconstr Surg* 2007;120(4):910-6.
2. Bogdanov-Berezovsky A, Cohen AD, Glesinger R, Cagnano E, Rosenberg L. Risk factors for incomplete excision of squamous cell carcinomas. *J Dermatolog Treat* 2005;16(5-6):341-4.
3. Ang P, Tan AW, Goh CL. Comparison of completely versus incompletely excised cutaneous squamous cell carcinomas. *Ann Acad Med Singapore* 2004;33(1):68-70.
4. Talbot S, Hitchcock B. Incomplete primary excision of cutaneous basal and squamous cell carcinomas in the Bay of Plenty. *N Z Med J* 2004;117(1192):U848.
5. Chiller K, Passaro D, McCalmont T, Vin-Christian K. Efficacy of curettage before excision in clearing surgical margins of nonmelanoma skin cancer. *Arch Dermatol* 2000;136(11):1327-32.
6. Thomas DJ, King AR, Peat BG. Excision margins for nonmelanotic skin cancer. *Plast Reconstr Surg* 2003;112(1):57-63.
7. Burns T, Breathnach S, Cox N, Griffiths C, editors. *Rook's Textbook of Dermatology*. 8th ed. Oxford, UK: Wiley-Blackwell; 2008. p. 52.
8. Huang CC, Boyce SM. Surgical margins of excision for basal cell carcinoma and squamous cell carcinoma. *Semin Cutan Med Surg* 2004;23(3):167-73.
9. Johnson TM, Rowe DE, Nelson BR, Swanson NA. Squamous cell carcinoma of the skin (excluding lip and oral mucosa). *J Am Acad Dermatol* 1992;26(3 Pt 2):467-84.
10. Dinehart SM, Pollack SV. Metastases from squamous cell carcinoma of the skin and lip. An analysis of twenty-seven cases. *J Am Acad Dermatol* 1989;21(2 Pt 1):241-8.
11. Rowe DE, Carroll RJ, Day CL Jr. Prognostic factors for local recurrence, metastasis, and survival rates in squamous cell carcinoma of the skin, ear, and lip. Implications for treatment modality selection. *J Am Acad Dermatol* 1992;26(6):976-90.
12. Brodland DG, Zitelli JA. Surgical margins for excision of primary cutaneous squamous cell carcinoma. *J Am Acad Dermatol* 1992;27(2 Pt 1):241-8.
13. Kraus DH, Carew JF, Harrison LB. Regional lymph node metastasis from cutaneous squamous cell carcinoma. *Arch Otolaryngol Head Neck Surg* 1998;124(5):582-7.
14. Friedman HI, Cooper PH, Wanebo HJ. Prognostic and therapeutic use of microstaging of cutaneous squamous cell carcinoma of the trunk and extremities. *Cancer* 1985;56(5):1099-105.
15. Petter G, Haustein UF. Histologic subtyping and malignancy assessment of cutaneous squamous cell carcinoma. *Dermatol Surg* 2000;26(6):521-30.
16. Cherpelis BS, Marcusen C, Lang PG. Prognostic factors for metastasis in squamous cell carcinoma of the skin. *Dermatol Surg* 2002;28(3):268-73.
17. Lichter MD, Karagas MR, Mott LA, Spencer SK, Stukel TA, Greenberg ER. Therapeutic ionizing radiation and the incidence of basal cell carcinoma and squamous cell carcinoma. The New Hampshire Skin Cancer Study Group. *Arch Dermatol* 2000;136(8):1007-11.
18. Alam M, Ratner D. Cutaneous squamous-cell carcinoma. *N Engl J Med* 2001;344(13):975-83.
19. Dieu T, Macleod AM. Incomplete excision of basal cell carcinomas: a retrospective audit. *ANZ J Surg* 2002;72(3):219-21.
20. Miller SJ. The National Comprehensive Cancer Network (NCCN) guidelines of care for nonmelanoma skin cancers. *Dermatol Surg* 2000;26(3):289-92.
21. Reid B. Reducing the incomplete excision of non melanotic skin cancers in Australian general practice. *Aust Fam Physician* 2000;29(3):278-81.