

# Magnetic Resonance Imaging Findings in Epileptic Children and its Relation to Clinical and Demographic Findings

Susan Amirsalari<sup>1</sup>, Amin Saburi<sup>2</sup>, Reza Hadi<sup>2</sup>, Mohammad Torkaman<sup>1</sup>,  
Fateme Beiraghdar<sup>3</sup>, Shahla Afsharpayman<sup>2</sup>, and Yasaman Ghazavi<sup>4</sup>

<sup>1</sup> Department of Pediatrics, Baqiyatallah University of Medical Sciences, Tehran, Tehran, Iran

<sup>2</sup> Health Research Center, Baqiyatallah University of Medical Sciences, Tehran, Tehran, Iran

<sup>3</sup> Nephrology & Urology Research Center, Baqiyatallah University of Medical Sciences, Tehran, Iran

<sup>4</sup> Student Research Committee, Shahid Beheshti University of Medical Sciences, Tehran, Terhan, Iran

Received: 19 Apr. 2011; Received in revised form: 2 Sep. 2011; Accepted: 27 Sep. 2011

**Abstract-** Epilepsy is an important disease with a cumulative incidence of 3% all over the life and more than half of them are started from childhood. In this study we surveyed magnetic resonance imaging (MRI) findings in epileptic children and its relation with clinical and demographic findings in order to find better diagnostic and treatment modalities for these children in the future. In this cross sectional study, we investigated consecutively all 1 to 15-year-old epileptic children who referred to the pediatric neurology outpatient clinic from 2004 to 2010. Two hundred children were enrolled for investigation. There were 85 (42.5%) girls and 115 (57.7%) boys, aged 1 to 15-year-old ( $7.7\pm 4$ ). 196 (98%) of the children had abnormal electroencephalography (EEG). Abnormal MRI was seen in 57 (28.5%) patients and consisted of brain atrophy (10%), increasing white matter signal intensity in T<sub>2</sub>-weighted images (8%), benign cysts (5%), brain tumors (4%) and vascular abnormalities (1.5%). Abnormal MRI findings had significant relation with abnormal EEG, age, positive family history for epilepsy, dysmorphic appearance, and abnormal physical exam. Considering 98% EEG abnormalities in these epileptic children, benign nature of MRI findings in most of our cases, the high price of MRI and the small minority of patients who benefit from active intervention as a result of MRI, we suggest to use EEG for confirmation of epilepsy and perform MRI for patient with abnormal physical exams, focal neurologic deficits or focal EEG abnormalities.

© 2012 Tehran University of Medical Sciences. All rights reserved.

*Acta Medica Iranica*, 2012; 50(1): 37-42.

**Keywords:** Children, Epilepsy; Electroencephalography (EEG); Magnetic resonance imaging (MRI)

## Introduction

Epileptic seizure displays the clinical manifestation of excessive, abnormal, unprovoked, synchronous discharges of neurons residing primarily in the brain cortex (1). This abnormal abrupt cerebral stimulation is intermittent and usually short-term and self-limited, continuing seconds to a few minutes. The definition of epilepsy needs the happening of at least one epileptic seizure (3). It is appraised that near to 10.5 million children less than 15 years have a form of epilepsy throughout the world, representing about quadrant of the universal epilepsy population (2). Approximately 1.12 million people develop epilepsy annually that live in developing countries (such as Iran) are younger than 15 year-old (2,3). The prevalence of pediatrics epilepsy is

reported up to 10% in the literature (4-5,9-10). A cumulative incidence of 3.6% all over the life and more than half of them are started from childhood (3,11). An individual is identified to have epilepsy when seizures reappear over a period of time without apparent reasons. Epilepsy is not a specific disease, but to confirm the diagnosis of epilepsy, other causes must be ruled that they can cause seizures such as tumors, sclerosis, acute brain injury, hemorrhage, infection and genetic channelopathies (6). Electroencephalography (EEG) and imaging are two usual ways to use for this propose. The goal of the diagnostic assessment in a patient with epilepsy is to prepare evidence that helps establish or disprove the diagnosis of epilepsy and to determine the cause of epilepsy to classify the epileptic syndrome. Majority of patients surmised of having had an epileptic

**Corresponding Author:** Amin Saburi

Health Research Center, Baqiyatallah University of Medical Sciences. Mollasadra St, Vanak Sq, Tehran, Iran  
Tel: +98 21 88600062, 912 7376851, Fax: +98 21 88600062, E-mail: aminsaburi@yahoo.com

## MRI findings in epileptic children

seizure should evaluate by a neuroimaging. The goal is to recognize a structural etiology for epilepsy. The worthwhile optional neuroimaging is magnetic resonance imaging (MRI), which is more sensitive than CT scan for most brain epileptogenic lesions (12-14). The electroencephalography (EEG) is an important and usual supplement to the investigation of children with uncertain seizures. Practically each child with repeated seizures should have an EEG awake and during sleep.

Neuroimaging specially computed tomography (CT) scan also has a critical role in the evaluation of patients with seizure for overruling the life-threatening causes. MRI is the one of best neuroimaging study for the assessment of a child with seizures. MRI is more sensitive than CT scan for identifying brain abnormality and dysplastic lesions especially in the hippocampus, a common site of seizure onset (15). The Considerable MRI abnormalities in children with epilepsy were present in 16-21% and the most frequent structural abnormality are congenital impairments, neurocutaneous syndromes, malignancy, and evidence of encephalopathy due to trauma, infection or asphyxia insult (16-18). Furthermore, all MRI abnormal findings are not related to epileptic seizures. white matter Punctuate foci of T<sub>2</sub> signal change, some cystic lesions (choroidal fissure cysts, arachnoid cysts), lacunar infarctions, diffuse atrophy, ventricular asymmetry and isolated venous anomalies (*i.e.* those not correlated with arteriovenous malformation or cavernous angioma) are not recognized to be cause of epilepsy, and must be assigned incidental to a seizure diagnosis (8).

Recent advancements in neuroimaging including structural imaging (CT and conventional MRI) and functional imaging (PET, SPECT, functional MRI) could be useful to characterize brain abnormality in epileptic children. In this study we surveyed MRI findings in epileptic children and its relation with clinical and demographic findings in order to find better diagnostic and treatment modalities for these children in the future.

## Patients and Methods

In this cross-sectional study, we investigated consecutively all 1 to 15-year-old epileptic children who referred to Baqiyatallah pediatric neurology outpatient clinic from July 2004 to July 2010. Patients with acute cerebral insult were excluded from the study. We defined Epilepsy as seizures occurring more than once among children without fever (3), in the absence of a history of head trauma (or other acute brain insults),

absence of any laboratory abnormalities or evidence of concurrent central nervous system infection. Children with previous neonatal seizure (before 28 days of life) and first seizures lasting 30 minutes or more (status epilepticus) were excluded, because these disorders are different in diagnosis and therapeutic protocol.

Hence, study team contacted the child's parents or guardians to request permission. After getting permission from the parent, the physician collected needed data. The Baqiyatallah university research ethics committee ratified the method for the study.

Demographic information and clinical data contained patient's age, gender, familial history, the presence of any underlying conditions, any dysmorphic appearance, generalized or partial type of seizure (19-20), central body temperature, neurologic symptoms and any other abnormal findings in the neurologic examination and developmental delays (according to Denver developmental screening test second edition (21). A surface EEG was performed for all of the patients and any abnormalities were annotated and sorted as epileptiform irregularities (rhythmical stir, spikes and sharp waves) or non-epileptiform irregularities (polymorphic partial or generalized slowing). Benign EEG variants were not regarded abnormal (22). The EEG was only interpreted via single pediatric neurologist after the accomplishment of the MRI where the results were blinded to the neurologist.

The MRI study was carried out on a 1.5 Tesla magnet (Siemens, Germany) within first months of the second seizure whenever possible. Imaging was done using the routine MRI epilepsy protocol with 5 mm thickness slices and 2.0 mm interslice gaps in the sagittal, coronal and axial plane with T<sub>1&2</sub>-weighting. A single radiologist with pediatrics proficiency construed MRI scans blind to medical history, physical examination, epilepsy type or any information about the patients. Demographic and clinical data were correlated with brain MRI abnormality employing Chi-square, t-test or Fisher's exact test using SPSS 16 version software (SPSS Inc, USA). *P* <0.05 was considered statistically meaningful.

## Results

Two hundred children were enrolled in this study. There were 85 (42.5%) girls and 115 (57.7%) boys, aged 1 to 15-year-old (mean ± SD: 7.7 ± 4 years). One hundred thirty one (65.5%) patients presented with focal and 69 (34.5%) with generalized seizures (Table 1). Twenty-nine (14.5%) children had abnormal findings on

neurologic examination (8% of girls versus 19% of boys with significant statistical difference) and eleven (5.5%) patients had dysmorphic appearance (1.2% of girls against 8.7% of boys with meaningful statistical difference). 77.6% of female patients and 56.5% of male patients had focal seizures and this difference was significant ( $P=0.002$ ). 49.4% of girls and 62.6% of boys had positive family history of epilepsy and this inequality was non-significant ( $P=0.06$ ). In addition, 42.7% of patients that affected with partial epilepsy had positive family history of afebrile seizures although 43.5% of generalized epileptic patients had similar history.

7.1% of female children were affected with failure to thrive (FTT) versus 20% of male children with significant difference ( $P=0.01$ ). 12.2% of focal epileptic patients concerned with delay developmental status whereas development delay was seen in more than 18.8% of children with generalized epilepsy that this difference wasn't significant. The above findings are exhibited in Table 1.

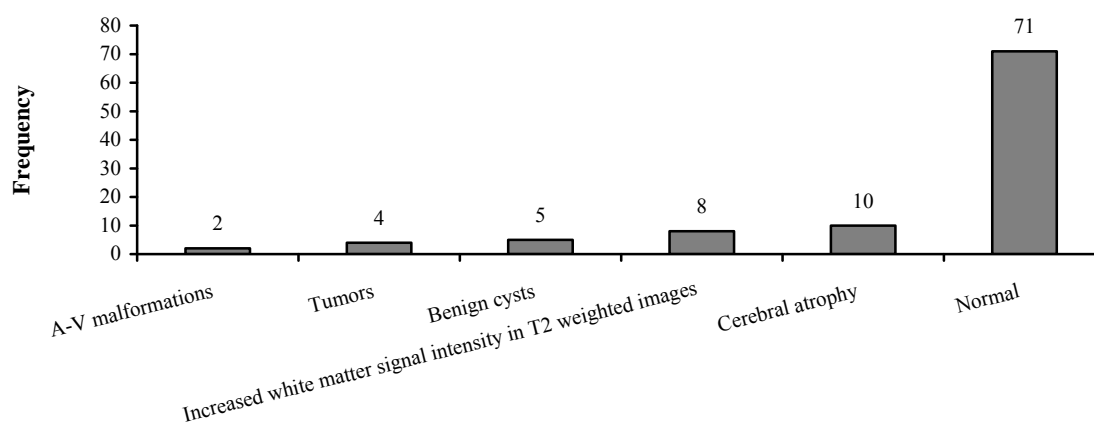
196 (98%) of the children had abnormal EEG. Therein all of girls and 96.5% of boys had abnormal EEG. Normal MRI was seen in 143 (71.3%) and abnormal MRI in 57 (28.5%) patients (with no significant difference according to gender or type of seizures). Abnormal MRI findings consisted of brain

atrophy in 20 cases (10%), increasing white matter signal intensity in T<sub>2</sub>-weighted images in 16 cases (8%), benign cysts in 10 cases (5%), brain tumors in 8 cases (4%) and vascular abnormalities in 3 cases (1.5%). Abnormal imaging findings are shown separately at lesion types in Figure 1. There are significant differences between the mean ages of patients with abnormal MRI findings against the patients with normal MRI findings ( $9.3\pm 4.2$  versus  $7.3\pm 3.8$ ).

Abnormal MRI findings were seen in 31.4% of patients with positive family history of epilepsy and 14.9% of patient without this history which the difference was meaningful. 34.5% of children with FTT had abnormal imaging report where as 19.9% of epileptic children without FTT had abnormal MRI. Furthermore, 54.5% of children with somatic dysmorphic feature and 21% of patients without it had abnormal MRI results. ( $P<0.05$ ) Abnormal imaging reports existed in 51.7% of patients with abnormal neurologic examination, while the amount of patients with normal neurologic examination equivalent to 17% ( $P=0.000$ ). Also, the mean age ( $\pm$ SD) in epileptic children with normal and abnormal MRI findings had significant difference ( $7.3\pm 3.8$  versus  $9.3\pm 4.2$ ). Of the 57 patients with abnormal neuroimaging, 8.8% (5) had underlying diseases whereas 7.7% (11) of normal imaging patient had underlying diseases ( $P=0.1$ )

**Table 1.** Clinical and para-clinical findings based on epilepsy type.

Findings	Focal epilepsy	Generalized epilepsy	P
Dysmorphic feature	8.4%	0%	0.01 (Significant)
Abnormal neurologic examination	11.5%	20%	0.09
Abnormal EEG	96.9%	100%	0.1
Abnormal MRI	21.4%	23.2%	0.7



**Figure 1.** MRI findings frequency.

### Discussion

Centers for Disease Control and Prevention of the United State (CDC) estimated prevalence of epileptic seizure base on a self-reported study about 1.1-2.2% (23). The prevalence of epilepsy was reported 1.8% in Iran which is a common neurological condition in younger group (24). Also near to 57% of patients who demonstrate with a first epileptic seizure are younger than 25 years, and most of them is 15 years or younger (25). Near to 70% of these patients are admitted and undergo various evaluations (26). MRI has been found to be efficient in the evaluation of brain structures and imaging the possible pathologies in the etiology of seizure and other abnormalities in childhood partial epilepsy. MRI is highly sensitive and noninvasive neuroimaging but it is expensive and not comfortably available. International league against epilepsy guideline imaging for children is suggested when localization-related new onset epilepsy is not known or in doubt, when the epilepsy classification is suspected, or when an epileptic syndrome with unlikely symptomatic etiology is in doubt. When available, MRI is preferred to CT because of its superior resolution, versatility, and lack of radiation (27).

Approximately half of sporadic imaging studies in children with localization-related new-onset epilepsy were announced to be abnormal; 15-20 percent of imaging studies obtained beneficial information on cause or and seizure focus, and 2-4 percent obtained information that potentially modified urgent medical management (27). On the other hand, more than 5% of scans carried out on healthy adult show incidental findings. Some investigations have informed the prevalence of abnormal neuroimaging in children with new onset epilepsy. The prevalence of abnormal neuroimaging in these investigations varied between 0-38.6 percent (16-18,29-40).

Our study reviewed 200 children with new-onset epilepsy and neuroimaging was done in 200 children and an abnormal MRI result was seen in 57 (28.5%) patients that is more than other previous studies. This difference could be abnormal MRI findings had significant relation with high age, positive family history for epilepsy, dysmorphic appearance and abnormal physical exam. There was not a significant relation with sex, type of seizures (generalize or partial), failure to thrive and underlying diseases. Sharma *et al*, (31) investigated 500 of children presented with new-onset afebrile seizures in emergency department. Neuroimaging was carried out in 475 children and they

reported the prevalence of 8%, as clinically meaningful abnormal neuroimaging report. Against of our study, the results revealed that there was a significant correlation between type of the seizure and abnormal neuroimaging findings.

Other pediatric investigations have recommended that a partial new-onset seizure is more often correlated with abnormal neuroimaging that is not concordant with our study (32,33,38,39). Khodapanahandeh and Hadizadeh (34) reported 10% of children concerning from their first afebrile seizure (not epileptic seizure) had abnormal neuroimaging findings and most of them also had abnormal neurologic examinations. In some reports, low age level had relation to frequent neuroimaging abnormalities (33,34). Mohamed *et al*, (35) reported frequency MRI abnormalities in epileptic patient more than our study (38.6% versus 28.5%). This difference may be due to the target population age differences. The prevalence of brain lesions by lesion type was similar to our study. Kalnin *et al*. (36) determine the frequency of MRI abnormalities in children with a first recognized seizure about 31%. Ventricular enlargement and leukomalacia were most common abnormalities which reported in this study that is completely different compared our results. In a same investigation, Berg *et al*. (37) studied on 488 newly diagnosed epileptic children whom 12.7% of patients demonstrated meaningful abnormalities on at least one MRI. The present study is focused on dysmorphic appearance, positive family history of epilepsy and FTT associated with higher prevalence of brain MRI abnormalities that in previous studies is not checked. In conclusion, considering 98% EEG abnormality in these epileptic children, benign nature of MRI findings in most of our cases, the high price of MRI and the small minority of patients who benefit from active intervention as a result of MRI, we suggest to use EEG for confirmation of epilepsy and perform MRI for patient with abnormal physical exams, focal neurologic deficits or focal EEG abnormalities. MRI as an effective neuroimaging is recommended for epileptic children who have evidence of positive family history for epilepsy, dysmorphic appearance, abnormal physical neural examinations and higher age. Results of our study should be verified with another large patient population or by a prospective trial study.

### Acknowledgments

The authors thank hearty parents of children who participated in this study. Also we acknowledge research

committee of Baqiyatallah University of medical sciences, Tehran, Iran.

## References

1. Wright NB. Imaging in epilepsy: a paediatric perspective. *Br J Radiol* 2001;74(883):575-89.
2. Forsgren L. Incidence and prevalence. In: Wallace SJ, Farrell K, editors. *Epilepsy in Children*. 2<sup>nd</sup> ed. London, UK: Arnold Publishers; 2004. p. 21-5.
3. Guerrini R. Epilepsy in children. *Lancet* 2006;367(9509):499-524.
4. Serdaroglu A, Ozkan S, Aydin K, Gucuyener K, Tezcan S, Aycan S. Prevalence of epilepsy in Turkish children between the ages of 0 and 16 years. *J Child Neurol* 2004;19(4):271-4.
5. Guissard G, Damry N, Dan B, David P, Sékhara T, Ziereisen F, Christophe C. Imaging in paediatric epilepsy. *Arch Pediatr* 2005;12(3):337-46.
6. Wright J, Pickard N, Whitfield A, Hakin N. A population-based study of the prevalence, clinical characteristics and effect of ethnicity in epilepsy. *Seizure* 2000;9(5):309-13.
7. Hirtz D, Ashwal S, Berg A, Bettis D, Camfield C, Camfield P, Crumrine P, Elterman R, Schneider S, Shinnar S. Practice parameter: evaluating a first nonfebrile seizure in children: report of the quality standards subcommittee of the American Academy of Neurology, The Child Neurology Society, and The American Epilepsy Society. *Neurology* 2000;55(5):616-23.
8. Vattipally VR, Bronen RA. MR imaging of epilepsy: strategies for successful interpretation. *Neuroimaging Clin N Am* 2004;14(3):349-72.
9. Topalkara K, Akyuz A, Sumer H, Bekar D, Topaktas S, Dener S. An epilepsy prevalence study performed using stratified sampling method among urban residents of Sivas. *Epilepsi* 1999;5:24-9.
10. Okan N, Okan M, Eralp O, Aytakin AH. The prevalence of neurological disorders among children in Gemlik (Turkey). *Dev Med Child Neurol* 1995;37(7):597-603.
11. Annegers JF, Hauser WA, Lee JR, Rocca WA. Incidence of acute symptomatic seizures in Rochester, Minnesota, 1935-1984. *Epilepsia* 1995;36(4):327-33.
12. Duncan JS. Imaging and epilepsy. *Brain* 1997;120(Pt 2):339-77.
13. Commission on Neuroimaging of the International League Against Epilepsy. Recommendations for neuroimaging of patients with epilepsy. *Epilepsia* 1997;38(11):1255-6.
14. Krumholz A, Wiebe S, Gronseth G, Shinnar S, Levisohn P, Ting T, Hopp J, Shafer P, Morris H, Seiden L, Barkley G, French J; Quality Standards Subcommittee of the American Academy of Neurology; American Epilepsy Society. Practice Parameter: evaluating an apparent unprovoked first seizure in adults (an evidence-based review): report of the Quality Standards Subcommittee of the American Academy of Neurology and the American Epilepsy Society. *Neurology* 2007;69(21):1996-2007.
15. Hsieh DT, Chang T, Tsuchida TN, Vezina LG, Vanderver A, Siedel J, Brown K, Berl MM, Stephens S, Zeitchick A, Gaillard WD. New-onset afebrile seizures in infants: role of neuroimaging. *Neurology* 2010;74(2):150-6.
16. Arthur TM, deGrauw TJ, Johnson CS, Perkins SM, Kalnin A, Austin JK, Dunn DW. Seizure recurrence risk following a first seizure in neurologically normal children. *Epilepsia* 2008;49(11):1950-4.
17. Berg AT, Mathern GW, Bronen RA, Fulbright RK, DiMario F, Testa FM, Levy SR. Frequency, prognosis and surgical treatment of structural abnormalities seen with magnetic resonance imaging in childhood epilepsy. *Brain* 2009;132(Pt 10):2785-97.
18. Shinnar S, O'Dell C, Mitnick R, Berg AT, Moshe SL. Neuroimaging abnormalities in children with an apparent first unprovoked seizure. *Epilepsy Res* 2001;43(3):261-9.
19. Commission on Classification and Terminology of the International League Against Epilepsy. Proposal for revised classification of epilepsies and epileptic syndromes. *Epilepsia* 1989;30(4):389-99.
20. Engel J Jr; International League Against Epilepsy (ILAE). A proposed diagnostic scheme for people with epileptic seizures and with epilepsy: report of the ILAE Task Force on Classification and Terminology. *Epilepsia* 2001;42(6):796-803.
21. Frankenburg WK, Dodds J, Archer P, Shapiro H, Bresnick B. The Denver II: a major revision and restandardization of the Denver Developmental Screening Test. *Pediatrics* 1992;89(1):91-7.
22. Sato S, Rose DF. The electroencephalogram in the evaluation of the patient with epilepsy. *Neurol Clin* 1986;4(3):509-29.
23. Centers for Disease Control and Prevention (CDC). Prevalence of epilepsy and health-related quality of life and disability among adults with epilepsy: South Carolina, 2003 and 2004. *MMWR Morb Mortal Wkly Rep* 2005;54(42):1080-2.
24. Mohammadi MR, Ghanizadeh A, Davidian H, Mohammadi M, Norouzi M. Prevalence of epilepsy and comorbidity of psychiatric disorders in Iran. *Seizure* 2006;15(7):476-82.

## MRI findings in epileptic children

25. Jallon P, Loiseau P, Loiseau J. Newly diagnosed unprovoked epileptic seizures: presentation at diagnosis in CAROLE study. *Coordination Active du Réseau Observatoire Longitudinal de l'Épilepsie. Epilepsia* 2001;42(4):464-75.
26. Armon K, Stephenson T, Gabriel V, MacFaul R, Eccleston P, Werneke U, Smith S. Determining the common medical presenting problems to an accident and emergency department. *Arch Dis Child* 2001;84(5):390-2.
27. Gaillard WD, Chiron C, Cross JH, Harvey AS, Kuzniecky R, Hertz-Pannier L, Vezina LG; ILAE, Committee for Neuroimaging, Subcommittee for Pediatric. Guidelines for imaging infants and children with recent-onset epilepsy. *Epilepsia* 2009;50(9):2147-53.
28. Illes J, Rosen AC, Huang L, Goldstein RA, Raffin TA, Swan G, Atlas SW. Ethical consideration of incidental findings on adult brain MRI in research. *Neurology* 2004;62(6):888-90.
29. Landfish N, Gieron-Korthals M, Weibley RE, Panzarino V. New onset childhood seizures. Emergency department experience. *J Fla Med Assoc* 1992;79(10):697-700.
30. Warden CR, Brownstein DR, Del Beccaro MA. Predictors of abnormal findings of computed tomography of the head in pediatric patients presenting with seizures. *Ann Emerg Med* 1997;29(4):518-23.
31. Sharma S, Riviello JJ, Harper MB, Baskin MN. The role of emergent neuroimaging in children with new-onset afebrile seizures. *Pediatrics* 2003;111(1):1-5.
32. Maytal J, Krauss JM, Novak G, Nagelberg J, Patel M. The role of brain computed tomography in evaluating children with new onset of seizures in the emergency department. *Epilepsia* 2000;41(8):950-4.
33. McAbee GN, Barasch ES, Kurfist LA. Results of computed tomography in "neurologically normal" children after initial onset of seizures. *Pediatr Neurol* 1989;5(2):102-6.
34. Khodapanahandeh F, Hadizadeh H. Neuroimaging in children with first afebrile seizures: to order or not to order? *Arch Iran Med* 2006;9(2):156-8.
35. Mohamed Y, Alias NN, Shuaib IL, Tharakan J, Abdullah J, Munawir AH, Naing NN. Referral of epileptic patients in North East Coast of West Malaysia an area with poor MRI coverage: an analysis. *Southeast Asian J Trop Med Public Health* 2006;37(6):1199-208.
36. Kalnin AJ, Fastenau PS, deGrauw TJ, Musick BS, Perkins SM, Johnson CS, Mathews VP, Egelhoff JC, Dunn DW, Austin JK. Magnetic resonance imaging findings in children with a first recognized seizure. *Pediatr Neurol* 2008;39(6):404-14.
37. Berg AT, Testa FM, Levy SR, Shinnar S. Neuroimaging in children with newly diagnosed epilepsy: A community-based study. *Pediatrics* 2000;106(3):527-32.
38. Kolk A, Beilmann A, Tomberg T, Napa A, Talvik T. Neurocognitive development of children with congenital unilateral brain lesion and epilepsy. *Brain Dev* 2001;23(2):88-96.
39. Doescher JS, deGrauw TJ, Musick BS, Dunn DW, Kalnin AJ, Egelhoff JC, Byars AW, Mathews VP, Austin JK. Magnetic resonance imaging (MRI) and electroencephalographic (EEG) findings in a cohort of normal children with newly diagnosed seizures. *J Child Neurol* 2006;21(6):491-5.
40. Hamiwka LD, Singh N, Niosi J, Wirrell EC. Diagnostic inaccuracy in children referred with "first seizure": role for a first seizure clinic. *Epilepsia* 2007;48(6):1062-6.