

Primary Angiitis of the Central Nervous System

Hossein Pourmahmoodian, Hossein Ali Ghelichnia Omrani, Mohammad Hossein Harrirchian,
Mojdeh Ghabae, Babak Zamani, and Majid Ghaffarpour

Department of Neurology, Iranian Center of Neurological Research, Imam Khomeini Hospital,
Tehran University of Medical Sciences, Tehran, Iran

Received: 20 Feb. 2011; Received in revised form: 5 Nov. 2011; Accepted: 26 Dec. 2011

Abstract- Primary angiitis of the central nervous system (PACNS) is an idiopathic disorder (vasculitis) restricted to the central nervous system (CNS). It often presents with focal neurological deficits suggesting stroke or a combination of confusion and headache. We herein report three cases with various combinations of fever, partial seizure, encephalopathy, paresis, headache and ataxia. One of them was initially treated as herpes simplex meningoencephalitis, but further investigations revealed primary angiitis. Primary angiitis of the CNS has protean manifestations and should always be considered in patients suspicious to have CNS infection or stroke, particularly who does not respond to the routine treatments. Clinical data, exclusion of differential diagnoses and typical angiography seem to be enough to justify the diagnosis in the majority of cases.

© 2012 Tehran University of Medical Sciences. All rights reserved.
Acta Medica Iranica, 2012; 50(3): 216-221.

Keywords: Vasculitis; Central nervous system; Angiography

Introduction

Primary angiitis of the central nervous system (PACNS), originally described by Cravioto and Feign in 1959, is a recurrent vasculitis confined to the CNS (central nervous system) without any systemic disease causing vasculitis. It can occur at any age but is more frequent in the fourth to sixth decades (often after 40 years of age) (1). Involvement of the small and medium-sized parenchymal and leptomeningeal arteries and veins lead to thrombotic occlusion, small cortical/subcortical petechial or lobar and rarely subarachnoid hemorrhages (2). Large vessels may occasionally be involved.

Headache with encephalopathy accompanied by symptoms of multifocal cerebral lesions is the most common presenting feature. Less commonly it presents as myelopathy, dementia, cranial neuropathy and radioculopathies including those confined to cauda equina (3, 4). The diagnosis of PACNS is still remained challenging. Recently, in most cases, typical angiography plus excluding other conditions that can mimic PACNS seems to be enough for diagnosis (5).

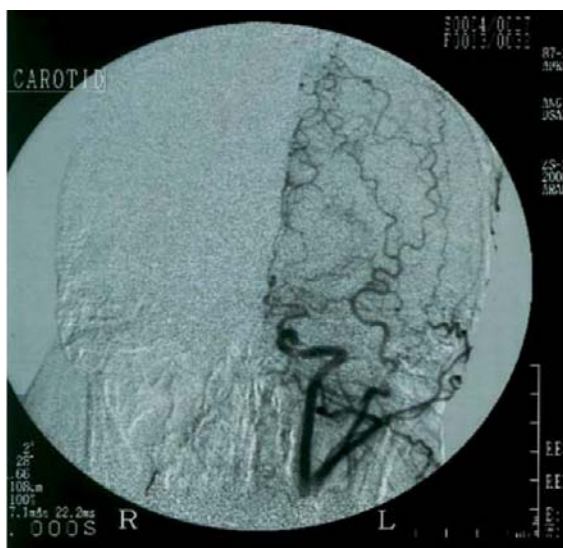
We herein report three cases, whose diagnosis were made by above mentioned trend, except one of them, in whom diagnosis achieved by wedge parenchymal and leptomeningeal biopsy.

Case 1

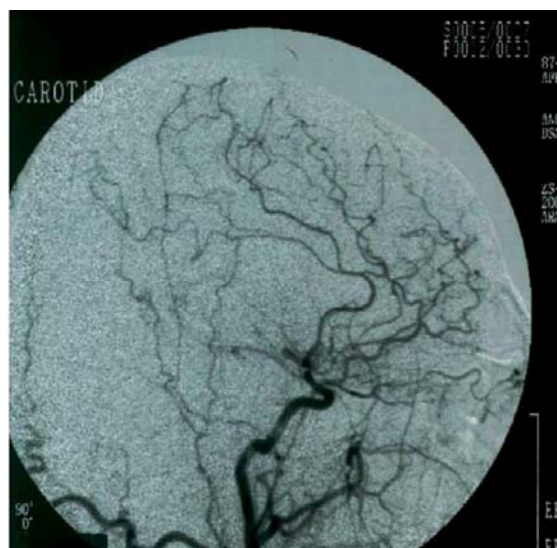Our first case was a 28 years old male whose presenting symptom was sustained and the poor treatment-responsive headache that had been begun since June 2008. He was admitted to hospital with severe diffuse headache, seizure and left hemiplegia few months later. There was no history of drug abuse. Routine laboratory evaluation, serum immunoprotein electrophoresis, cryoglobulins, coagulation studies, urine analysis, chest x-ray and echocardiography revealed no abnormality. CRP, serologic tests for HBS antigen and antibody, ANA, Anti dsDNA, ANCA (P&C), Wright, Coombs Wright, VDRL, Borrelia antibody, polymerase chain reactions for HSV type_{1,2}, VZV, *Treponema pallidum* and CMV were negative. The CSF revealed only 6 lymphocytes/m³, protein 82 mg/dl, IgG 3.4 mg/dl and IgG index 0.4. Glucose ratio and thyroid function tests were normal, and there was no OCB. Cerebral angiography reported changes compatible with vasculitis including occlusion of the left MCA (Figures 1_A, 1_B). The patient's relatives did not accept brain biopsy. High dose steroid therapy resulted in dramatic recovery. He developed right hemiparesis after 6 months; thus, cyclophosphamide was added, but in spite of combined regimen, he progressed to vegetative state and showed partial recovery during 6 month follow-up.

Corresponding Author: Hossein Pourmahmoodian.

Department of Neurology, Iranian Center of Neurological Research, Imam Khomeini Hospital, Tehran University of Medical Sciences, Tehran, Iran
Tel: +98 21 61192424, 912 1042411, Fax: +98 21 66581558, E-mail: Pourmahmoodian@yahoo.com



1_A



1_B

Figures 1_A, 1_B (Case 1). Left internal carotid artery injection: Occlusion of left MCA is seen from origin. Anterior cerebral artery is unremarkable

Case 2

A 16 year-old girl was admitted to emergency service of our center with fever, encephalopathy and left-sided motor seizures. She previously had received acyclovir on the assumption of herpes simplex meningoencephalitis one week before admission; that was stopped because of rising of creatinine and non-confirmative brain MRI after 6 days.

Neurological examination disclosed dysphasia, agitation, confusion and left-side motor seizures. Brain MRI showed lesions with central low T₁, peripheral high T₁ intensity and increased T₂ signal intensity in the anterior aspect of both thalami, suggesting malacia with subacute hemorrhage (Figures 2_{A,B,C}).

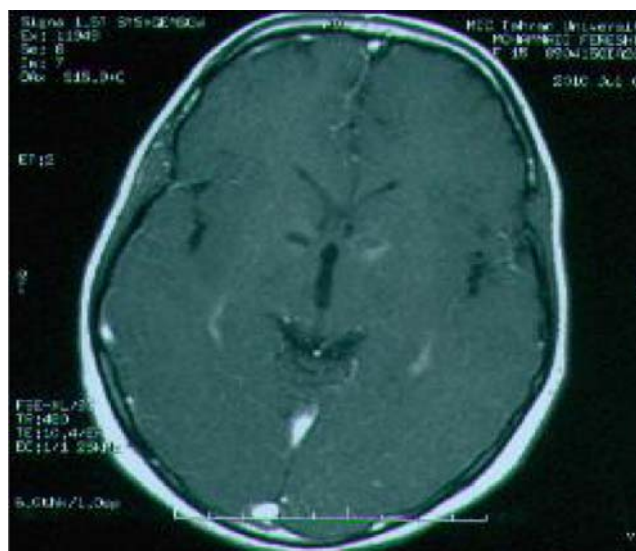


Figure 2_A (Case 2). T1/W, lacunar infarction located in the anterior aspect of the right thalamus and subacute hemorrhage in the anterior aspect of the left thalamus.

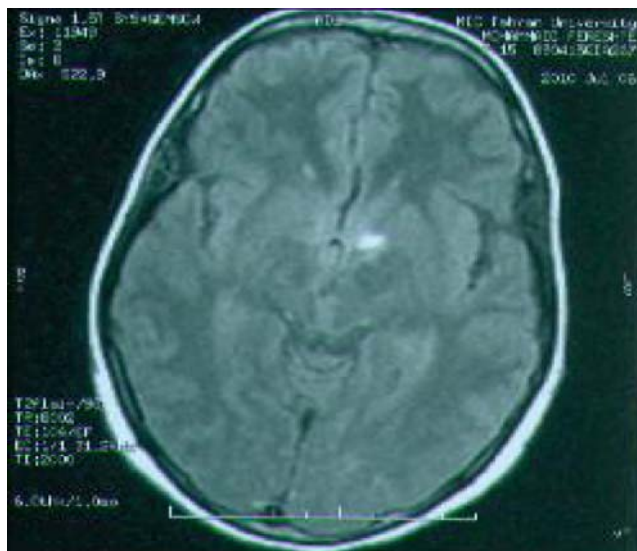


Figure 2_B (Case 2). Axial PD/W, Bright focus in the anterior portion of the left thalamus.

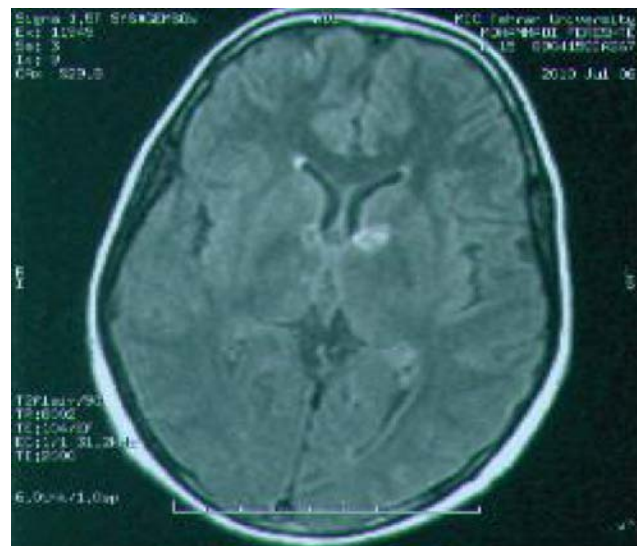


Figure 2_C (Case 2). Axial FLAIR, Bilateral bright signals located in the anterior aspect of the thalami.

The follow-up MRI showed more white matter hyperintensities with enhancement. All investigations for exclusion of other possible involving causes were negative or unremarkable, except for CSF that revealed only 2 PMN cells/ m³ and protein 174 m/dl. EEG showed bilateral dysrhythmic slowing with asymmetric epileptiform discharges. MR-angiography showed multiple stenosis with sausage appearance. We did not perform biopsy because her father did not allow it. Pulse therapy with methyl prednisolone was administered, followed by oral prednisolone 1mg/kg, that resulted in improvement within 7 days and seizures stopped.

Case 3

A 38 years old female experienced initially depression and fatigue in early 2009. She developed right lower limb weakness and then left hemiparesis a few months later. Neurological examination revealed dysarthria, ataxia and quadriparesis. Brain MRI showed diffuse brain atrophic changes in supratentorial structures and brainstem. There were also bilateral periventricular/subcortical foci of T1 low intensity and T2 high intensity lesions, some of which enhanced with Gd-PTPA T1/W.

Angiography was negative. Right frontal pole wedge and leptomenigeal biopsy confirmed the diagnosis (Infiltration of lymphocytes, giant multinucleated cells and necrosis without polymorphonuclear or eosinophils). The patient improved rapidly with corticosteroid therapy but remained with nystagmus, ataxia and paretic gait.

Discussion

In addition to cases reported herein, we reviewed approximately 70 reported cases. PACNS is a rare disorder with an estimated incidence of 1:2000, 000 (6). Headache was reported to be the most common symptom (7). Encephalopathy accompanied by headache and multifocal symptoms is the most common presentation (8). Focal weakness at least in one of the limbs, myelopathy with relapsing – remitting course and seizures occur in 50%, 15% and 10% of cases respectively (8,9).

An atypical multiple sclerosis and intracranial mass with surrounding edema (15%) are uncommon presentations. Necrotic unihemispheric presentation mimicking Rasmussen's encephalitis (10), cauda equina syndrome (11), subarachnoid hemorrhage (12), posterior leukoencephalopathy with visual disturbances (13) and recurrent aseptic meningitis are also reported.

CT and MRI may disclose infarction and relatively large lobar but not cortical/subcortical petechial hemorrhages. Their sensitivities are 30 and 80% respectively. MRI usually reveals multiple bilateral supratentorial high intensity lesions on T2-weighted sequences and rarely is normal. Disseminated, non-periventricular T2-hypersignals in white matter can indicate PACNS and may be helpful in differentiation from MS. Unilateral supratentorial multifocal lesions are more frequent in children (14). Linear and punctuate leptomenigeal enhancements are seen in up to 60% of patients. Pulvinar sign was also reported (15). Gradient-echo MRI is a useful tool in detection of cortical/subcortical petechial hemorrhages that reveals areas of signal loss due to chronic blood products such as hemosiderin (16,17).

Standard angiography (SA) is increasingly replaced by MRA and CT angiography; however, the sensitivity of the latter procedures is lower than SA. Some authors regarded SA as a gold standard for evaluation of suspected patients. The characteristic findings in angiography are multifocal stenosis (beading or sausage – like appearance) with ectasia and occasionally arterial occlusions. This procedure alone can not exclude or

confirm the diagnosis, because 30-45% false negative rate has been reported (18).

If angiography is negative, brain biopsy may be contemplated. Positive biopsy achieves only in 50-70% of cases. This process carries 0.5-2% risk of mortality; therefore it should be reserved for patients in whom clinical findings, MRI and MRA are non-conclusive. Others (19) claimed that early biopsy should be discussed in all suspicious cases.

Histologically defined angiitis of CNS (HDACNS) with a fulminant or progressive course and steroid-resistant cases are treated by the combination of steroid and cyclophosphamide (the latter is preferably replaced by azathioprine or methotrexate after 3-6 months), whereas for angiographically defined cases (ADACNS) and for patients with a unique focal manifestation such as stroke steroid and calcium channel blockers are advised.

Calabrese LH, Mallek JA (1988) and Moore (1998) proposed following criteria for diagnosis of the PACNS: 1) Exclusion of systemic infectious and inflammatory diseases and 2) Positive biopsy (20). Recently, in most instances and depending on the clinical feature, the diagnosis is made by either positive.

Biopsy or high-suggesting angiogram in addition to excluding all differential diagnosis including Wegener's and lymphoid granulomatosis, other mimicking conditions such as secondary CNS vasculitis occurring in collagen vascular disorders, viral or bacterial infections, malignancies (Hair cell leukemia, neoplastic meningioma, malignant histiocytosis, Hodgkin and non-Hodgkin's lymphoma), treatments (Radiation, Transplantation), drug abuse (crack, cocaine, amphetamine), atrial myxoma, atrium and cholesterol-derived emboli and other vasculitis stimulators (Table 1).

Table 1. Vasculitis simulators.

-	Angiocentric lymphoproliferative disease
-	Angioendotheliomatosis
-	Anticardiolipin antibody syndrome
-	Arterial fibromuscular dysplasia
-	Atherosclerosis
-	Cardiac myxoma , cholesterol embolism syndrome
-	Moyamoya
-	Radiation
-	Sickle cell anemia , small vessel disease
-	Transplantation , TTP
-	Vasospasm including acute or malignant hypertension

Primary angiitis of CNS

Table 2. Associated/predisposing conditions for vasoconstriction.

- 1- Early puerperium / late pregnancy.
- 2- Eclampsia / preeclampsia / delayed postpartum eclampsia.
- 3- Exposure to drugs and blood products
Phenylpropanolamine, Pseudoephedrine, Ergotamine, Tartrate, Methysergine, Bromocryptine, Lisuride, SSRI, Sumatriptan, Isometheptine, Cocaine, Ecstasy, Marijuana, Amphetamines, Tacrolimus, Cyclophosphamide, Erythropoetin, IVIG, Red blood cell transfusion.
- 4- Miscellaneous
Hypercalcemia, Porphyria, Pheochromocytoma, Bronchial carcinoid, Unruptured cerebral aneurysm, Head trauma/ neurosurgical procedures, Spinal subdural haematoma, Post carotid endarterectomy.
- 5- Idiopathic

Abeta-related angiitis (ABRA) that occurs occasionally in patients with cerebral amyloid angiopathy is another differential diagnosis, however, its mean age of onset is usually higher (often >65 years) and presents in most of cases with unusual features such as behavior and cognitive derangements (21).

Angiopathic changes, suggesting vasculitis have occasionally been reported in neurosarcoidosis and CADASIL (22).

Reversible cerebral vasoconstriction syndrome (Call-Fleming syndrome) should always be considered in interpretation of angiographic feature of PACNS. Associated/ predisposing conditions for vasoconstriction (Table 2), thunderclap headache, spontaneous resolving within weeks or months and rapid improvement under calcium channel blockers characterize this syndrome (23).

In two of our cases, diagnosis was made by exclusion of other causes and angiography. Acceptable response to steroids supported our diagnosis so we agree some authors' opinion that biopsy should be reserved for patients in whom other investigations including MRI and angiography fail to interpret and explain clinical findings. In conclusion, PACNS should be considered in CNS lesions specially when no ordinary or common causes of CNS involvement are found or adequate response does not achieve by proposed treatment.

References

1. Moore PM, Richardson B. Neurology of the vasculitides and connective tissue diseases. *J Neurol Neurosurg Psychiatry* 1998;65(1):10-22.

2. Lie. JT. Primary (granulomatous) angiitis of the central nervous system: a clinicopathologic analysis of 15 new cases and a review of the literature. *Hum Pathol* 1992;23(2):164-71.
3. Siva A. Vasculitis of the nervous system. *J Neurol* 2001;248(6):451-68.
4. Ilhan A, Budak F. Primary Angiitis of the Central Nervous System: Unusual Clinical Presentation. *Int J Angiol* 2000;9(1):23-6.
5. Abu-Shakra M, Khraishi M, Grosman H, Lewtas J, Cividino A, Keystone EC. Primary angiitis of the CNS diagnosed by angiography. *Q J Med* 1994;87(6):351-8.
6. Moore PM. Central nervous system vasculitis. *Curr Opin Neurol* 1998;11(3):241-6.
7. Hankey GJ. Isolated angiitis/angiopathy of the central nervous system. *Cerebrovasc Dis* 1991;1:2-15.
8. Vollmer TL, Guarnaccia J, Harrington W, Pacia SV, Petroff OA. Idiopathic granulomatous angiitis of the central nervous system. Diagnostic challenges. *Arch Neurol* 1993;50(9):925-30.
9. Bhibhatbhan A, Katz NR, Hudon M, Clark AW, Hurlbert RJ, Zochodne DW. Primary angiitis of the spinal cord presenting as a conus mass: long-term remission. *Surg Neurol* 2006;66(6):622-5; discussion 625-6.
10. Derry C, Dale RC, Thom M, Miller DH, Giovannoni G. Unihemispheric cerebral vasculitis mimicking Rasmussen's encephalitis. *Neurology* 2002;58(2):327-8.
11. Rehman HU. Primary angiitis of the central nervous system. *J R Soc Med* 2000;93(11):586-8.
12. Kumar R, Wijdicks EF, Brown RD Jr, Parisi JE, Hammond CA. Isolated angiitis of the CNS presenting as subarachnoid haemorrhage. *J Neurol Neurosurg Psychiatry* 1997;62(6):649-51.
13. Wijdicks EF, Manno EM, Fulgham JR, Giannini C. Cerebral angiitis mimicking posterior leukoencephalopathy. *J Neurol* 2003;250(4):444-8.
14. Aviv RI, Benseler SM, Silverman ED, Tyrrell PN, Deveber G, Tsang LM, Armstrong D. MR imaging and angiography of primary CNS vasculitis of childhood. *AJNR Am J Neuroradiol* 2006;27(1):192-9.
15. Collie DA, Summers DM, Sellar RJ, Ironside JW, Cooper S, Zeidler M, Knight R, Will RG. Diagnosing variant Creutzfeldt-Jakob disease with the pulvinar sign: MR imaging findings in 86 neuropathologically confirmed cases. *AJNR Am J Neuroradiol* 2003;24(8):1560-9.
16. Schmidley JW. Isolated CNS angiitis: pathology. In: Schmidley JW, editor. *Central Nervous System Angiitis*. Woburn: Butterworth-Heinemann; 2000. p. 1-28.

17. Fazekas F, Kleinert R, Roob G, Kleinert G, Kapeller P, Schmidt R, Hartung HP. Histopathologic analysis of foci of signal loss on gradient-echo T2*-weighted MR images in patients with spontaneous intracerebral hemorrhage: evidence of microangiopathy-related microbleeds. *AJNR Am J Neuroradiol* 1999;20(4):637-42.
18. Vollmer TL, Guarnaccia J, Harrington W, Pacia SV, Petroff OA. Idiopathic granulomatous angiitis of the central nervous system. Diagnostic challenges. *Arch Neurol* 1993;50(9):925-30.
19. Kadkhodayan Y, Alreshaid A, Moran CJ, Cross DT 3rd, Powers WJ, Derdeyn CP. Primary angiitis of the central nervous system at conventional angiography. *Radiology* 2004;233(3):878-82.
20. Calabrese LH, Mallek JA. Primary angiitis of the central nervous system. Report of 8 new cases, review of the literature, and proposal for diagnostic criteria. *Medicine (Baltimore)* 1988;67(1):20-39.
21. Scolding NJ, Joseph F, Kirby PA, Mazanti I, Gray F, Mikol J, Ellison D, Hilton DA, Williams TL, MacKenzie JM, Xuereb JH, Love S. Abeta-related angiitis: primary angiitis of the central nervous system associated with cerebral amyloid angiopathy. *Brain* 2005;128(Pt 3):500-15.
22. Schmidley JW, Beadle BA, Trigg L. Co-occurrence of CADASIL and isolated CNS angiitis. *Cerebrovasc Dis* 2005;19(5):352-4.
23. Ducros A, Boukobza M, Porcher R, Sarov M, Valade D, Bousser MG. The clinical and radiological spectrum of reversible cerebral vasoconstriction syndrome. A prospective series of 67 patients. *Brain* 2007;130(Pt 12):3091-101.