

# Clinical Characteristics and Remedies in 45 Iranians with Carotid Body Tumors

Iraj Nazari<sup>1</sup>, Fatemeh Aarabi Moghaddam<sup>2</sup>, Mohammad Mahdi Zamani<sup>2</sup>, and Javad Salimi<sup>1</sup>

<sup>1</sup> Department of Vascular Surgery, Sina Trauma and Surgery Research Center, Sina Hospital, Tehran University of Medical Sciences, Tehran, Iran

<sup>2</sup> Research Center, School of Medicine, Tehran University of Medical Sciences, Tehran, Iran

Received: 1 May 2011; Received in revised form: 10 Oct. 2011 ; Accepted: 17 Jan. 2012

**Abstract-** Carotid body tumors (CBTs) are rare, slow-growing tumors that should be considered in evaluating every lateral neck mass. This single center study was performed to define demographic features, clinical characteristics and remedies of Iranian patients with CBT. A retrospective review of prospectively collected data was done on 45 patients with 50 CBTs who have been referred to Sina Hospital, Tehran, Iran, during a 10-year period, were investigated in this study. The demographic characteristics, clinical and pathologic features, imagings, preoperative treatments, surgical approach and complications were analyzed. The study group predominantly consisted of females (82%). Age of diagnosis was 18 to 75 years old. Five patients had bilateral CBT. Family history of CBT was positive in seven patients. Most of CBTs were  $\leq 3$ cm in size. All of the patients presented with a neck mass, mostly without pain (84%). Other symptoms included vertigo 4%, dysphasia 4% and tinnitus 2%. There was no patient with cranial nerve involvement at presentation. The most common imaging helping the diagnosis was color Doppler sonography. Three patients had preoperative embolization. All patients underwent surgery and seven patients had post-operative cranial nerve injury. Nine cases underwent external carotid artery ligation and four ones had external carotid repair. Post operative mortality rate was one patient. This study provides epidemiological data on patients with CBT in Iran, which could be useful for health care workers in prompt diagnosis and appropriate work ups for patient's families in bilateral CBTs.

© 2012 Tehran University of Medical Sciences. All rights reserved.

*Acta Medica Iranica*, 2012; 50(5): 339-343.

**Keywords:** Carotid body tumor; Paraganglioma, extra adrenal; Iran

## Introduction

Carotid body tumors (CBTs) are uncommon and slow-growing tumors usually located at the bifurcation of the common carotid artery, which was first described by Von Haller in 1743. They arise from neural crest cells associated with the autonomic ganglia (1). They are mostly asymptomatic, presenting with a painless neck mass, and other symptoms are due to local mechanical compression of the vascular, muscular (2) and neural structures around. The carotid body works as a chemoreceptor organ stimulated by hypoxia (3-4), hypercapnia, and acidosis (2) also mutations are recognized as a cause (5), but its main etiology is unknown yet. Approximately 1 out of 30000 tumors of the head and neck region correspond to a paraganglioma, of which the most frequent site is the carotid body (65%) (6). Other paragangliomas located in the head and neck region are

the jugular, vagal, nasal, orbital, laryngeal, and tympanic tumors (3).

There are three distinct types of CBT: familial, sporadic and hyperplastic forms. Hyperplastic type is very common in patients of COPD, patients of congenital cyanotic heart disease and in the areas which are more than 1500 meters (about 5000 feet) above the sea level like the New Mexico, Peru and Colorado (7).

Different data are introduced in the literature in different countries. Even in Iran, a few studies have been done to show the distribution and features of this tumor (8-9). Because of the low incidence of this tumor, a remarkable number of patients in Sina Hospital, and few published data from the country, Iran, this study was performed to define demographic features, clinical characteristics and remedies of Iranian patients with CBT during a 10-years period in a referral hospital.

**Corresponding Author:** Javad Salimi

Vascular and Endovascular Surgery Ward, 4<sup>th</sup> Floor, Sina Hospital, Imam Khomeini St., Tehran, Iran, P.O. Box 11367-46911  
Tel/Fax: +98 21 66348564, E-mail: mjsalimi@tums.ac.ir

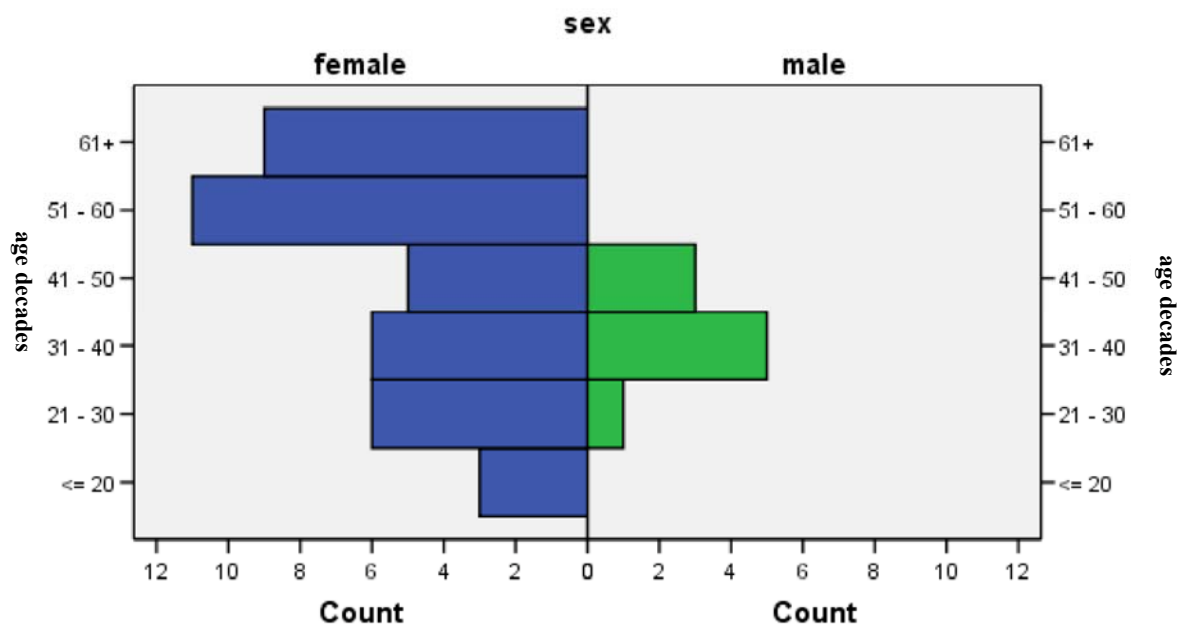


Figure 1. Age-gender distribution of patients with CBTs

## Patients and Methods

### Subjects

Forty-five patients with 50 diagnosed carotid body tumors in the range of 18-75 years old were investigated in this study (from April 1<sup>st</sup> 1999 to April 1<sup>st</sup> 2009). All the patients were referred to the Sina Hospital, Tehran, Iran, one of the main referral centers of vascular surgery diseases in Tehran-Iran. The data were gathered by interviewing the patients as well as reviewing their medical records. For all subjects, a complete history was taken. Medical documents were reviewed; Physical examinations were performed and necessary pathologic and imaging studies were conducted. Post-operative complications were gathered, as well. Age groups were divided into six categories as shown in figure 1. For the size, we divided tumors into three groups; group one (G.1):  $\leq 3$  cm, group two (G.2):  $3 < \text{to} < 5$  cm, group three (G.3):  $\geq 5$ cm. Regarding high altitude as a cause of CBT, the living place altitudes of the subjects were divided into two groups: equal or lower than 1500 meters (m) above sea level, higher than 1500 m above sea level.

The study was approved by the regional ethics committee of Hospital. Inform consent was obtained from each patient.

### Follow up

Forty two numbers of the subjects were followed up by a questionnaire included:

Reversibility of nerve injuries which have occurred during the surgical procedures, post-operative complications containing dysphasia, aphonia, dysphonia or any hoarseness or changing of voice, slow - growing mass on the same side or the other side of the neck, new onset mass in other family members and cerebrovascular attacks.

### Statistical analysis

Data analysis was analyzed by statistical package of social sciences (SPSS), version 16.0 (SPSS Inc, Chicago, IL). P-value of less than 0.05 was considered significant.

## Results

The study group consisted of 45 patients with 50 CBTs through which five patients had bilateral CBT. There were 37 females (82%) aging from 51 to 60 and 8 males (18%) aging 31-40 years old. Mean age of all patients was 44 years, ranging from 18 to 75. The ratio of male to female was 1:4.6. Seven ones (15%), who were all females, had bilateral CBT. Seven patients (15%) had a positive family history of CBT, three ones had unilateral and four ones had bilateral CBT. One patient with bilateral CBT had no family history of it. Twenty-nine patients lived at a place with an altitude of higher than 1500 m above the sea level (64%), and 16 ones lived at equal or less than 1500 m (36%).

The most common cause for seeking medical attention was a slow-growing cervical mass (100%). Forty two cases of CBTs (84%) were without pain, and eight ones (16%) had pain. Other symptoms included vertigo 4%, dysphasia 4% and tinnitus 2%. There was no patient with cranial nerve involvement or neuroendocrine symptoms at presentation. Thirty-two (64%) CBTs were pulsatile, and 24 cases (48%) had bruit on auscultation. Together with bruit, only 10 patients with CBTs (20%) had pulse in physical examination. Mean size of the tumor was 4.36 cm, 24 (48%) of CBTs were in G.1, 16 (32%) were in G.2 and 10 (20%) sized in G.3. Twenty-six CBTs were right sided and 24 on the left. The most common imaging helping the diagnosis was color Doppler sonography which was performed in 36 patients (80%). For 26 patients computed tomography (CT) (57%), for 11(24%) angiography and for one (2%) magnetic resonance imaging (MRI) were done. Eight patients had CT + angiography, 21 ones Doppler+CT and four ones had Doppler+CT+ angiography and Doppler+angiography was done for eight patients.

Three patients had preoperative embolization. All the 45 patients (with 50 CBTs) underwent surgery from which, seven patients had post-operative cranial nerve injury. In nine operations, external carotid artery ligation was done (18%), four ones had external carotid repair (8%). Through the 13 operations with external carotid injury, six ones were in G.3, five in G.2 and two in G.1 which showed Significant size dependency of carotid artery injury ( $P \leq 0.05$ ). Internal carotid repair was done for three patients (6%), from which, two were in G.3 and one in G.1. Post-operative difference between size and internal carotid repair requirement was not significant

( $P > 0.05$ ). Mortality rate was two percent, who was a 32 years old man with a 10 cm of tumor size, involving hypoglossal nerve and internal and external carotid arteries with adhesion to the surrounding tissue. Preoperative embolization was done for him. After the surgery, he was discharged from intensive care unit (ICU) one day after the operation to the ward with sympathetic and 12<sup>th</sup> cranial nerve injury and GCS of 15/15. In the third day of admission in the ward, he had CVA symptoms and was proved by CT as bilateral brain ischemia, which necessitated intubation and re-admission in ICU, after a week, the patient was expired.

Preoperative embolization and excision significantly had more mortality (one from three patients) compare with excision alone (zero from 42 patients) ( $P < 0.05$ )

In the follow up for a mean time of 40 months (range: 3-112 months) in 42 patients, from the seven patients with post-operative cranial nerve injuries, two patients had reversible and one patient had irreversible 12<sup>th</sup> nerve injury, and there was one patient suffering from irreversible vagus nerve injury (Table 1). One patient was referred with recurrence of the tumor and another one with a new CBT growing on the other side of the neck, one 70 years old female was referred with metastasis to regional lymph node after six years of the CBT being resected and two patients who were sisters and one of them had glomus jugular tumor simultaneously by CBT, reported their third sister having a new onset CBT.

In a 46 years old woman, in addition to CBT, small irregularity was detected in right thyroid lobe (same side with CBT) and frozen section of thyroid lobectomy, revealed papillary thyroid carcinoma.

**Table 1.** Post-operative cranial and sympathetic nerve injuries according to carotid body tumor size.

		Size					
		≤3 cm		3.1-5 cm		>5 cm	
		No* of patients	Percent (%)	No* of patients	percent	No* of patients	Percent (%)
Injury to nerve 12	Yes	1	33.3	0	0	2	66.7
	No	23	48.9	15	31.9	9	19.1
Injury to nerve 10	Yes	1	25	0	0	3	75
	No	23	50	15	32.6	8	17.4
Injury to sympathetic	Yes	0	0	0	0	1	100
	No	24	49	15	30.6	10	20.4

\* Number

## Discussion

Like other paragangliomas, CBT originates from cells which develop from neural crest. CBT is a non functioning tumor, but sometimes histamine, serotonin, epinephrine and norepinephrine secreting ones are seen, as well (7). Differential diagnoses include brachial cyst, node metastases, salivary gland tumors, carotid artery aneurysm and neurofibromas.

One of the largest series to-date is reported by Hallett *et al.*, in 1988 with 153 tumors through 50 years, approximately three cases per year (10) compared to the present study which has about five cases per year.

Recent studies have reported that CBTs are more common in females rather than males (1.9:1) (1). But, there are some Asian centers reporting their data vice versa (11,12). In a study from Shiraz, Iran, CBT was more common in females than males (8); similarly, in another study performed in Tehran, Iran, the female to male ratio was 2:1 (9). Similarly, in this study, gender dominancy was with women: the ratio of male to female was 1:4.6. As shown in the results, carotid body tumors generally present as a painless, rubber-like consistency, slowly enlarging mass, with limited mobility in the vertical direction and mobile in the lateral plane when physically explored (Fontaine sign) (13). Sometimes they are mistaken by other neck tumors and FNA is done for more evaluation. Thus, general practitioners (GP) and family physicians should pay more attention to this sign. If there is no feedback from the vascular surgeon to the GP, the diagnostic process for other patients could be delayed as it is a rare tumor through neck masses. Chronic exposure to hypoxia which is more common in high altitude regions (5000 feet), is responsible for the higher incidence of hyperplastic CBT in these patients (7,14). In Iran, which is dominantly low altitude, 64 percent of patients with CBTs lived at an altitude of higher than 1500 m above the sea level.

In other studies bilaterality is more common in familial cases even more than the latest studies and maybe it is a genotype leading of CBT etiology by genetic investigations in Persians.

Familial type mainly involved younger patients, to the results with a mean age of 26 years old ( $P<0.05$ ).

A multicenter review of CBT management also concluded that color Doppler sonography is considered the primary diagnostic investigation, as mentioned in the results (80%), but angiography and CT or MRI are helpful for planning surgery (7) of course in Ma *et al.*, study in 2010, digital subtraction angiography (DSA) was reported as the gold standard for the diagnosis of

CBTs and they emphasized on color Doppler Sonography beside digital subtraction angiography (DSA) as a very important diagnostic test in confirmation of the clinical diagnosis of CBTs (15), but further studies are needed for DSA confirmation as the first-line of CBT diagnosis. So at this time CT and Doppler sonography are enough for diagnosis confirmation of CBTs.

In large tumors, although the role of embolization is not appreciated completely, it is recommended to be used in addition to angiography. Instead of embolization, it is easier to investigate vascular pattern by using multi-slice CT angiography, which is a non-invasive method.

Eighty five percent of the brain's blood supply comes from the internal carotid arteries, therefore, ligation or removal of the carotid system may result in cerebral ischemia, edema or death. Through the 13 operations with external carotid injury, six ones were in G.3, five in G.2 and two in G.1 which showed the size dependency of carotid artery injury ( $P\leq 0.05$ ). The need for internal carotid repair was for three ones, from which, two were in G.3 and one in G.1. In the recent years, by developments in vascular surgery, peri-operative monitoring and good preoperative evaluation, mortality rate has reduced to 0.6% (16) and even near zero (11), in the current study, it was two percent (one patient).

Vogel *et al.*, by a retrospective study on 2117 patients reported no difference in mortality rate, between preoperative embolization and excision comparison with excision alone, but we had one patient (2% mortality rate) which was included in patients who took preoperative embolization (17), that patient' CBT was included in G.3, with bilateral brain ischemia after four days from surgery.

Cranial nerve palsies still remain one of the major complications of surgical CBT removal, which can occur in 10-40% of cases (18,19), similar to the very study's operation outcome which is 14%.

In our study, thyroid malignancy was detected in one patient (2%) and we did not diagnose any malignancy in CBT tissue, but in literature malignancy in CBT was reported 0% to 10% (6,20) and maybe this results suggested environmental effects on CBT malignancy occurrence and in another study of Iran 3.1% malignancy were reported (9), totally. In this environment malignancy rate is low and prospective studies are needed for discover these risk factors.

The present study provides epidemiologic data regarding the characteristics of a group of patients with

CBT in a tertiary center in Iran. Constructing a population-based registry in the region could be suggested in order to provide better epidemiologic data on these diseases in Iran. We hope that, the clinical and epidemiological experience we possess forms a basis for future RCTs on early diagnosis of family positive CBTs by emphasis on the intervals of imaging in healthy family members.

## Acknowledgement

This research has been supported by Sina Trauma and Surgery Research Center, Tehran University of medical science, grant no. 108.

## References

1. Krupski WC. Uncommon disorders affecting the carotid arteries. In: Rutherford RB, editor. *Vascular surgery*. Vol 2. 6<sup>th</sup> ed. Philadelphia, PA: Elsevier Saunders; 2005.
2. Ozay B, Kurc E, Orhan G, Yucel O, Senay S, Tasdemir M, Gorur A, Aka SA. Surgery of carotid body tumour: 14 cases in 7 years. *Acta Chir Belg* 2008;108(1):107-11.
3. Saldana MJ, Salem LE, Travezan R. High altitude hypoxia and chemodectomas. *Hum Pathol* 1973;4(2):251-63.
4. Grufferman S, Gillman MW, Pasternak LR, Peterson CL, Young WG Jr. Familial carotid body tumors: case report and epidemiologic review. *Cancer* 1980;46(9):2116-22.
5. Rodríguez-Cuevas S, López-Garza J, Labastida-Almendaro S. Carotid body tumors in inhabitants of altitudes higher than 2000 meters above sea level. *Head Neck* 1998;20(5):374-8.
6. Luna-Ortiz K, Rascon-Ortiz M, Villavicencio-Valencia V, Granados-García M, Herrera-Gomez A. Carotid body tumors: review of a 20-year experience. *Oral Oncol* 2005;41(1):56-61.
7. Sajid MS, Hamilton G, Baker DM; Joint Vascular Research Group. A multicenter review of carotid body tumour management. *Eur J Vasc Endovasc Surg* 2007;34(2):127-30.
8. Atefi S, Nikeghbalian S, Yarmohammadi H, Assadi-Sabet A. Surgical management of carotid body tumours: a 24-year surgical experience. *ANZ J Surg* 2006;76(4):214-7.
9. Salehian MT, Ghoddoosi I, Marashi A. Carotid body tumor: survey of 97 patients. *Arch Iran Med* 2002;5(1):1.
10. Hallett JW Jr, Nora JD, Hollier LH, Cherry KJ Jr, Pairolero PC. Trends in neurovascular complications of surgical management for carotid body and cervical paragangliomas: a fifty-year experience with 153 tumors. *J Vasc Surg* 1988;7(2):284-91.
11. Tayyab M, Khan MR, Sophie Z. Presentation and management of carotid body tumors. *J Pak Med Assoc* 2003;53(7):306-10.
12. Arun D, Edwin S, David S, Sunil A. Surgical management of carotid body tumors: A 15-year review. *Indian J Surg* 2006;68(5):257-61.
13. Leonetti JP, Donzelli JJ, Littooy FN, Farrell BP. Perioperative strategies in the management of carotid body tumors. *Otolaryngol Head Neck Surg* 1997;117(1):111-5.
14. Knight TT Jr, Gonzalez JA, Rary JM, Rush DS. Current concepts for the surgical management of carotid body tumor. *Am J Surg* 2006;191(1):104-10.
15. Ma D, Liu M, Yang H, Ma X, Zhang C. Diagnosis and surgical treatment of carotid body tumor: A report of 18 cases. *J Cardiovasc Dis Res* 2010;1(3):122-4.
16. Williams MD, Phillips MJ, Nelson WR, Rainer WG. Carotid body tumor. *Arch Surg* 1992;127(8):963-7; discussion 967-8.
17. Vogel TR, Mousa AY, Dombrovskiy VY, Haser PB, Graham AM. Carotid body tumor surgery: management and outcomes in the nation. *Vasc Endovascular Surg* 2009;43(5):457-61.
18. Westerband A, Hunter GC, Cintora I, Coulthard SW, Hinni ML, Gentile AT, Devine J, Mills JL. Current trends in the detection and management of carotid body tumors. *J Vasc Surg* 1998;28(1):84-92; discussion 92-3.
19. Koskas F, Vignes S, Khalil I, Koskas I, Dziekiewicz M, Elmkies F, Lamas G, Kieffer E. Carotid chemodectomas: long-term results of subadventitial resection with deliberate external carotid resection. *Ann Vasc Surg* 2009;23(1):67-75.
20. Zhang WC, Cheng JP, Li Q, Zhang L, Wang XD, Anniko M. Clinical and pathological analysis of malignant carotid body tumour: a report of nine cases. *Acta Otolaryngol* 2009;129(11):1320-5.