

Late Sequelae of Hip Septic Arthritis in Children

Taghi Baghdadi¹, Sadegh Saberi¹, Amir Sobhani Eraghi¹,

Aidin Arabzadeh¹, and Shirin Mardookhpour²

¹ Department of Orthopedic Surgery, Imam Khomeini Hospital, Tehran University of Medical Sciences, Tehran, Iran

² Department of Radiology, Imam Khomeini Hospital, Tehran University of Medical Sciences, Tehran, Iran

Received: 20 Nov. 2011; Received in revised form: 25 Mar. 2012; Accepted: 23 May 2012

Abstract- Septic arthritis of the hip in children has multiple sequelae and may result in severe disability. Significant morbidity can be prevented by early recognition and treatment. The authors reviewed 13 children with 14 hips with sequelae of septic arthritis of the hip. All of children had history of hip septic arthritis before age of 4 years. Six were male subjects, and 7 were female subjects. We evaluated the history, clinical findings and radiographs of all children who had been treated at the Imam Khomeini hospital between 1986 and 2001 for septic arthritis of the hip. Final results of operations in patients include range of motion, presence or absence pain, joint stability, limb-length discrepancy were assessed. Three hips had mild pain in usual daily activities and one patient with cerebral palsy experienced hip instability. Most of patients (80%) had flexion contracture about 10-15 degrees. Final results showed average limb length discrepancy was about 2.8 cm. Septic arthritis of the hip in children may result in a spectrum of residual problems and the significant complications can be averted by early detection and treatment. Treatment in younger age cause better outcome.

© 2012 Tehran University of Medical Sciences. All rights reserved.

Acta Medica Iranica, 2012; 50(7): 463-467.

Keywords: Hip septic arthritis; Sequelae; Operative reconstruction

Introduction

Delay of the diagnosis and treatment of septic arthritis of the hip (SAH) may result in a spectrum of pathologic changes. This is especially true in the newborn, who may have no constitutional signs of infection. Laboratory studies and radiographs of the hip may also remain unrevealing. The sequelae of septic arthritis of the hip in an infant are diverse and include premature closure of the triradiate cartilage, acetabular dysplasia, limb length discrepancy, premature or asymmetrical closure of the proximal femur physis, subluxation, dislocation, necrosis of the cartilage, ischemic necrosis of the femoral head, pseudoarthrosis of the femoral neck and complete destruction of the femoral head and neck (1-6). The purpose of this study was to review our experience with treatment of the late sequelae of septic arthritis of the hip in infants and we present a series of patients with sequelae of SAH.

Materials and Methods

We retrospectively reviewed the medical records, clinical examinations and radiographs of all patients who had been treated at the Imam Khomeini hospital between 1986 and 2001 for SAH. Most patients in this study were treated at other medical centers at the acute phase and were referred to our hospital to treat complications. The diagnosis was made with typical history of SAH and characteristic signs of the sequelae. We classified the hips using the Choi *et al.* classification (Figure 1) (7-9).

Children with history of developed septic arthritis before age of 4 years were included in this study. We excluded all patients with minimal sequelae (type 1 by Choi *et al.* classification). Final outcome of patients include range of motion, presence or absence pain, joint stability, limb-length discrepancy were evaluated.

Corresponding Authors:

Sadegh Saberi and Amir Sobhani Eraghi

Department of Orthopedic Surgery, Imam Khomeini Hospital, Tehran University of Medical sciences, Tehran, Iran

Tel: +98 21 61192767, +98 912 5035148, E-mail: s_saberi@tums.ac.ir or amir_sobhany@yahoo.com

Results

14 hips in 13 patients (one patient, bilateral) met the criteria to be included in this study. There were 6 boys and 7 girls. The right side was involved in 6 patients; the left side in 8. The average age at the last visit was 12 years (range, 4-20 years). The average length of follow-up of the sequelae was 3.7 years (range, 1-14 years). The average length of follow-up from the first surgery for the treatment of the sequelae was 8.3 years (range, 1-18

years). Except cases No 2, 6 and 8 that given infection after two years old, in other patient's age of infection onset was in infancy. Charectistics of the patients are presented in Table 1.

In 3 of patients (No.4, 7 and 10) in addition to hip, other joints involvement was seen. 2 of cases suffered from cerebral palsy (CP) and one of them suffered from juvenile rheumatoid arthritis. Until last follow up every patient operated averagely 2 times (1-5).

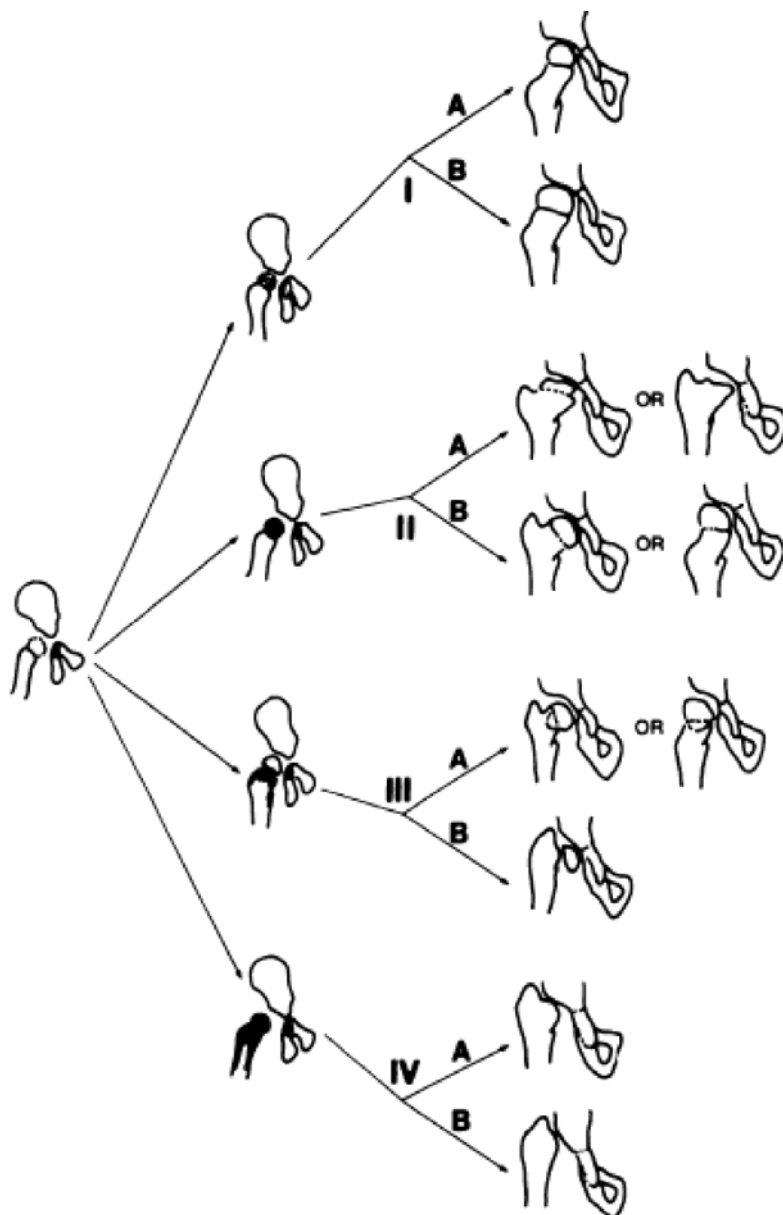


Figure 1. Classification of sequelae. Type I: no residual deformity (Type IA) or mild coxa magna (Type IB). Type II: Coxa breva with a deformed head (Type IIA) or progressive coxa vara or valga due to asymmetrical, pre-mature physeal closure (Type IIB). Type III: Slipping at the femoral neck, resulting in coxa vara or valga with severe anteversion or retroversion (Type IIIA) or pseudarthrosis of the femoral neck (Type IIIB). Type IV: destruction of the femoral head and neck, with small medial remnant of the neck (Type IVA) or complete loss of the femoral head and neck and no articulation of the hip (Type IVB).

Table 1. Charectistics of study population.

Case Number	Gender	Age of Operation (years)	Times of Operation	Other site involvement	Backgroun d Problem	Infective germ
1	M	2.5	1	-	-	Gram negative
2	F	17	1	Femur Osteomyelitis	-	Staph. aureus
3	F	17.5	3	-	-	-
4	F	10	1	Shoulder arthritis	-	-
5	F	8	1	-	JRA	Staph. aureus
6	M	18	1	-	-	Staph. aureus
7	M	1	1	Shoulder and knee arthritis	-	Staph. aureus
8	F	7	3	-	-	Staph. aureus
9	M	7	1	-	-	Gram negative
10	F	6	2	Knee arthritis	-	Staph. aureus
11	M	4	3	-	Spastic CP	Staph. aureus
12	F	9	2	-	-	-
13	M	1	5	-	-	-

CP: Cerebral Palsy, JRA: Juvenile idiopathic arthritis, Staph. aureus: Staphylococcus aureus

Table 2. Outcome of hip septic arthritis evaluated for the long term clinical course.

Case number	Radiologic classification	Pain or no?	Stability of joint	Operation method	ROM		
					Flexion	Abductin	Int. Rotation
1	4A	No	Stable	Salter OT	0-120	40	30
2	4A	No	Stable	Valgus subtrochantric OT	10-90	10	10
3	4A	No	Stable	Distal greater trochantric Advancement Femoral lengthening	10-100	10	5
4	2A	No	Stable	Distal greater trochantric Advancement	0-100	25	15
5	-	No	Stable	Adductor tenotomy and CR with skeletal traction	15-85	15	5
6	-	No	Stable	Arthrodesis	-	-	-
7	4A	No	Stable	Harman Op..	10-100	15	0
8	-	No	Stable	Valgus subtrochantric OT	-	-	-
9	4A	Mild	Stable	Harman Op.	15-90	15	5
10	4A	Mild	Stable	Greater trochantric arthroplasty	10-80	0	10
11	4A	-	Unstable	Harman Op. Distal greater trochantric Advancement Valgus subtrochantric OT	20-90	30	10
12	2A	-	Stable	Open reduction Shelf Op.	100	20	10
13	4A	mild	Stable	Greater trochantric Arthroplasty Shelf Op. Varus subtrochantricOT Epiphysiodesis	90	15	10

OT: Osteotomy , OP: Operation

Late sequelae of hip septic arthritis

Of the 10 patients who suffered from septic arthritis in infancy, 8 had sequel grade 4 and 2 had grade 2 (based on Hunka classification). It shows that patients who had grade 4 sequelae suffered from more problems and refer to hospital. *Pain after operation:* In usual daily activities only 3 patients had mild pain; however, in heavy exercises the pain and fatigue were inevitable. *Stability of hip:* Except the patient No.11 that suffered from mild CP, other patients had stable hip in the last visit. *Hip Range of Motion:* Most of patients (80%) had flexion contracture about 10-15 degrees (average flexion was 90 degrees). Average abduction was 15-20 degrees. The main problem in ROM was in rotational motions that limited in most patients. *Limb length discrepancy:* Except the case No. 5, there was average limb length discrepancy about 2.8 cm (1-5 cm). Of 9 patients that infective germ was detected, 7 infected with *Staphylococcus aureus* and 2 infected with gram negative germs. Final outcome of patients are presented in Table 2.

Discussion

The diagnosis of septic arthritis of the hip is readily made in a toddler or older child due to the typical presentation but especially in newborns may be difficult. Several prognostic factors have been consistently associated with a poor result after septic arthritis of the hip and the occurrence of the sequelae (1-5,10-12). These factors have included delay in diagnosis and treatment, age at onset of infection, premature birth, virulence of the organism, and association with osteomyelitis. Most of the authors agree that a delay of 4 days or more increases the chance of bad prognosis and it is the most important single factor contributing to a poor result (1-3,12). Sequelae may diverge from very subtle alteration to severe damage of the proximal femur and dislocation of the joint. Complications of septic arthritis of the hip include: premature closure of the triradiate cartilage, acetabular dysplasia, limb-length discrepancy, premature or asymmetrical closure of the proximal femoral physis, subluxation, dislocation, necrosis of the cartilage, ischemic necrosis of the femoral head, pseudarthrosis of the femoral neck, complete destruction of the femoral head and neck, early osteoarthritis and loss of motion (5,7-9). Given this spectrum of pathology, treatment recommendations must be individualized. In newborns and infants that are treated with delay, long term use of Pavlik harness prevents soft tissue contracture and improves acetabular development. Therefore, subsequent reconstructive

procedures make easier. Most of patients in the study were included in group 4 Choi *et al.* classification. Better results have been observed when treatment performs in younger age. Accordingly both patient and surgeon acquire better consequences. Leg-length discrepancy should be expected in all patients with lesion of the proximal epiphysis. Leg-length discrepancy may be significant, and contributing factors include subluxation or dislocation, arrest of the upper femoral physis, and malpositioning of the extremity due to soft tissue contracture and/or bony malalignment. In the stable hips, the discrepancy varies from 2 to 5 cm, and for the unstable hips, it reaches up to 14 cm (3-5,9-12). In our series, the maximum discrepancy in the centered hip (with or without reconstruction) was 6 cm at the last follow-up. The choice of treatment method will depend on the both the current discrepancy and the anticipated discrepancy at skeletal maturity. Epiphysiodesis should be considered for anticipated discrepancies between 2.5 and 5 centimeters. Limb lengthening is indicated for anticipated discrepancies in excess of 5-6 centimeters. In painful degenerative joints, arthrodesis and total joint replacement are options (5-7,12). Arthrodesis provides excellent relief of pain, but may confine function and activities of daily living. Total joint replacement is an option in older adolescents. In Type IIIb there is a pseudarthrosis of the femoral neck, and the recommended treatment is valgus osteotomy with bone grafting. Valgus subtrochantric osteotomy improves health conditions in ankylosed hips. Pelvic osteotomy (Salter or Pemberton) enhance containment and joint stability (5,7-9,13).

Abductor insufficiency apparent as an abductor lurch, a positive Trendelenburg sign, and aching discomfort following prolonged ambulation. Greater trochanter may be transferred either distally, laterally, or both and recover abductor function (5, 9-12).

The effective management of sequelae of septic hip arthritis in children still remains a challenging goal for the orthopedic community. Principles of treatment of musculoskeletal infections in children involve prevention, accurate diagnosis, and prompt intervention (including antibiotic therapy and surgical debridement). Close follow-up is mandatory to ensure a good long-term outcome (14).

References

1. Bennett OM, Namnyak SS. Acute septic arthritis of the hip joint in infancy and childhood. Clin Orthop Relat Res 1992;(281):123-32.

2. Kaplan SL. Challenges in the evaluation and management of bone and joint infections and the role of new antibiotics for gram positive infections. *Adv Exp Med Biol* 2009;634:111-20.
3. Grill F, Rustler T. Late sequelae of coxitis in infants. *Orthopade* 1997;26(10):848-57.
4. Dobbs MB, Sheridan JJ, Gordon JE, Corley CL, Szymanski DA, Schoenecker PL. Septic arthritis of the hip in infancy: long-term follow-up. *J Pediatr Orthop* 2003;23(2):162-8.
5. Spiegel DA, Penny JN, Banskota AK, Shrestha OP. Sequelae of Septic Arthritis of The Hip. A Global-HELP Publication. [Internet] 2007 [cited 2012 May 15]; Available from: http://www.global-help.org/publications/books/help_hipsepticarthritis.pdf
6. Peters W, Irving J, Letts M. Long-term effects of neonatal bone and joint infection on adjacent growth plates. *J Pediatr Orthop* 1992;12(6):806-10.
7. Choi IH, Shin YW, Chung CY, Cho TJ, Yoo WJ, Lee DY. Surgical treatment of the severe sequelae of infantile septic arthritis of the hip. *Clin Orthop Relat Res* 2005;(434):102-9.
8. Choi IH, Yoo WJ, Cho TJ, Chung CY. Operative reconstruction for septic arthritis of the hip. *Orthop Clin North Am* 2006;37(2):173-83, vi.
9. Choi IH, Pizzutillo PD, Bowen JR, Dragann R, Malhis T. Sequelae and reconstruction after septic arthritis of the hip in infants. *J Bone Joint Surg Am* 1990;72(8):1150-65.
10. Manzotti A, Rovetta L, Pullen C, Catagni MA. Treatment of the late sequelae of septic arthritis of the hip. *Clin Orthop Relat Res* 2003;(410):203-12.
11. Wang EB, Ji SJ, Zhao Q, Zhang LJ. Treatment of severe sequelae of infantile hip sepsis with trochanteric arthroplasty. *J Pediatr Orthop* 2007;27(2):165-70.
12. Forlin E, Milani C. Sequelae of septic arthritis of the hip in children: a new classification and a review of 41 hips. *J Pediatr Orthop* 2008;28(5):524-8.
13. Kim YH, Oh SH, Kim JS. Total hip arthroplasty in adult patients who had childhood infection of the hip. *J Bone Joint Surg Am* 2003;85-A(2):198-204.
14. McCarthy JJ, Dormans JP, Kozin SH, Pizzutillo PD. Musculoskeletal infections in children: basic treatment principles and recent advancements. *Instr Course Lect* 2005;54:515-28.