

## Effect of Topical Application of Silymarin (*Silybum marianum*) on Excision Wound Healing in Albino Rats

Roya Sharifi<sup>1</sup>, Hossein Rastegar<sup>2</sup>, Mohammad Kamalinejad<sup>3</sup>, Ahmad Reza Dehpour<sup>4</sup>, Seyed Mohammad Tavangar<sup>1</sup>, Maliheh Paknejad<sup>1</sup>, Mahboobeh Mehrabani Natanzi<sup>1</sup>, Naghmeh Ghannadian<sup>6</sup>, Minoo Akbari<sup>2</sup>, and Parvin Pasalar<sup>1,7</sup>

<sup>1</sup> Department of Biochemistry, School of Medicine, Tehran University of Medical Sciences, Tehran, Iran

<sup>2</sup> Food and Drug Control Laboratory and Research Center, Ministry of Health and Medical Education, Tehran, Iran

<sup>3</sup> Department of Pharmacognosy, Faculty of Pharmacy, Shahid Beheshti University of Medical Sciences, Tehran, Iran

<sup>4</sup> Department of Pharmacology, Tehran University of Medical Sciences, Tehran, Iran

<sup>5</sup> Department of Pathology, Shariati Hospital, Tehran University of Medical Sciences, Tehran, Iran

<sup>6</sup> Students' Scientific Research Center, Tehran University of Medical Sciences, Tehran, Iran

<sup>7</sup> Center for Research on Occupational diseases, Tehran University of Medical Sciences, Tehran, Iran

Received: 15 Apr. 2012; Received in revised form: 28 Jun. 2012; Accepted: 4 Aug. 2012

**Abstract-** Silymarin, an extract from *Silybum marianum*, has been shown to have antioxidant properties. However, there is no scientific report on wound healing activity of the silymarin. The purpose of this study was to evaluate the effect of topical administration of silymarin on excision wound healing in rats. Excision wounds were made on the back of rats. Rats were divided into three groups, as control, vehicle, and treatment. Vehicle and treatment groups received polyethylene glycol and silymarin dissolved in polyethylene glycol, respectively. The control group did not receive any treatment. The wound tissues were removed on 5th, 10th and 15th day for histopathological analysis and total collagen determination by hydroxyproline assay. Results showed that silymarin increased epithelialization and decreased inflammation but did not have any effect on percentage of wound contraction, collagenization and hydroxyproline levels. It was concluded that silymarin can significantly stimulate epithelialization and reduce inflammation in full-thickness wounds in rats.

© 2012 Tehran University of Medical Sciences. All rights reserved.

*Acta Medica Iranica*, 2012; 50(9): 583-588.

**Keywords:** Epithelialization; Excision wound; Silymarin; Wound healing

### Introduction

Wound healing is a complex process that involves a variety of processes such as inflammation, proliferation, and remodeling. The process of wound healing is essential to prevent the invasion of damaged tissue by pathogens and to reform the damaged tissue (1).

Reactive oxygen species (ROS) that are produced in response to cutaneous injury may impair the healing process. Several antioxidants have been reported to quench oxidative damage to tissue. In fact, the use of antioxidants has been suggested as an effective strategy for therapeutic approaches in wound healing (2,3). Flavonoids, the main component of plant extract, act as a powerful antioxidant and free radical scavenger (4-6).

Silymarin, a flavonoid obtained from *Silybum marianum* (*L.*) *Gaertn.* (milk thistle plant), has been used for centuries to treat liver, spleen and gallbladder

disorders (7). Silymarin possesses strong antioxidant, anti-inflammatory and anticancer activities (8-12), and also modulates many molecular changes caused by xenobiotics and ultraviolet radiation to protect the skin (9,11,13-16). Although silymarin and its components were demonstrated to have significant activity on UV-irradiated skin and be effective against burn-induced oxidative damage in rat skin, there is no information about its effect on wound healing. In this study, we investigated the effect of silymarin on excision wound healing in rat.

### Materials and Methods

#### Experimental model

This study was performed on male Wistar albino rats weighing 150–200 g. Rats were housed in individual cages in the animal laboratory. They were maintained in

**Corresponding Author:** Parvin Pasalar

Department of Biochemistry, School of medicine, Tehran University of Medical Sciences, 1417613151, Tehran, Iran  
Tel/Fax: +98 21 88953004, E-mail: pasalar@tums.ac.ir

## Effect of topical application of silymarin

a 12 h light, 12 h dark cycle at room temperature ( $25\pm 3^{\circ}\text{C}$ ) and were fed a standard rat chow for 1 week to be acclimatized prior to the investigation. All procedures were carried out with prior approval from the animals committee of Tehran University of Medical Sciences.

The animals were anaesthetized with intraperitoneal injection of 12.5 mg/kg xylazine hydrochloride (Alfasan, Woerden, Holland) and 125 mg/kg ketamine hydrochloride (Alfasan, Woerden, Holland). Their backs were shaved and cleaned with 70% ethanol. A 500 mm<sup>2</sup> full-thickness excision was made on the back of each rat and the day on which the wound was made considered as day 0 (17). A total of 45 rats were randomly divided into three groups of equal number (control, vehicle and treatment groups). Control group did not receive any treatment (n=15). Silymarin (Sigma-Aldrich, Germany) was prepared by dissolving 60 mg silymarin in 2g polyethylene glycol. Rats in treatment group received 30 mg/kg silymarin on wound area once daily. Rats in vehicle group (n=15) were treated with equal volume of polyethylene glycol topically, once daily. On days 5, 10 and 15, five animals in each group were randomly selected and sacrificed with the same anesthetic solution. The wounds were excised together with the surrounding skin and dissected into two parts, half for histopathological analysis and the other half for hydroxyproline level determination.

### Histopathological evaluation

Tissue samples for histopathological analysis were separately fixed in 10% formalin, dehydrated through graded alcohol series, cleared in xylene and embedded in paraffin wax. Serial sections of 5  $\mu\text{m}$  were prepared, and stained with hematoxylin and eosin (H&E) for routine histopathological evaluation. Masson's trichrome stain was used to determine degree of collagenization. All slides were examined in a blinded manner by surgical pathologist. Inflammation and collagen deposition were graded as: 0 (none), 1 (scant), 2 (moderate), and 3 (abundant). Epithelization was graded as either: 0 (none), 1 (partial), 2 (complete, but immature or thin), and 3 (complete and mature) (17).

### Hydroxyproline measurement

Hydroxyproline levels were determined spectrophotometrically by Woessner's method (18). Weighed tissue samples were first hydrolyzed in 6 N HCl for 18 h at  $115^{\circ}\text{C}$ , evaporated to dryness and then made up with a known volume of water. One ml of sample was incubate with 0.5 ml of 0.05 M chloramine T solution (0.14 g chloramines T, 2 ml distilled water, and 8 ml citrate acetate buffer) for 20 min at room

temperature. Then 1 ml of Erlich's solution (2.5 g p-dimethylbenzaldehyde, 2.7 ml HCl, and 16 ml n-propanol) was added and the sample was incubated for 15 min at  $60^{\circ}\text{C}$ . Absorbance was measured at 550 nm with spectrophotometer. Hydroxyproline concentrations of the unknown samples were calculated from a linear standard curve and were presented as  $\mu\text{g}/\text{mg}$  protein.

### Rate of wound contraction

The largest and smallest diameters of the wounds were measured using a caliper (Vernier caliper, Mitutoyo, Japan) and the area (s) was calculated as  $s = \pi ab$ , where a and b correspond to one-half of the largest and one-half of the smallest diameter, respectively. Measurements were done directly on the animals, by the same examiner. The percentage reduction in wound size on days 5, 10, 15 was calculated by the following formula (19). % of wound contraction = ((initial wound size-specific day wound size)/ initial wound size)  $\times$  100

### Statistical analysis

All data are expressed as mean  $\pm$  SEM. Percentage of wound contraction and hydroxyproline level data were compared with one-way ANOVA, while histological data were analyzed with Kruskal-Wallis multivariate analysis followed by Mann-Whitney U test (non-parametric methods). Values of  $P < 0.05$  were considered as significant.

## Results

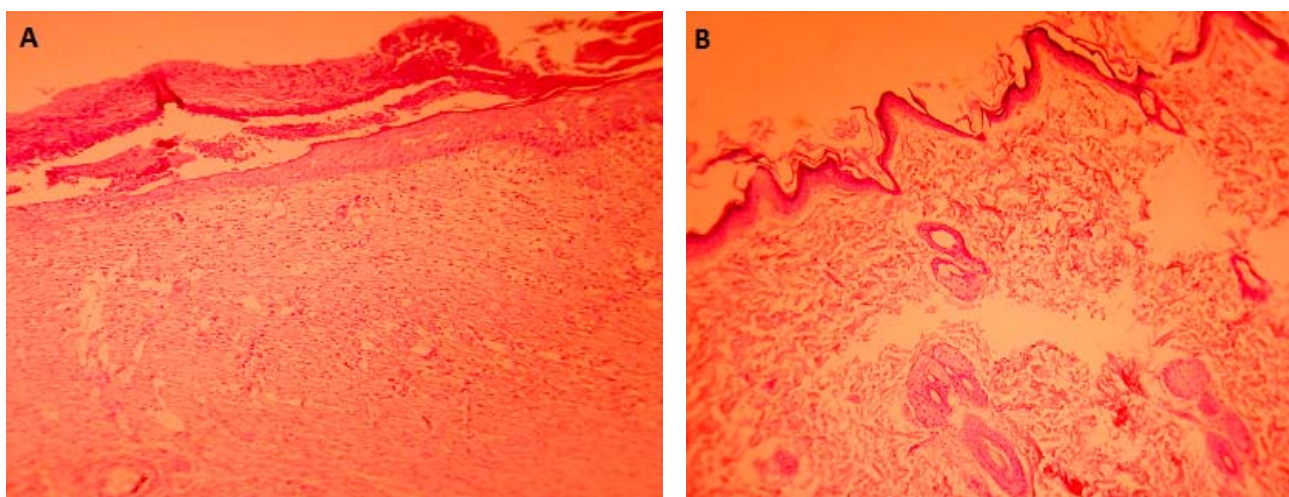
There was no difference in percentage of wound contraction, hydroxyproline level and histopathological evaluation between control and vehicle groups. The histopathological scores were determined in the control, vehicle and treatment groups. Epithelialization and inflammation were significantly different between vehicle group and treatment group (Table 1). Although on day 5 no significant epithelization was observed in the vehicle and treatment groups, silymarin significantly increased epithelization on days 10 and 15 in the silymarin group compared to the vehicle group ( $P=0.008$ ) (Figure 1 and Table 1). Silymarin also significantly reduced inflammation in the silymarin group compared to the vehicle group on days 5, 10 and 15 ( $P=0.032$ ) (Table 1). There was no difference in percentage of wound contraction between treatment and vehicle groups ( $P > 0.05$ ) (Figure 2). As shown in Table 1 and Figure 3, no significant difference was observed in the collagenization and hydroxyproline levels in the vehicle and treatment groups ( $P > 0.05$ ).

**Table 1.** Histopathological scores in control rats and rats treated with polyethylene glycol (vehicle) or silymarin (treatment) groups.

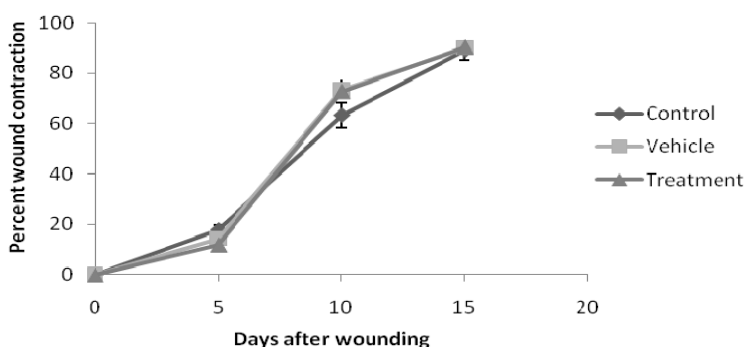
Parameters	Day 5	Day 10	Day 15
Epithelization			
Control	0	1 (1-1.5)	1 (1-1.5)
Vehicle	0	1 (0.5-1)	1 (1-1)
Treatment	0	2 (2-2)**	2 (2-2.5)**
Inflammation			
Control	2 (1.5-2)	2 (1-2)	2 (1-2)
Vehicle	2 (1.5-3)	2 (1.5-2)	2 (1.5-2)
Treatment	1 (1-1)*	1 (1-1)*	1 (1-1)*
Collagenization			
Control	1(1-1)	1 (1-2)	2 (2-3)
Vehicle	1(1-1)	1 (1-2)	3 (2-3)
Treatment	1(1-1)	2 (1.5-3)	3 (3-3)

Medians (interquartile range) are shown.

\*  $P < 0.05$ , \*\*  $P < 0.01$ .  $P$  values compared to vehicle control are shown in the insets (Mann-Whitney U-test).

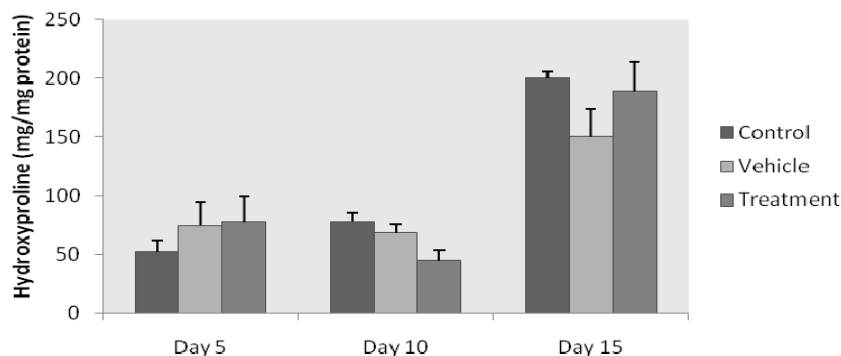


**Figure 1.** (A) Vehicle wound tissue on 15<sup>th</sup> day, showing focal ulceration of surface epithelium (H&D×100). (B) Silymarin treated wound tissue on 15<sup>th</sup> day, showing intact surface epithelium with no ulceration (H&E×100).



**Figure 2.** Comparison of the percent of wound contraction in control, vehicle (treated with polyethylene glycol), and treatment (treated with silymarin) groups at different days. Results are presented as mean  $\pm$  SEM. There is no significant difference between groups.

## Effect of topical application of silymarin



**Figure 3.** Hydroxyproline levels in wound tissue during wound healing. Levels were measured in control rats and rats treated with polyethylene glycol (vehicle) or silymarin (treatment), 5, 10, and 15 days after wounding. Results are presented as mean $\pm$ SEM. There is no significant difference between groups.

## Discussion

Wound healing is categorized into three stages; inflammatory phase (consisting of homeostasis and inflammation); proliferative phase (consisting of granulation, contraction and epithelialisation) and the remodeling phase which ultimately determines the appearance of the healed tissue and its strength (1). Contraction and epithelialization are two independent processes that heal full-thickness cutaneous wounds (20). Contraction reduces the size of a wound by centripetal movement of the dermis and epidermis to facilitate closure of the defect. Epithelialization is the process that cells from the epidermis at a wound's edge proliferate and migrate to cover the surface of the cutaneous defect (21).

Regulation of inflammation and oxidation are important in the process of wound healing. Production of free radicals in response to cutaneous injury, may contribute to delay wound healing through the destruction of lipids, proteins and extracellular matrix elements (22). Silymarin possesses significant antioxidant activity, which would help to prevent oxidative damage and promote the healing process. In this study, we found that silymarin can increase epithelization of wounds, but doesn't have any effect on percentage of wound contraction. Svobodova *et al.* showed that silymarin acts as a powerful inhibitor against hydrogen peroxide damage in human keratinocytes and mouse fibroblasts (13). It was demonstrated that a number of endogenous antioxidants, including GSH, superoxide dismutase (SOD), catalase (CAT), glutathione peroxidase (GPx), glutathione reductase (GR), and glucose-6-phosphate dehydrogenase (G6PD) can be induced by silymarin (23). Oral administration of silymarin has been shown to reduce

lipid peroxidation of brain tissues in acetaminophen-induced toxicity by enhancing antioxidant enzymes (24).

The acute inflammation during the early stages of wound healing generates factors that are essential for tissue repair, but a prolonged inflammatory phase may lead to cell destruction and altered composition of the extracellular matrix with subsequent failure of epithelization (25-27). It was shown in this study that silymarin is able to reduce inflammation in wounds. In previous studies it has been shown that, silymarin is a potent and specific inhibitor of nuclear transcription factor  $\kappa$ B, and also modulates immune response, by augmenting synthesis of anti-inflammatory cytokines, such as IL-10, IL-12 (11,28,29). Furthermore, Toklu *et al.* showed that administration of silymarin was effective against burn-induced oxidative damage and depressed TNF- $\alpha$  and reversed MDA and glutathione levels (15). By histopathological evaluation of tissue samples we have also shown that, the inflammatory cells were significantly decrease by silymarin during wound healing. Thus, silymarin may enhance epithelization through its antioxidant properties and ROS scavenging effects, in addition to its multiple anti-inflammatory properties.

In this study it was shown for the first time that silymarin has no effect on collagen deposition and hydroxyproline level in vivo. It was shown previously that silibinin, the major component of silymarin, has no effect on type I collagen synthesis in vitro (30). Thus the effect of silymarin on wound healing process can be attributed to its effect on epithelization and inflammation.

According to the results of the present study, silymarin can significantly stimulate epithelization in full-thickness wound in rats. It can also reduce inflammation in cutaneous wounds. Therefore, silymarin

may be useful as a therapeutic agent for the treatment of cutaneous wounds. Further studies should be performed to determine the molecular mechanism of silymarin in wound healing.

## Acknowledgements

This article is a part of the PhD thesis, which was financially supported by Tehran University of Medical Sciences (Grant No. 88-1-30-8602) and Food and Drug Control Laboratory and Research Center. We are grateful to Mr Lotfi and Mr Asghar Nejad from Food and Drug Control laboratory, for their kind cooperation and providing necessary infrastructure facilities.

## References

- Diegelmann RF, Evans MC. Wound healing: an overview of acute, fibrotic and delayed healing. *Front Biosci* 2004;9:283-9.
- James TJ, Hughes MA, Hofman D, Cherry GW, Taylor RP. Antioxidant characteristics of chronic wound fluid. *Br J Dermatol* 2001;145(1):185-6.
- Musalmah M, Fairuz AH, Gapor MT, Ngah WZ. Effect of vitamin E on plasma malondialdehyde, antioxidant enzyme levels and the rates of wound closures during wound healing in normal and diabetic rats. *Asia Pac J Clin Nutr* 2002;11 Suppl 7:S448-51.
- Lodhi S, Pawar RS, Jain AP, Singhai A. Wound healing potential of *Tephrosia purpurea* (Linn.) Pers. in rats. *J Ethnopharmacol* 2006;108(2):204-10.
- Majumdar M, Nayeem N, Kamath JV, Asad M. Evaluation of *Tectona grandis* leaves for wound healing activity. *Pak J Pharm Sci* 2007;20(2):120-4.
- Suguna L, Singh S, Sivakumar P, Sampath P, Chandrakasan G. Influence of *Terminalia chebula* on dermal wound healing in rats. *Phytother Res* 2002;16(3):227-31.
- Gazák R, Walterová D, Kren V. Silybin and silymarin: New and emerging applications in medicine. *Curr Med Chem* 2007;14(3):315-38.
- Gu M, Singh RP, Dhanalakshmi S, Agarwal C, Agarwal R. Silibinin inhibits inflammatory and angiogenic attributes in photocarcinogenesis in SKH-1 hairless mice. *Cancer Res* 2007;67(7):3483-91.
- Katiyar SK. Treatment of silymarin, a plant flavonoid, prevents ultraviolet light-induced immune suppression and oxidative stress in mouse skin. *Int J Oncol* 2002;21(6):1213-22.
- Katiyar SK, Korman NJ, Mukhtar H, Agarwal R. Protective effects of silymarin against photocarcinogenesis in a mouse skin model. *J Natl Cancer Inst* 1997;89(8):556-66.
- Meeran SM, Katiyar S, Elmets CA, Katiyar SK. Silymarin inhibits UV radiation-induced immunosuppression through augmentation of interleukin-12 in mice. *Mol Cancer Ther* 2006;5(7):1660-8.
- Singh RP, Agarwal R. Flavonoid antioxidant silymarin and skin cancer. *Antioxid Redox Signal* 2002;4(4):655-63.
- Svobodová A, Walterová D, Psotová J. Influence of silymarin and its flavonolignans on H<sub>2</sub>O<sub>2</sub>-induced oxidative stress in human keratinocytes and mouse fibroblasts. *Burns* 2006;32(8):973-9.
- Svobodová A, Zdarilová A, Malisková J, Mikulková H, Walterová D, Vostalová J. Attenuation of UVA-induced damage to human keratinocytes by silymarin. *J Dermatol Sci* 2007;46(1):21-30.
- Toklu HZ, Tunalı-Akbay T, Erkanlı G, Yüksel M, Ercan F, Sener G. Silymarin, the antioxidant component of *Silybum marianum*, protects against burn-induced oxidative skin injury. *Burns* 2007;33(7):908-16.
- Zhao J, Lahiri-Chatterjee M, Sharma Y, Agarwal R. Inhibitory effect of a flavonoid antioxidant silymarin on benzoyl peroxide-induced tumor promotion, oxidative stress and inflammatory responses in SENCAR mouse skin. *Carcinogenesis* 2000;21(4):811-6.
- Abramov Y, Golden B, Sullivan M, Botros SM, Miller JJ, Alshahrour A, Goldberg RP, Sand PK. Histologic characterization of vaginal vs. abdominal surgical wound healing in a rabbit model. *Wound Repair Regen* 2007;15(1):80-6.
- Woessner JF Jr. The determination of hydroxyproline in tissue and protein samples containing small proportions of this imino acid. *Arch Biochem Biophys* 1961;93:440-7.
- Cardoso CR, Souza MA, Ferro EA, Favoreto S Jr, Pena JD. Influence of topical administration of n-3 and n-6 essential and n-9 nonessential fatty acids on the healing of cutaneous wounds. *Wound Repair Regen* 2004;12(2):235-43.
- Swaim SF, Lee AH. Topical wound medications: a review. *J Am Vet Med Assoc* 1987;190(12):1588-93.
- Swaim SF, Hinkle SH, Bradley DM. Wound contraction: basic and clinical factors. *Compend Contin Educ Pract Vet* 2001;23(1):20-4.
- Russo A, Longo R, Vanella A. Antioxidant activity of propolis: role of caffeic acid phenethyl ester and galangin. *Fitoterapia* 2002;73 Suppl 1:S21-9.
- Ramakrishnan G, Raghavendran HR, Vinodhkumar R, Devaki T. Suppression of N-nitrosodiethylamine induced hepatocarcinogenesis by silymarin in rats. *Chem Biol Interact* 2006;161(2):104-14.

## Effect of topical application of silymarin

24. Nencini C, Giorgi G, Micheli L. Protective effect of silymarin on oxidative stress in rat brain. *Phytomedicine* 2007;14(2-3):129-35.
25. Cotran RS, Kumar V, Robbins SL, Schoen FJ, editors. *Robbins Pathologic Basis of Disease*. Philadelphia, PA: WB Saunders; 1994. p. 35-92.
26. Eming SA, Werner S, Bugnon P, Wickenhauser C, Siewe L, Utermöhlen O, Davidson JM, Krieg T, Roers A. Accelerated wound closure in mice deficient for interleukin-10. *Am J Pathol* 2007;170(1):188-202.
27. Gutiérrez-Fernández A, Inada M, Balbín M, Fueyo A, Pitiot AS, Astudillo A, Hirose K, Hirata M, Shapiro SD, Noël A, Werb Z, Krane SM, López-Otín C, Puente XS. Increased inflammation delays wound healing in mice deficient in collagenase-2 (MMP-8). *FASEB J* 2007;21(10):2580-91.
28. Chang JW, Kim CS, Kim SB, Park SK, Park JS, Lee SK. Proinflammatory cytokine-induced NF-kappaB activation in human mesangial cells is mediated through intracellular calcium but not ROS: effects of silymarin. *Nephron Exp Nephrol* 2006;103(4):e156-65.
29. Schümann J, Prockl J, Kiemer AK, Vollmar AM, Bang R, Tiegs G. Silibinin protects mice from T cell-dependent liver injury. *J Hepatol* 2003;39(3):333-40.
30. Hashem MA, Jun KY, Lee E, Lim S, Choo HY, Kwon Y. A rapid and sensitive screening system for human type I collagen with the aim of discovering potent anti-aging or anti-fibrotic compounds. *Mol Cells* 2008;26(6):625-30.