

The Running Y-V Plasty for Treatment of Linear and Cord-Like Burn Contractures

Ehsan Arasteh and Masoud Yavari

Department of Plastic and Reconstructive Surgery, 15 Khordad Hospital,
Shahid Beheshti University of Medical Sciences, Tehran, Iran

Received: 3 Apr. 2012; Received in revised form: 14 Aug. 2012; Accepted: 26 Nov. 2012

Abstract- Linear and cord-like burn scar contractures are commonly treated by severing the scar in a transverse direction and skin grafting or performing Z-plasties. However, skin grafts may result in suboptimal take and contract gradually and the Z-plasty requires undermining flaps in scarred skin which may lead to the distal tip necrosis. In this article the authors present their experience with multiple Y-V plasty technique. From May 2005 to September 2009, 44 linear and narrow cord-like burn contractures in various regions of upper and lower extremities of 32 patients were treated by multiple Y-V plasty technique. The contracted scars were treated successfully in all of the patients. No major post-operative complications or contracture recurrence were observed during the follow up period of 6 to 24 months in this series of patients. By creating a longer length, running Y-V plasty can relax the contracted scar. Considering the advantages and excellent results in the treated patients in this study group, and also other presented series, multiple Y-V plasty can be recommended as a very useful and safe technique for the treatment of linear and cordlike burn contractures.

© 2012 Tehran University of Medical Sciences. All rights reserved.

Acta Medica Iranica, 2012; 50(11): 729-734.

Keywords: Cord like burn scar; Scar contraction; Y-V plasty

Introduction

Despite the recent improvements in the treatment of burn wounds, late hypertrophic scars and contractures may develop. Several surgical techniques have been used for the reconstruction of established burn scar contractures, including skin grafting and different types of local, regional, distal and free flaps (1-5). Linear and cord-like burn scar contractures are commonly treated by severing the scar in a transverse direction and skin grafting (3,6) or performing Z-plasties (7). However, skin grafts may result in suboptimal take and contract gradually, and Z-plasty requires undermining the flaps in scarred skin which may lead to flap tip necrosis.

Syzmanowski in 1865 used a single Y-V plasty to widen the oral commissure. Bier later in 1922 employed multiple Y-V plasty to advance local skin into an adjacent soft tissue defect. Finally, Palmén described the usage of this technique in the treatment of Dupuytren's contracture, syndactyly, and elongation of burn scar contracture bands (8-10).

Comparing to the methods mentioned above, the running or multiple Y-V plasty technique has certain advantages, and fewer complications. In this article the authors present their favorable experience with this technique in 44 linear and narrow scar contractures in various regions of upper and lower extremities.

Patients and Methods

From May 2005 to September 2009, 44 linear and narrow cord-like burn contractures in various regions of upper and lower extremities of 32 patients were treated by multiple Y-V plasty technique. The interval between thermal damage and referral to the authors ranged from 6 months to 16 years with the averaged of 3 years. Eighteen patients had previous operations for the treatment of burn contracture. Patients in this study group included 19 male and 15 female ranging in age from 3 to 42 years with the average of 16. The region of contracture was finger in 23 (52.3%), palm in 3 (6.8%), wrist and forearm in 4 (9.1%), elbow in 3 (6.8%), axilla and arm in 4 (9.1%), axilla to wrist in 1 (2.3%), chest

Y-V plasty for treatment of contractures

and both axillary regions in 1 (2.3%), popliteal region in 3 (6.8%), and dorsum of the foot and ankle in 2 (4.5%) cases (Figures 1-5).

Scar length varied from 3 to 40cm. The number of Y to V flaps used ranged from 4 to 21, depending on the length and site of the contracted scar.

Operative marking

Whole length of the scar is marked, and a zigzag line (the running Vs) was sketched continuously in two sides

of the scar central line, alternatively. The number, size, and the tip angle of Vs varied depending on the case. However, to prevent flap tip necrosis, acute angles (less than 60°) was avoided. The stems of Ys are drawn at the tip of each V. An essential point is to sketch the lines when the scar is a relaxed and not in a stretched position, otherwise, after incising the marked lines, the triangles contract to the original width and the tip angles reduce significantly (Figures 1-5).

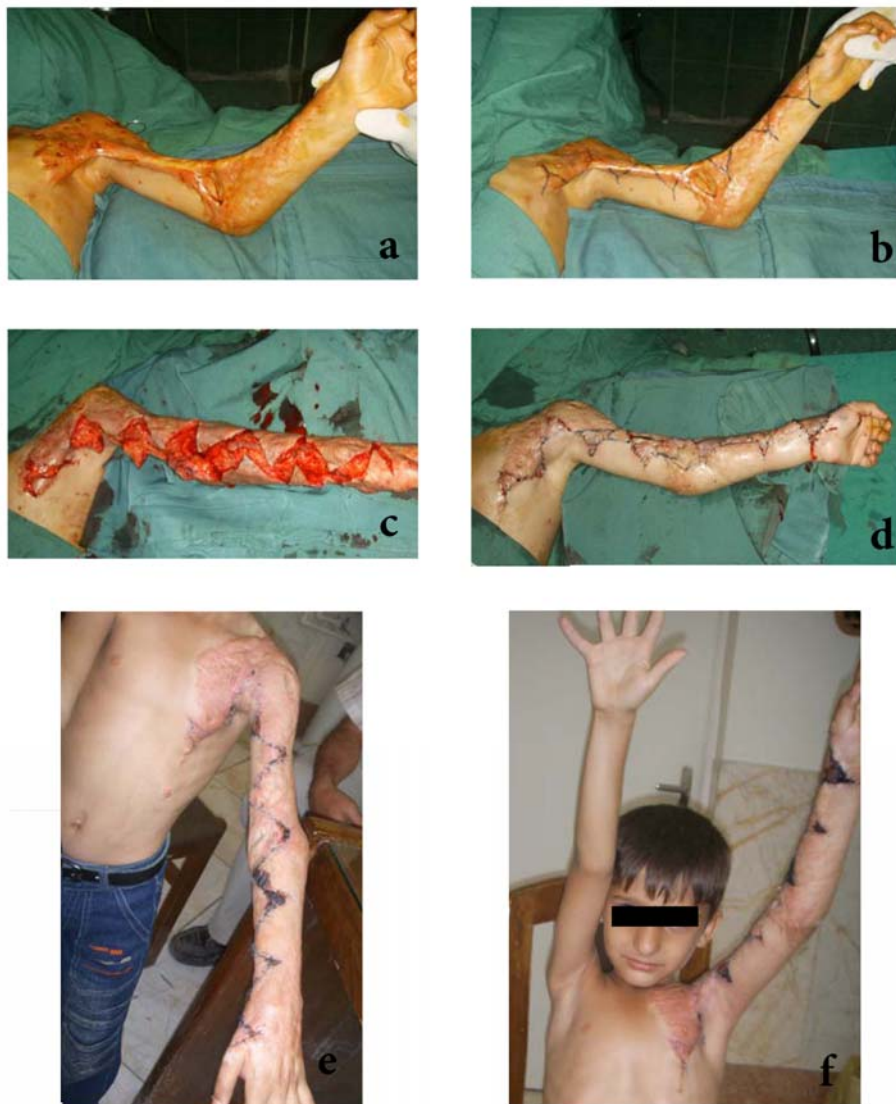


Figure 1. A 5 year old patient with a severely contracted cord like scar referred 18 months after burn accident. a) Contracted scar was extended from chest to axilla, arm, elbow, and forearm. b) A zigzag line (the running Vs) sketched continuously in two sides of the scar line alternatively. The stems of Ys were drawn at the tip of each V. c) All the outlined flaps were first incised only down to the dermis to avoid distortion of previous markings. Then incision proceeded perpendicularly through the scar down to the underlying healthy fat or fascia. d) The incised V flaps were advanced into the Ys stems, and finally the procedure ends with a zigzag repair line in the length of the previous scar. e) The contracted scar was treated successfully, and the patient could abduct and extend the shoulder, and extend the elbow completely 3 weeks postoperatively. f) Tip necrosis in two V flaps occurred which were treated by repeated dressings, and the wound healed uneventful without recurrence of contracture.

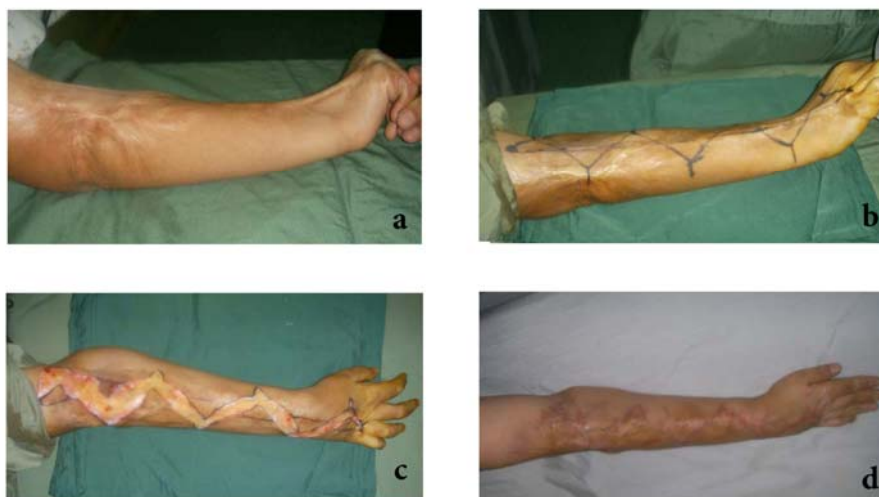

Figure 2. A 12 year old patient was referred 3 years after flame thermal damage. a) Cord like contracture in the dorsum of the hand, wrist, and forearm. b) Opposite Ys are sketched. c) The lines are incised down to the normal fat tissue. d) Three months postoperatively, contracture was relieved completely.

Surgical technique

All the outlined flaps were first incised only down to the dermis to avoid distortion of previous markings. Then incision proceeded perpendicularly through the scar down to the underlying healthy fat or fascia. Meticulous handling of the flaps without any undermining guaranteed the flap survival. The incised V

flaps were advanced completely into the Ys stems in an interdigitating fashion, and finally the procedure ended with a zigzag repair line in the length of the previous scar (Figures 1-5). Post-operative splinting was not necessary and the patients were able to begin mobilization immediately after the operation.

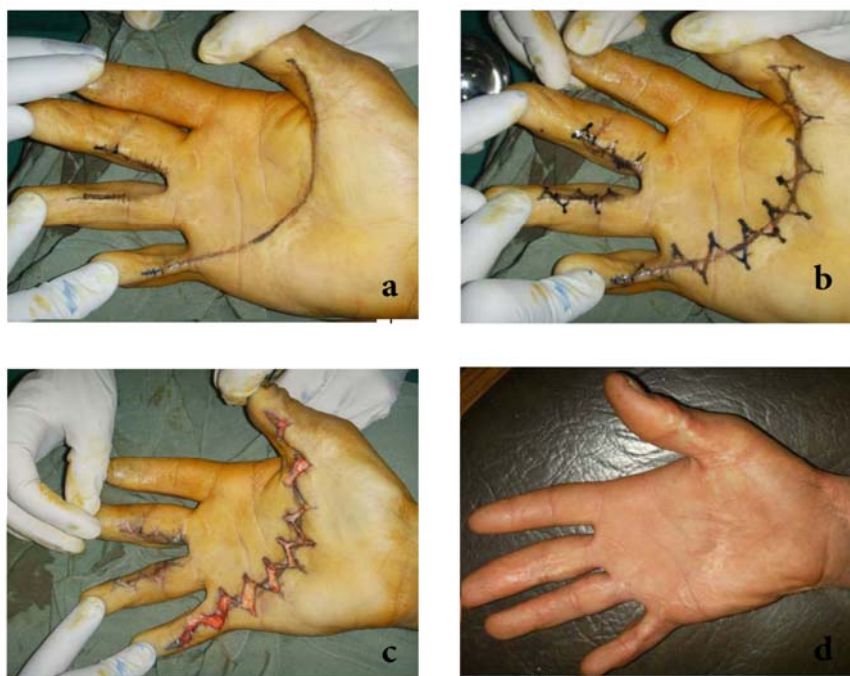


Figure 3. A 26 year old man burned 8 years prior to the referral. a) An established palmar linear contractures which continued to the thumb and little finger and two other linear contractures in palmar aspects of the ring and middle fingers are visible. b, c) Multiple Ys are sketched and incised in two sides of the scars. d) Four months postoperatively, the scars are fully released and the palm and finger contractures were relieved successfully.

Y-V plasty for treatment of contractures

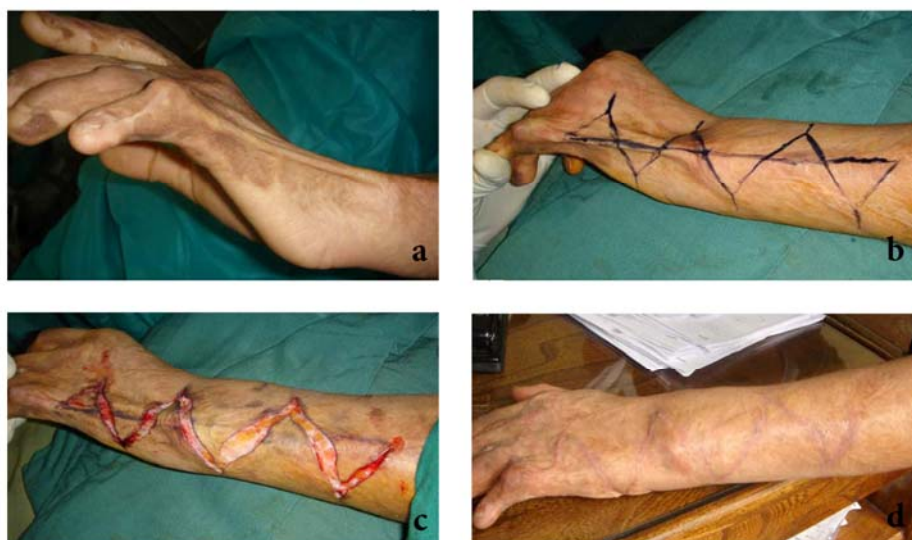

Figure 4. A patient was referred 5 years after burn injury. a) A cord like linear contracture in the dorsum of the little finger, hand, wrist, and distal forearm. b, c) marking and incising Y flaps in the length of the scar followed by the flaps advancement toward the stems of Ys. d) The final result 6 month after the operation. No sign of contracture remains.

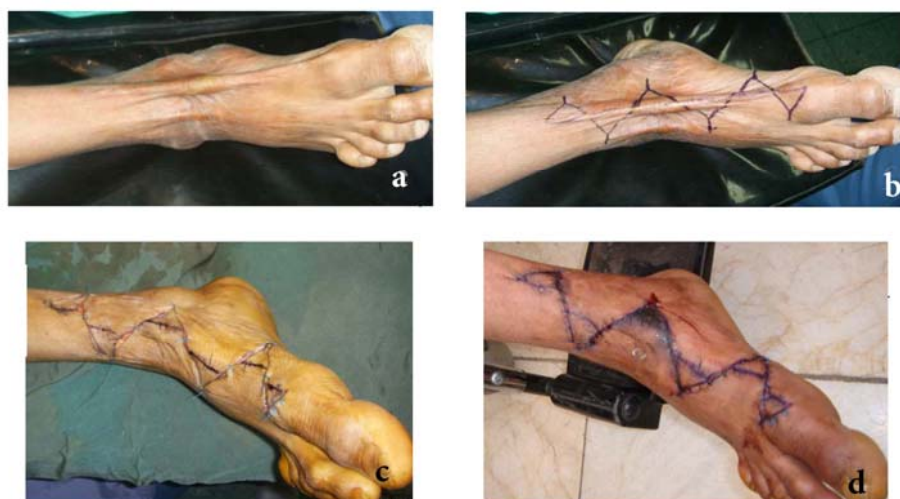

Figure 5. a) A cord like burn contracture in the dorsum of the foot in a 42 year old patient. b) The Y flaps are marked. c) After incising, the flaps were advanced, and the skin is repaired. d) Three weeks post-operatively, a dramatic increase of scar length is observable. Superficial necrosis of one of the flaps healed and re-epithelialized in 4 weeks.

Geometrical principles

The surface of the field of operation (scar area) is considered as a rectangle of length L and width w (Figure 6a). This rectangle is subdivided into a number of triangles (Figure 6b). To advance this series of triangles relative to one another, all the way until their bases align (Figure 6d), the stem of each Y (s) must be the same length as the sides of the triangles (i.e. $s=c$). It is clear that the total resultant theoretical length achievable by advancement is equal to the sum of the bases of all the triangles.

Since the bases of all triangles in each side of contracture band add up to L , regardless of their individual sizes and tip angles, and since all the triangular bases are aligned in series at the end of full advancement, it can be seen that this simply represents a doubling of the original scar length from L to $2L$ (figure 6d). This is the maximum theoretical length attainable. Usually in real clinical practice the length of Y stems are shorter and the triangles are not fully advanced. Therefore, a shorter final scar length is attained (Figure 6c).

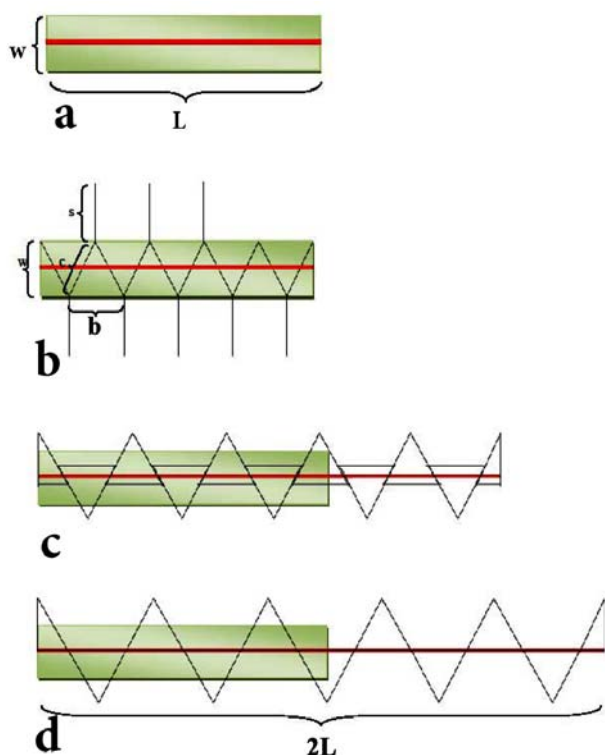


Figure 6. This diagram is a representation of running Y-V plasty effectiveness in scar lengthening. a) A contracted scar is represented by a green rectangular area with the length of L and width of W , and a central red scar line. b) A zigzag line in two sides of the central scar subdivided the rectangle to opposing triangles. The Ys stems (s) are drawn from the tip of each triangle. c) Partial advancement of triangles along the Ys results in lengthening of the central scar line which clinically means releasing of the contracture. d) Full advancement of triangles doubles the length of scar. Ys in (b) convert to Vs in (c) or (d) which is the cause of denomination of this procedure. The increase in scar length varies depending on the extent of advancement (length of Y stems). (a modified adaptation from diagram in ref:8)

Neither the angles of Ys nor the number of triangles in the design play a role in the ultimate length gained. The length of primary scar and the length of Ys stems are the determinants of final length achieved (8,11).

Results

The contracted scars were treated successfully in all of the 32 patients and after a follow up period of 6 to 24 months no recurrence was observed. In this series of patients, there was no major post-operative complication. Tip necrosis occurred in two V flaps which were conservatively treated by repeated the dressings. The wound healed uneventful without

recurrence of contracture or any major effect on the final outcome.

Discussion

A linear and cord-like contracted burn scars may result in moderate to major restriction in the range of motion of single or multiple joints of a limb. In addition these scars affect the total position of the limb at rest and movement, resulting in psychological concerns for the patients. Employing running Y-V plasties increase the scar length, relax the contracted scar, and allow the joints to move freely.

Among various methods used for the treatment of linear and cord-like contractures running Y-V plasty have definite advantages. Contrary to Z-plasty, no undermining is necessary. Therefore, the flaps are reliable and the triangles can be made as narrow as clinically necessitated. Furthermore, in the event of contracture recurrence, surgical revision can be performed and it is safe to design a new Y-V plasty along the old scars without the fear of dividing pedicles and compromising flap blood supply. However, a surgical revision is considered risky in the cases of the previously undermined Z-plasty. The theoretical ultimate attainable length in Y-V plasty is up to 100% of the original scar length compared to the approximately 75% lengthening for a 60° Z-plasty. Contrary to Z-plasty the angles and number of Y flaps play no role in the ultimate gain in scar length and degree of contracture release. This principle provides flexibility in planning and freedom in adjusting the amount of skin elongation. This Technique also has other practical clinical implications. For example, if an anatomical land mark such as nipple, axillary hairline, or an important skin crease is closed to a region of the scar, the individual flaps can be fashioned to minimize distortion (8,9,11-14). Also running Y-V plasties obviates the need for skin grafting in appropriate cases, therefore, avoiding the post-operative complications of incomplete take and relapse of contracture or associate donor site morbidity. Considering these advantages and excellent results in this series of patients and also other presented series, multiple Y-V plasty can be recommended as a very useful and safe technique for treatment of linear and cordlike burn contractures.

References

1. Kurtzman LC, Stern PJ. Upper extremity burn contractures. *Hand Clin.* 1990; (6): 261-79.

Y-V plasty for treatment of contractures

- Hudson DA, Renshaw A. An algorithm for the release of burn contractures of the extremities. *Burns*. 2006;(32): 663-8.
- Iwuagwu FC, Wilson D, Bailie F. The use of skin grafts in postburn contracture release: a 10-year review. *Plast Reconstr Surg*. 1999; 103(4):1198-204.
- Tsai FC, Yang JY, Mardini S, Chuang SS, Wei FC. Free split-cutaneous perforator flaps procured using a three-dimensional harvest technique for the reconstruction of postburn contracture defects. *Plast Reconstr Surg*. 2004; 113(1):185-93
- Li YY, Wang JL, Lu Y, Huang J. Resurfacing deep wound of upper extremities with pedicled groin flaps. *Burns*. 2000; 26(3):283-8.
- Metaizeau JP, Gayet C, Schmitt M, Prévot J. The use of free full thickness skin grafts in the treatment of complications of burns. *Prog Pediatr Surg*. 1981; 14:209-23.
- Bretteville-Jensen G. Marking the 60 degree Z-plasty to achieve accurate lengthening. *Br J Plast Surg*. 1977; 30(1):72-3.
- van Niekerk WJ, Taggart I. The size of the Y: the multiple Y-V plasty revisited. *Burns*. 2008; 34(2):257-61.
- Cooper MA. The multiple Y-V plasty in linear burn scar contracture release. *Br J Plast Surg*. 1990; 43(2):145-9.
- Shaw DT, Li CS. Multiple Y-V plasty. *Ann Plast Surg*. 1979; 2(5): 436-40.
- Lin TM, Lee SS, Lai CS, Lin SD. Treatment of axillary burn scar contracture using opposite running Y-V-plasty. *Burns*. 2005; 31(7):894-900.
- Olbrisch RR. Running Y-V plasty. *Ann Plast Surg* 1991; 26(1):52-6.
- Lai CS, Lin SD, Tsai CC, Tsai CW. Running Y-V-plasty for burn scar contracture. *Burns*. 1995;(21(6):458-62.
- Askar I. Double reverse V-Y-plasty in postburn scar contractures: a new modification of V-Y-plasty. *Burns*. 2003; 29(7):721-5.