

## Primary Ovarian and Pararectal Hydatid Cysts Mimicking Pelvic Endometriosis

Murat Bozkurt<sup>1</sup>, Duygu Kara Bozkurt<sup>2</sup>, Ahmet Said ÇİL<sup>3</sup>, and Mehmet Karaman<sup>4</sup>

<sup>1</sup> Department of Obstetrics and Gynecology, Universal Hospital Group, Malatya, Turkey

<sup>2</sup> Department of Radiology, Yeditepe University, Istanbul Turkey

<sup>3</sup> Department of Radiology, Universal Hospital Group, Malatya, Turkey

<sup>4</sup> Department of Pathology, Haydarpasa Training Hospital  
Gulhane Military Medical Academy, Istanbul, Turkey

Received: 4 Nov. 2011; Received in revised form: 6 Nov. 2012; Accepted: 25 Nov. 2012

**Abstract-** We report a case of 48-year-old woman with multiple hydatid cysts in pararectal region and right paraovarian localization with an unusual sonographic and computed tomographic presentation mimicking a pelvic endometriosis. During laparotomy, multiple pararectal and right ovarian cysts resembling endometriosis were resected. Pathologic examination gives the diagnosis of hydatid cysts. Retrospectively, we investigate the primary infection but the patient had no history of hepatic and liver involvement, it is a case of primary infection.

© 2012 Tehran University of Medical Sciences. All rights reserved.

*Acta Medica Iranica*, 2012; 50(12): 839-842.

**Keywords:** Cysts, Hydatid; Echinococcoses; Endometriosis; Pelvic pain

### Introduction

Hydatid disease is an endemic distribution and frequently hepatic involvement. Echinococcus granulosus is a major cause of human hydatid cysts. This infection is more common in countries where people in close contact with cattle, sheep and dogs in their living places. These countries belong to Mediterranean region, middle Europe, south America, Middle East, east Africa, and Australia (1). Liver and lungs are most frequently involved although this infestation seen anywhere in the body due to hematogenous spread. Primary ovarian and pararectal cyst hydatid are extremely rare in the literature a few cases have been reported.

### Case Report

A 48 year-old woman, gravida 5, para 4, presented with abdominal distention and pain in the lower abdomen for three years. The abdominal swelling had been gradually increasing in size. There was a loss of weight and weakness. She had no history of abdominal operation. She had a positive history of direct contact with dogs and sheeps for about 30 years. On vaginal examination,

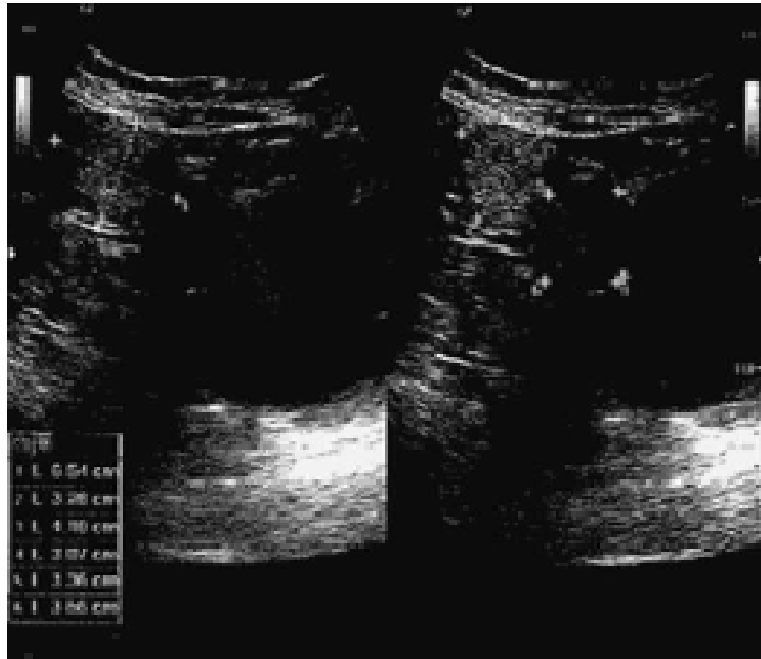
uterus larger than normal and bilateral adnexal mass was palpated. She had a second grade uterine prolaps accompanied by cystocele and rectocele. No other abnormalities were detected on systemic and gynecologic examination.

Abdominopelvic sonography revealed 65 mm, hypoechoic, oval mass with regular contour located in the right ovary and 45 mm, hypoechoic, oval mass located in the left pararectal region and the 30 mm, calcified hypoechoic oval mass were located in the right pararectal region, suggestive of endometriosis. Transvaginal sonographic evaluation showed hypoechoic mass lesions located in the right ovary and bilateral pararectal region (Figure 1). Computed tomography showed hypodense, oval masses with regular contour located in the right ovary and bilateral pararectal region with peripheral enhancement pattern (Figure 2). The tumor marker CA-125 was in normal limits. Preoperative diagnosis was endometriosis.

During laparotomy, multiple cystic oval masses were observed in right ovary and bilateral pararectal region. The cystic mass which was observed in right ovary showed invasion into the adjacent pelvic abdominal soft tissue.

**Corresponding Author:** Ahmet Said ÇİL

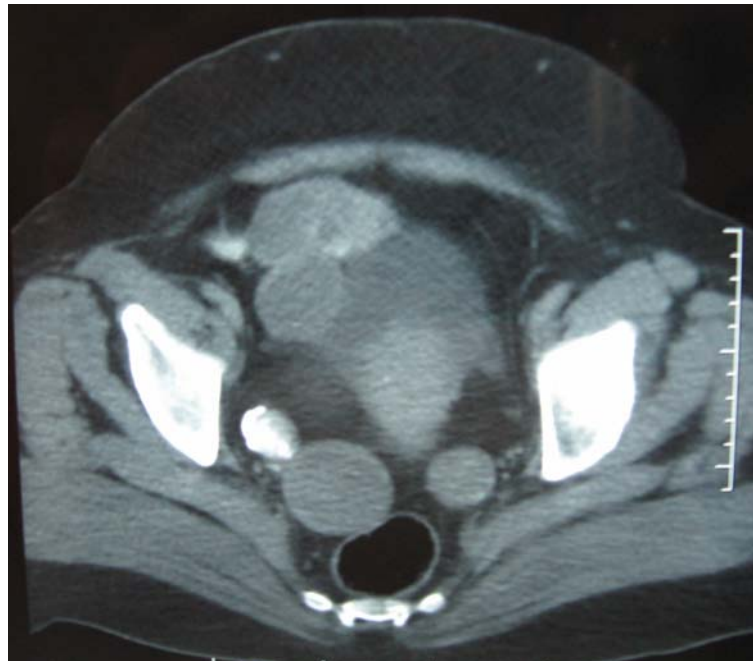
Universal Malatya Hastanesi Turgut Özal Bulvarı Ankara Asfaltı 6 km No:219 44000 Malatya/ Turkey  
Tel: +90 4222382828/1546, Fax: +90 4222382600, E-mail: asaidecil@hotmail.com



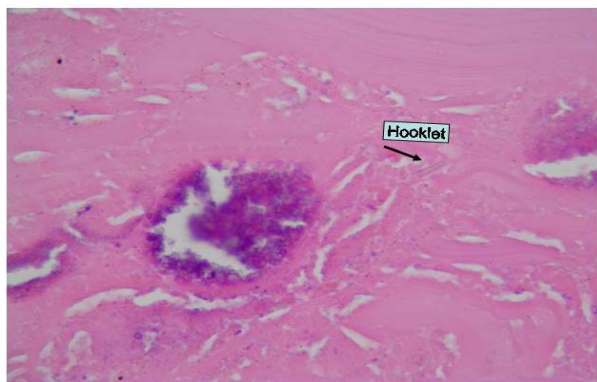
**Figure 1.** Transvaginal sonographic evaluation showed hypoechoic mass lesions located in the right ovary.

Multiple cystic masses located in pararectal region were resected. Total abdominal hysterectomy, bilateral salpingo-oophorectomy was done. Pathological examination showed the diagnosis of cyst hydatid. The cyst wall with outer cuticular membrane and inner germinal layer was also observed. The cyst lumen

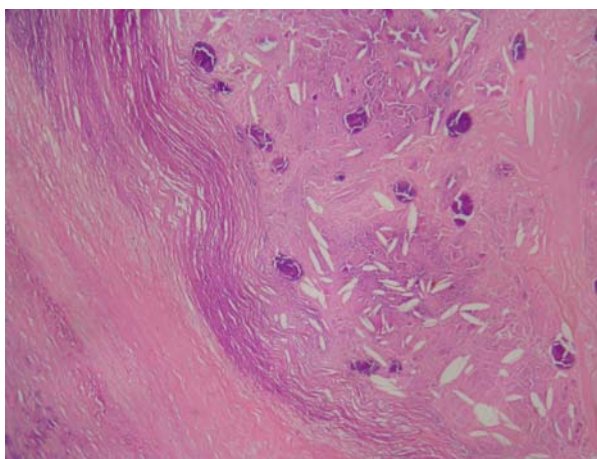
contained scolices and hooklet formation (Figure 3 and 4). Postoperative evaluation with thorax, cranial and abdominal CT scanning, there was no evidence of cyst hydatid disease. Following the pathological and post-operative examination, Albendazole treatment was started.



**Figure 2.** Computed tomography showed hypodense, oval masses with regular contour located in the right ovary and bilateral pararectal region with peripheral enhancement pattern.



**Figure 3.** Hooklet formation.



**Figure 4.** The outer cyst layer 'cuticular membrane'

## Discussion

Hydatid cyst is an endemic disease mostly seen people who has association with dogs and sheeps for a long time. It is found mostly in Mediterranean region, middle Europe, south America, Middle East, east Africa, and Australia. The organs most commonly involved in hydatid disease are the liver and lungs (2). The ovary and the pararectal regions are very rare locations for the hydatid cyst disease. Pelvic cyst hydatid most often secondary to hematogenous and lymphatic distribution of the scolex from the hepatic disease surgery and microruptures. Ovarian, tubal and uterine cyst hydatid have been reported in the literature. We report the primary right paraovarian and bilateral pararectal hydatid cyst mimicking endometriosis. Other intra and extra abdominal organs were evaluated and there was no evidence of hydatid cyst disease.

Also pelvic hydatid disease can present with vague abdominal pains due to irritation, swelling, menstrual irregularities, infertility and pressure symptoms involving the adjacent organs (vascular structures, ureters, bladder and rectum) (3,4,5,6). In our case patient

had severe pelvic pain on vaginal examination, sonographic and tomographic examination reported pararectal and adnexal multiple solid oval mass so that endometriosis was thought firstly. We never thought of hydatid cyst disease because of pararectal location. Computed tomography (CT) reported a calcified hypodense pararectal mass which may be a clue for the differential diagnosis of the cyst hydatid disease.

Radiography, Ultrasonography (US) and CT studies are important for diagnosis of echinococcal disease. Plain abdominal X-rays may show calcifications of the cystic wall (7). US is cost-effective in endemic areas and when the diagnosis of hydatid cyst is certain. However, ultrasonography is less accurate in localising and delineating the extent of the cyst (8). US is particularly useful for the detection of cystic membranes, septa, and hydatid sand within the cyst. The ultrasonographic appearance of hydatid cysts may various Several classification schemes based on cyst appearance have been proposed. The cyst wall usually manifests as double echogenic lines separated by a hypoechogenic layer. Simple cysts do not demonstrate internal structures, although multiple echogenic foci due to hydatid sand may be seen within the lesion by repositioning the patient. The echogenic foci quickly fall to the most dependent portion of the cavity without forming visible strata. This finding has been referred to as the snowstorm sign (9).

The sensitivity of computed tomography is 90%-100% (10). It provides a three-dimensional view and delineates the cyst, which is useful when diagnosis is uncertain, or when rupture or infection has occurred (11).

Serological tests contribute to the diagnosis. Immunoglobulin G antibody detection by ELISA and indirect hemagglutination test have been used.

The World Health Organization has precised the treatment guidelines for hydatid cysts. Surgery is the treatment of choice for all patients with symptomatic disease and who are convenient for surgery (12).

Surgical treatment can be either radical or conservative. Whenever possible, total cystectomy is the gold standard for hydatid cyst treatment. For peritoneal cysts firmly attached to intraperitoneal viscera, uncovering and drainage has been proven to be a safe method. It is important that the abdominal cavity is isolated with gauze soaked in 20% hypertonic saline solution to avoid secondary hydatosis and allergic reaction (13). The most common complications are generalized toxic reaction due to cyst hydatid rupture and secondary infections. Pre-operative medical

treatment reduce the cyst tension, to sterilized the cyst, and to prevent anaphylactic reaction. Post-operative adjuvant albendazole and mebendazole medical treatment prevented recurrence.

Primary ovarian and pararectal cyst hydatid disease is a vary rare entity. Multiple pelvic masses with abnormal radiologic findings, primary ovarian and pelvic cyst hydatid disease should be considered in the differential diagnosis in endemic geographic regions.

## References

1. Aksu MF, Budak E, Ince U, Aksu C. Hydatid cyst of the ovary. *Arch Gynecol Obstet* 1997;261(1): 51-3.
2. Bickers WM. Hydatid disease of the female pelvis. *Am J Obstet and Gynecol* 1970;107(3): 477-83.
3. Pedrosa I, Saiz A, Arrazola J, Ferreiros J, Pedrosa CS. Hydatid disease: radiologic and pathologic features and complications. *Radiographics* 2000;20(3):795-817.
4. Terek MC, Ayan C, Ulukus M, Zekioglu O, Ozkinay E, Erhan Y. Primary pelvic hydatid cyst. *Arch Gynecol Obstet* 2000;264(2):93-6.
5. Seenu V, Misra MC, Tiwari SC, Jain R, Chandrashekhar C. Primary pelvic hydatid cyst presenting with obstructive uropathy and renal failure. *Postgrad Med J* 1994; 70(830):930-2.
6. Solidoro G, Del Gaudio GA. Hydatid cysts of the ovary. Description of a case. *Minerva Chir* 1991;46(10):571-5.
7. Sayek I, Onat D. Diagnosis and treatment of uncomplicated hydatid cyst of the liver. *World J Surg* 2001;25(1):21-7.
8. Safioleas M, Misiakos E, Manti C, Katsikas D, Skalkeas G. Diagnosis evaluation and surgical management of hydatid disease of the liver. *World J Surg* 1994;18(6):859-65.
9. el-Tahir MI, Omojola MF, Malatani T, al-Saigh AH, Ogunbiyi OA. Hydatid disease of the liver: evaluation of ultrasound and computed tomography. *Br J Radiol* 1992;65(773):390-2.
10. Guidelines for treatment of cystic and alveolar echinococcosis in humans. WHO Informal Working Group on Echinococcosis. *Bull World Health Organ* 1996;74(3):231-42.
11. Karavias DD, Vagianos CE, Kakkos SK, Panagopoulos CM, Androulakis JA. Peritoneal echinococcosis. *World J Surg* 1996;20(3):337-40.
12. Mehra BR, Thawait AP, Gupta DO, Narang RR. Giant abdominal hydatid cyst masquerading as ovarian malignancy. *Singapore Med J* 2007;48 (11):e284-6.
13. Ray S, Gangopadhyay M. Hydatid cyst of a ovary: a rare entity. *J Turkish-German Gynecol Assoc* 2010;11: 63-4.
14. Maharlooei MKh, Attar A, Goran A, Amuee S, Dehghan, Monabati A. Hydatid Cyst of Ovary: A Case Report. *Iran J Med Sci* 2009; 34(1): 76-9.
15. Gorgen H, Api M, Çetin A. Primary adnexial hydatid cyst mimicking ovarian tumor. *J Turkish-German Gynecol Assoc* 2009;10: 232-4.
16. Öztürk I, Dilek TUK, Gurses I, Dilek S. Primer ovaryen kist hidatik: Olgu sunumu. *Türk Jinekoloji ve Obstetrik Dernegi Dergisi, (TJOD Derg)* 2009;6(4):286- 9.