

A Case of Brainstem Cavernous Angioma Presenting with Persistent Hiccups

Mohammad Ali Arami

Department of Neurology, Milad General Hospital, School of Medicine, Tehran University of Medical Sciences, Tehran, Iran

Received: 11 Jul. 2009; Received in revised form: 18 Aug. 2009; Accepted: 2 Sep. 2009

Abstract- Intractable hiccup most be considered as a symptom of underlying serious pathologies. We report a case of medulla oblongata cavernous angima presented with persistant hiccup and without any improvement during routine nonpharmacologic and pharmacologic treatment regimns. The patient is under our follow up visits and surgery is very high risk for this young girl.

© 2010 Tehran University of Medical Sciences. All rights reserved.

Acta Medica Iranica 2010; 48(4): 277-278.

Key words: Hiccup; Hemangioma, cavernous; brain stem

Introduction

Hiccups are repeated abrupt contractions of the diaphragm and the external intercostals muscles. The glottis closes to prevent inspiration 35 ms after electrical activity rises above the baseline in the diaphragm and external intercostals muscles (1). The exact cause remains a mystery despite centuries of contemplation. Hippocrates and Celsus associated hiccups with liver inflammation and other conditions. Galen believed hiccups were due to violent emotions arousing the stomach. In 1833, Shortt first recognized association between hiccups and phrenic nerve irritation. More than 100 causes of persistent hiccups have been described that may be classified as table 1. Usually hiccups terminate spontaneously within hours and these brief episodes in adults usually are benign and self-limiting. Typical causes for these benign conditions include gastric distention (ie, food, alcohol, air), sudden changes in ambient or gastric temperature, and use of alcohol and/or tobacco in excess. Psychogenic causes (ie, excitement, stress) also may elicit hiccups.

Persistent or intractable episodes are more likely to result from serious pathologic processes. Here we present a case of persistent hiccups that was chief compliant of a medulla oblongata lesion.

Case Report

A 22 years aged girl referred our hospital for evaluation of intractable hiccups for 6 months. The patient had contractions at the rate of one every 3s. The individual was given Chlorpromazine 100 mg daily and Haloperidol up to 10 mg daily with partial effect.

Famotidine and baclofen had no effect. In examination she had no history of trauma or drug history except those for her hiccup in recent weeks. All laboratory tests including metabolic and hematological tests showed normal results. General examination was normal. In neurological examination we found fine nystagmus and brisk tendon reflexes in all limbs. Plantar reflexes were flexor. No cranial nerve involvement was detected. Swallowing and speech were normal. She had normal tandem gait and no ataxia was revealed. Vibration and position senses functions were normal. According to suspected pyramidal system involvement and persistent nystagmus we recommended magnetic resonance study of brain for this patient for exclusion of Central Nervous System (CNS) causes for her hiccups. The MRI study showed a 1.5×2 cm cavernous angioma in medulla oblongata (Figure 1 and 2). Also a small angioma was found in anterior right temporal region (Figure 3).

Our hospital neurosurgeons were consulted for management of this case. They recommended follow up of patient and according the angioma location they found the surgery very high risk and with unpredictable results for hiccup and prognosis. Now the patient is under our close observation and no progress in her clinical condition was detected. No enlargement or hemorrhagic insults were occurred during observation.

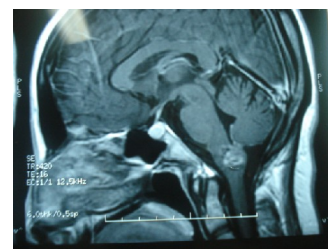


Figure 1. Sagittal T1 MRI of Brain

*Corresponding Author: Mohammad Ali Arami

Department of Neurology, Milad General Hospital, School of Medicine, Tehran University of Medical Sciences, Tehran, Iran
Tel: +98 21 8230000, Fax: +98 21 8230001, E-mail: arami_ma@yahoo.com

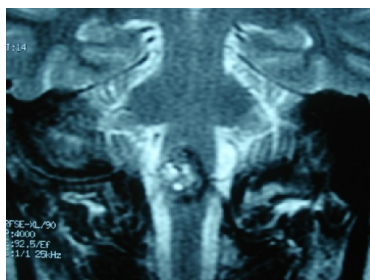


Figure 2. Coronal T2 Brain MRI pateint

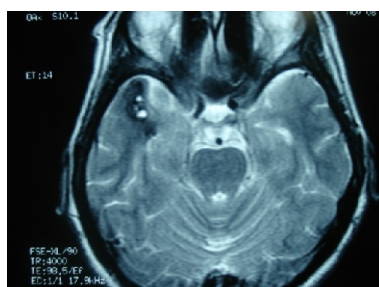


Figure 3. Axial T2 Brain MRI, another angioma in temporal lobe

Discussion

Protracted hiccups often are associated with underlying organic disease and often induce social and emotional distress (2). Pathphysiologic studies have showed that the hiccup reflex, originally proposed by Bailey in 1943, consists of the following: 1) an Afferent limb including phrenic and vagus nerves and sympathetic chain arising from T6 to T12; 2) a hiccup center that is a nonspecific location between C3 and C5 and 3) connections to the respiratory center, phrenic nerve nuclei, medullary reticular formation, and hypothalamus. Efferents for this reflex are: phrenic nerve (C3-5), anterior scalene muscles (C5-7), external intercostals (T1-11), Glottis (recurrent laryngeal component of vagus) (3). Medulla oblongata has a central role in this reflex and lesions in this site could cause hiccup, usually persistent and intractable. Marsot-Dupuch et al in a study to look for central nervous system abnormalities as possible causes of intractable hiccups, performed brain and upper cervical cord MR examination in 9 patients. Five of these 9 patients had definite MR abnormalities located in the temporal lobe (3 cases), cerebellopontine angle (1 case), or areas of high signal intensity compatible with demyelination (1 case). They concluded that brain MRI is a useful investigation in patients with chronic hiccups when gastroesophageal lesions are either excluded or too mild to account for an intractable hiccup (4). The vagus nerve irritation with subsequent hiccups may be caused by chest disorders (injury, surgery) and heart diseases (myocardial infarction). Recently Krysiak et al. described a 62-year-old male with recurrent hiccups

associated with exertion as a secondary symptom of myocardial ischemia (5). Others described hiccup in aseptic meningitis (6), neuromyelitis optica (7), during absence seizure attacks (8) and as a rare prodromal manifestation of herpes zoster (9). Many treatments have been proposed for intractable hiccups, but there is little consensus regarding treatment in the medical literature because intractable hiccups are uncommon and many of the proposed treatments are unproven or have long-term side effects. Some antipsychotic medications had therapeutic effects but long-term of these drugs are not acceptable by most patients. Gabapentin, a new anticonvulsant medication, was presented for the treatment of intractable hiccups for its safety, and rapid onset of action but Further research is needed to investigate efficacy of gabapentin (10).

References

1. Davis JN. An experimental study of hiccup. *Brain* 1970;93(4):851-72.
2. Lewis JH. Hiccups: causes and cures. *J Clin Gastroenterol* 1985;7(6):539-52.
3. Dickerman RD, Jaikumar S. The hiccup reflex arc and persistent hiccups with high-dose anabolic steroids: Is the brainstem the steroid-responsive locus? *Clin Neuropharmacol* 2001;24(1):62-4.
4. Marsot-Dupuch K, Bousson V, Cabane J, Tubiana JM. Intractable hiccups: the role of cerebral MR in cases without systemic cause. *AJNR Am J Neuroradiol* 1995;16(10):2093-100.
5. Krysiak W, Szabowski S, Stepień M, Krzywkowska K, Krzywkowski A, Marciniak P. Hiccups as a myocardial ischemia symptom. *Pol Arch Med Wewn* 2008;118(3):148-51.
6. Sugimoto T, Takeda N, Yamakawa I, Kawai H, Tanaka Y, Sakaguchi M, et al. Intractable hiccup associated with aseptic meningitis in a patient with systemic lupus erythematosus. *Lupus* 2008;17(2):152-3.
7. Takahashi T, Miyazawa I, Misu T, Takano R, Nakashima I, Fujihara K, et al. Intractable hiccup and nausea in neuromyelitis optica with anti-aquaporin-4 antibody: a herald of acute exacerbations. *J Neurol Neurosurg Psychiatry* 2008;79(9):1075-8.
8. Ponnusamy A, Rao G, Baxter P, Field P. Ictal hiccup during absence seizure in a child. *Epileptic Disord* 2008;10(1):53-5.
9. Reddy BV, Sethi G, Aggarwal A. Persistent hiccups: a rare prodromal manifestation of herpes zoster. *Indian J Dermatol Venereol Leprol* 2007;73(5):352-3.
10. Tegeler ML, Baumrucker SJ. Gabapentin for intractable hiccups in palliative care. *Am J Hosp Palliat Care* 2008;25(1):52-4.

