

Cervical Transverse Myelitis After Chickenpox in An Immunocompetent Patient

Mehrnaz Rasoolinejad, Zahra Abdi Layali, Esfandiar Shojaei*, and Saeed Kalantari

Department of Infectious Diseases, Tehran University of Medical Sciences, Tehran, Iran

Received: 9 Jul. 2009; Received in revised form: 27 May 2009; Accepted: 28 Dec. 2009

Abstract- Varicella-zoster viruses complications involving the CNS are estimated to occur rarely, transverse myelitis after Varicella-zoster virus in most patients is characterized by an abrupt onset of progressive weakness and sensory disturbance in the lower extremities, like other viruses. We describe the case of 17 year-old boy who experienced cervical transverse myelitis after chickenpox with inability to walk and with urinary retention. He was not treated with any medication but complete recovery has been occurred.

© 2010 Tehran University of Medical Sciences. All rights reserved.

Acta Medica Iranica 2010; 48(6): 417-418.

Key words: Myelitis, transverse; chickenpox; immunocompetence

Introduction

Neurological complications caused by chickenpox is estimated approximately 0.01-0.3%. Cerebellar ataxia and encephalitis are frequently seen; while transverse myelitis, aseptic meningitis, Guillian-Barre syndrome, meningoencephalitis, ventriculitis, optic neuritis, delayed contralateral hemiparesis, peripheral neuropathy, cerebral angitis, reye syndrome and facial paralysis can rarely be observed (1). Transverse myelitis is characterized by focal inflammation of the spinal cord. Occurrence of transverse myelitis during or following chickenpox is uncommon; we describe a 17 year-old boy of transverse myelitis following chickenpox.

Case Report

A 17 year-old boy was admitted to our center with diffuse crusted lesions through his body which was diagnosed chickenpox. His complaints were inability to walk and urinary retention. He was not treated with any medication. His vital signs were normal. Neurological examination revealed normal level of consciousness, cooperation, orientation and showed that all cranial nerves were intact. Lower extremity weakness of both sides (power 3/5 symmetrically) and absence of bilateral knee and achil reflexes. Cerebrospinal fluid study was normal. His EMG-NCV was nondiagnostic and cervical MRI demonstrated lesions of abnormal signal at C3-C7 levels. The patient was diagnosed with myelitis and we did not perform any medication to him and supportive therapy was initiated. He started improving on the 10th

day of his admission. After 16 days he improved completely and discharged from hospital and was able to walk and no urinary retention was seen.

Discussion

Transverse myelitis is an unusual inflammatory disease involving the entire thickness of the spinal cord. It results in loss of sensory and motor function below the level of injury (2). Post infectious transverse myelitis often begins as the patient appears to recovering from the infection, but an infectious agent cannot be isolated from the nervous system or spinal fluid (3).

It can be the result of immune response to an infection rather than the direct effect of an infectious agent (2). As in our case he finally became well after 16 days with no specific treatment. The CSF usually shows a lymphocytic pleocytosis, elevated protein, and normal glucose (4,5). But in our case CSF analysis was normal.

The diagnosis of transverse myelitis can be made from results of immunological and viral tests and CSF examination and findings from MRI as well as review the clinical manifestations (5). MRI is a sensitive and quite specific tool of investigation for myelitis (6). MRI not only provides information about the site, but also the extent of involvement of spinal cord. In our patient cervical cord was swollen from C₃ to C₇ segments. Cervical myelitis is reported very uncommon (6). There is no established treatment regimen for transverse myelitis as a complication of varicella (7), but there are reports that intravenous methylprednisolone and antiviral treatments might be beneficial (8,9).

*Corresponding Author: Esfandiar Shojaei

Department of Infectious Diseases, Imam Khomeini Hospital, Tehran University of Medical Sciences, Tehran, Iran
Tel: +98 21 61192811, Fax: +98 21 66581598, E-mail:eshojaei@yahoo.com

Cervical myelitis after chickenpox in an immunocompetent patient

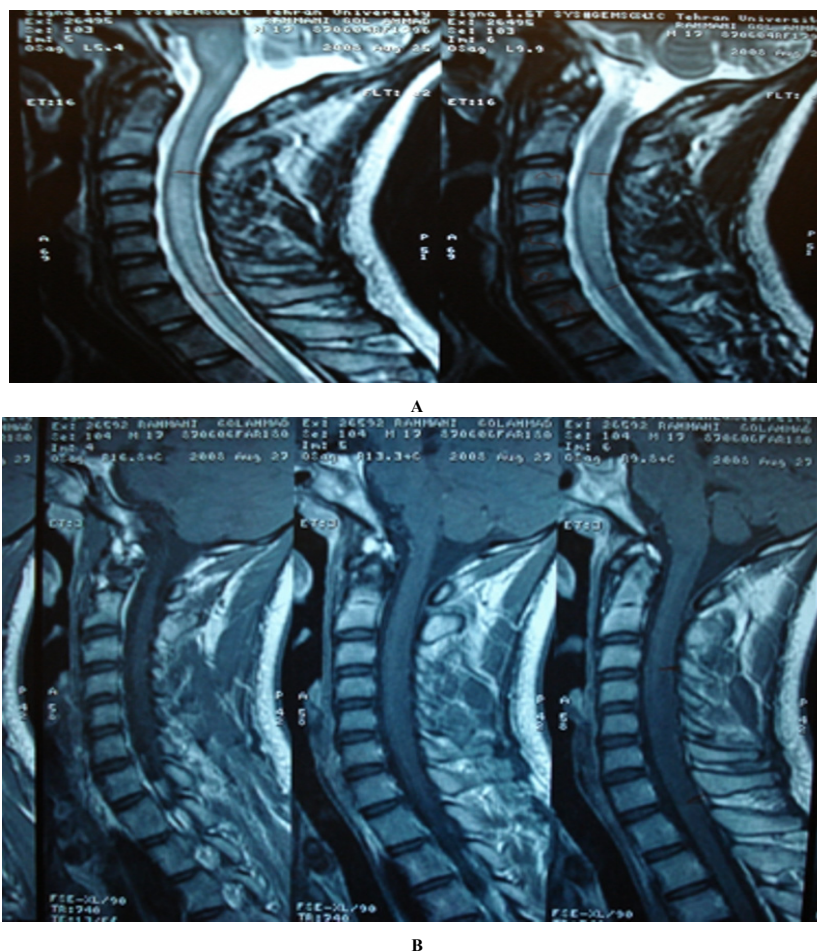


Figure 1. Cervical spine MRI ;There is large abnormal signal focus; extending from C3toC7 causing obvious cord swelling (A), After contrast no obvious enhancement is noted (B).

References

1. Mehndiratta MM, Bansal J, Gupta M, Puri V. Herpes zoster cervical myelitis in an immunocompetent subject. *Neurol India* 2000;48(2):189-90.
2. Yılmaz S, Köseolu HK, Yücel E. Transverse myelitis caused by varicella zoster: case reports. *Braz J Infect Dis* 2007;11(1):179-81.
3. Hauser SL, Ropper AH. Diseases of the spinal cord. In: Fauci AS, Braunwald E, Kasper DL, Hauser SL, Longo DL, Jameson JL, et al, editors. *Harrison's Principles of Internal Medicine*. 16th ed. New York: McGraw-Hill; 2005. p. 2443-4.
4. Hasbun R, Hyslop NE Jr. Myelitis and peripheral neuropathy. In: Schlossberg D, editor. *Clinical Infectious Disease*. New York, NY: Cambridge University Press; 2008. p. 547-61.
5. Kim MY, Suh ES. A case of acute transverse myelitis following chickenpox. *Korean J Pediatr* 2009;52(3):380-384.
6. Hirai T, Korogi Y, Hamatake S, Ikushima I, Shigematsu Y, Takahashi M, et al. Case report: varicella-zoster virus myelitis: serial MR findings. *Br J Radiol* 1996;69(828):1187-90.
7. Jubelt B, Miller J. Viral infection. In: Rouland Lewis P. *Merritt's Neurology*. Philadelphia WB Sanders 2001;152.
8. Banwell BL. The long (itudinally extensive) and the short of it: transverse myelitis in children. *Neurology* 2007;68(18):1447-9.
9. Defresne P, Hollenberg H, Husson B, Tabarki B, Landrieu P, Huault G, et al. Acute transverse myelitis in children: clinical course and prognostic factors. *J Child Neurol* 2003;18(6):401-6.