

## Aneurysmal Bone Cyst Of The Spine

G.A. Teymoorian M.D, A. Slamdoust M.D., F.Bagheri M.D

An Aneurysmal bone cyst is an uncommon, benign, well-circumscribed lesion (1,8,10). It receives its name from its roentgenographic appearance. A comprehensive description of this lesion was given in 1948 by Jaffe and Lichtenstein. Aneurysmal bone cyst has been described in the literature under many seemingly unrelated designations: Ossifying hematoma, Subperiosteal giant-cell tumor, "Hemorrhagic" bone cyst, Atypical giant cell tumor, Aneurysmal giant-cell tumor, Expansile hemangioma, Malignant bone anerysm?

---

From  
Radiological and Neuresugical Department Medical. Pahlavi Medical Centre. Tehran University.

The lesion has been found in almost every bone but it is most common in the metaphyses of the long bones and in the vertebrae (75 % of cases).

Being subperiosteal, the lesion is surrounded by a thin shell of bone, producing a rather specific radiologic appearance. The proximal or distal diaphysis is usually involved. The epiphysis is seldom affected except secondarily in neglected cases. The picture is that of a cystic cavity destroying the cortex, as evidenced by cortex discontinuity. An expansile, denser-than-water mass protrudes eccentrically into the adjacent soft tissues. The rim of this mass is lined by a shell of periosteal new bone measuring a few millimeters in thickness. In the long bones, a variant has been observed in which the lesion is more or less central, causing a fusiform expansion of the bone with destruction of the cortex on both sides. (1,9,10). In the spine aneurysmal bone cyst is most often seen in the cervical region and usually present in the arches and spinous or transverse processes, less frequently in the bodies.

The purpose of this paper is to present two new cases of this benign lesion of the spine and evaluate its roentgen criteria, clinical features, and the influence of surgery or radiotherapy.

### CASE REPORTS NO. 1

B.S., an eleven-year-old boy was admitted to the hospital on October 1969 because of a tender mass in the upper part of the cervical vertebra. The duration of the pain was nearly four months. Suboccipital headache was also present. The mass was at first very small but over the four months it rapidly had reached the size of a small orange.

Physical Examination: A tender mass was noted on the upper part of the neck in the midline. Neck motion was limited in all directions because of pain. Paraspinal muscles were in spasm and diffusely tender. Neurological examination was completely normal. No abdominal or thoracic abnormality was noted.

**Rentgen Examination:** of the cervical vertebra revealed an expansible lesion of the second cervical vertebra in its posterior part which was seen extending into the soft parts, with "eggshell" borders.

This ballooned-out, well-circumscribed appearance of the spinous process of C2 was diagnosed as an aneurysmal bone cyst (Fig 1).

**Operation:** The mass with adjoining tissue was removed: It was a vascular lesion that extended to the dura but did not invade it. The gross appearance was of multiple sinusoids that contained unclotted dark blood. The mass bled freely when cut, but was easily peeled away from the adjacent bone and soft tissues.

**Microscopic appearance:** It was typical of an aneurysmal bone cyst. The walls of the many vascular channels and spaces did not contain muscle or elastic fibers. The fibrous tissue septa contained an abundance of hemosiderin and giant cells as a result of previous hemorrhages (Fig II). No recurrence noted after four years on this patient.

## CASE NO. 2

An eighteen years old girl was admitted because of a tender mass at the level of first dorsal vertebrae. The patient had first noticed it nearly seven months previously.

**Physical Examination:** On examination a tender swelling with smooth surface was noted in the first dorsal vertebrae. No neurological signs were noted. **Radiological Examination:** The body of the first dorsal vertebra was multiloculated and expanded. The left transvers process was expanded too with "eggshell" border. Because of the age of the patient and radiological findings, aneurysmal bone cyst was the first diagnosis (Fig III).

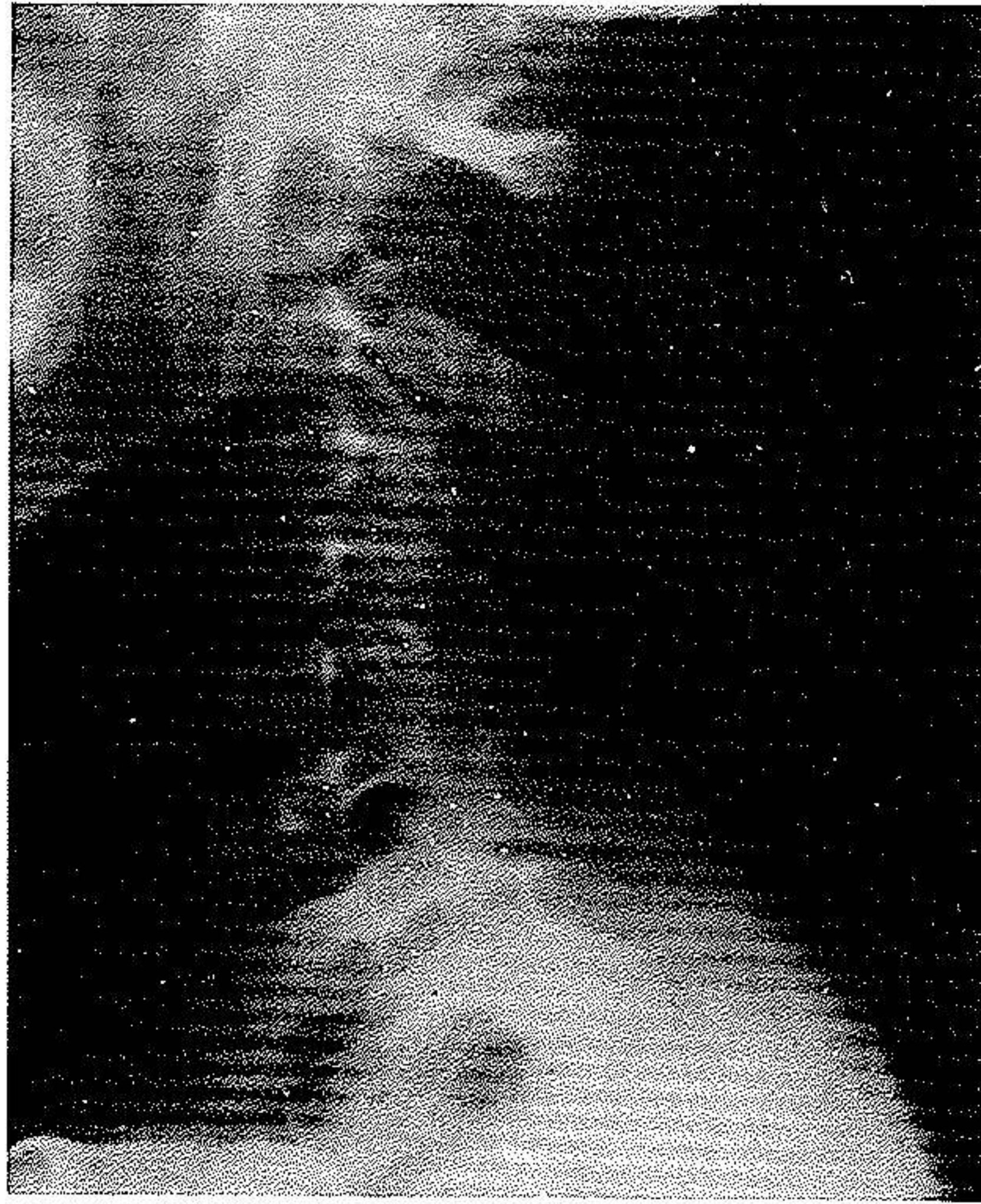

Fig. 1. Aneurysmal bone cyst of C2. There is expansion of the spinous process of C2 with "eggshell" borders.

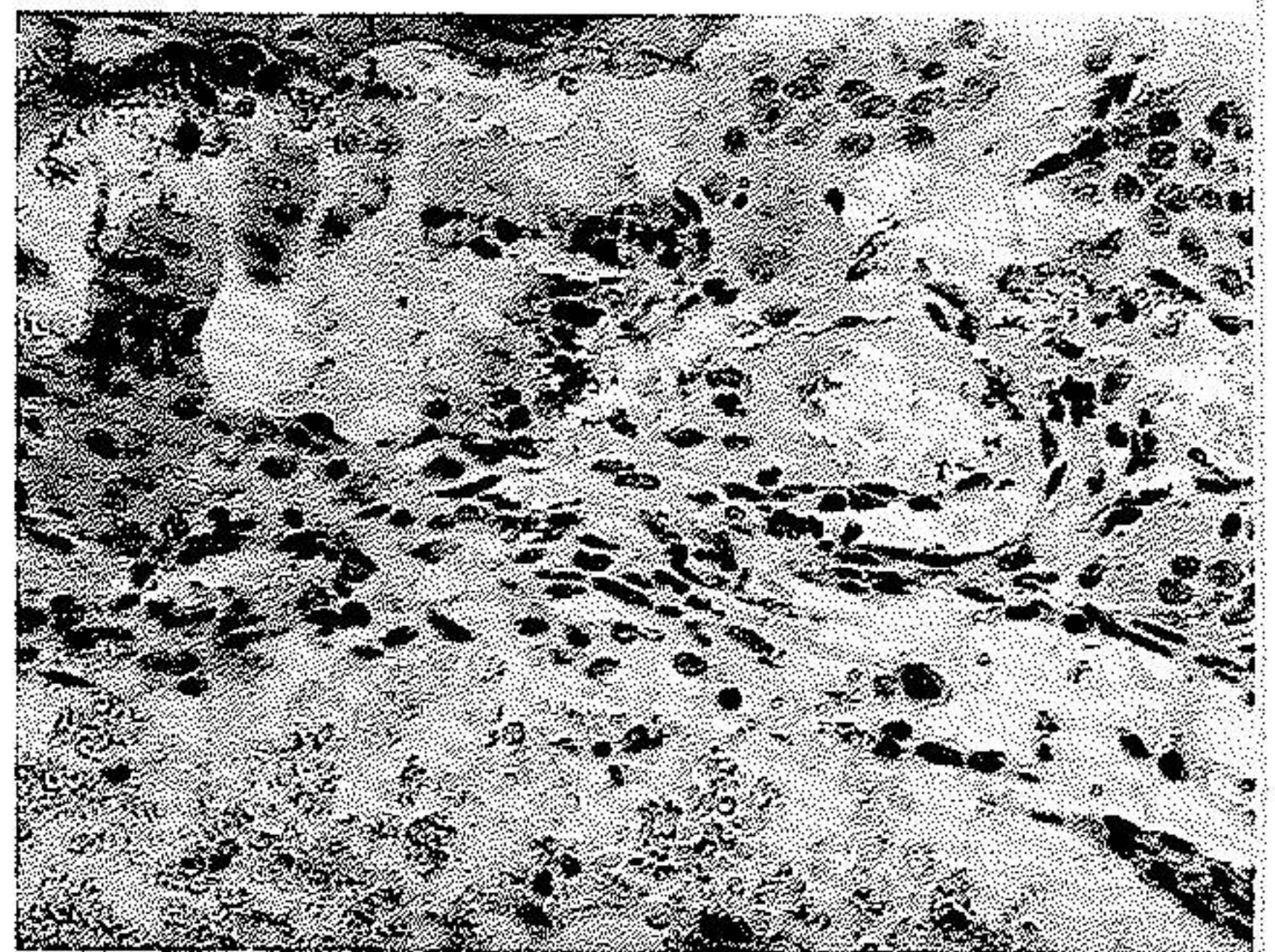
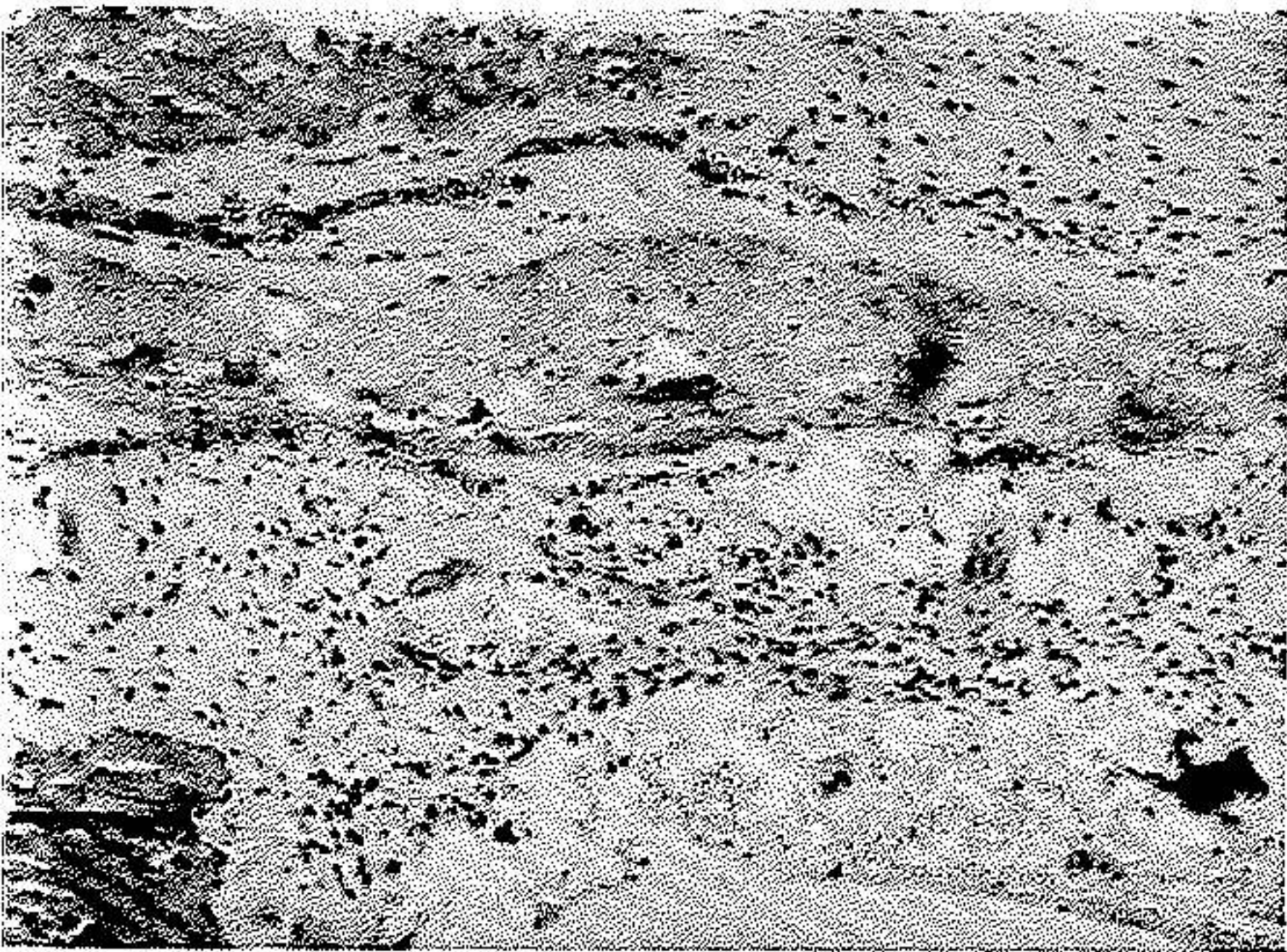
Fig. 2. Typical appearance of an aneurysmal bone cyst with fibrous tissue; septa containing giant cells and hemosiderin is noted.  
(Dr. Armin. Pathological department, Tehran medical school)

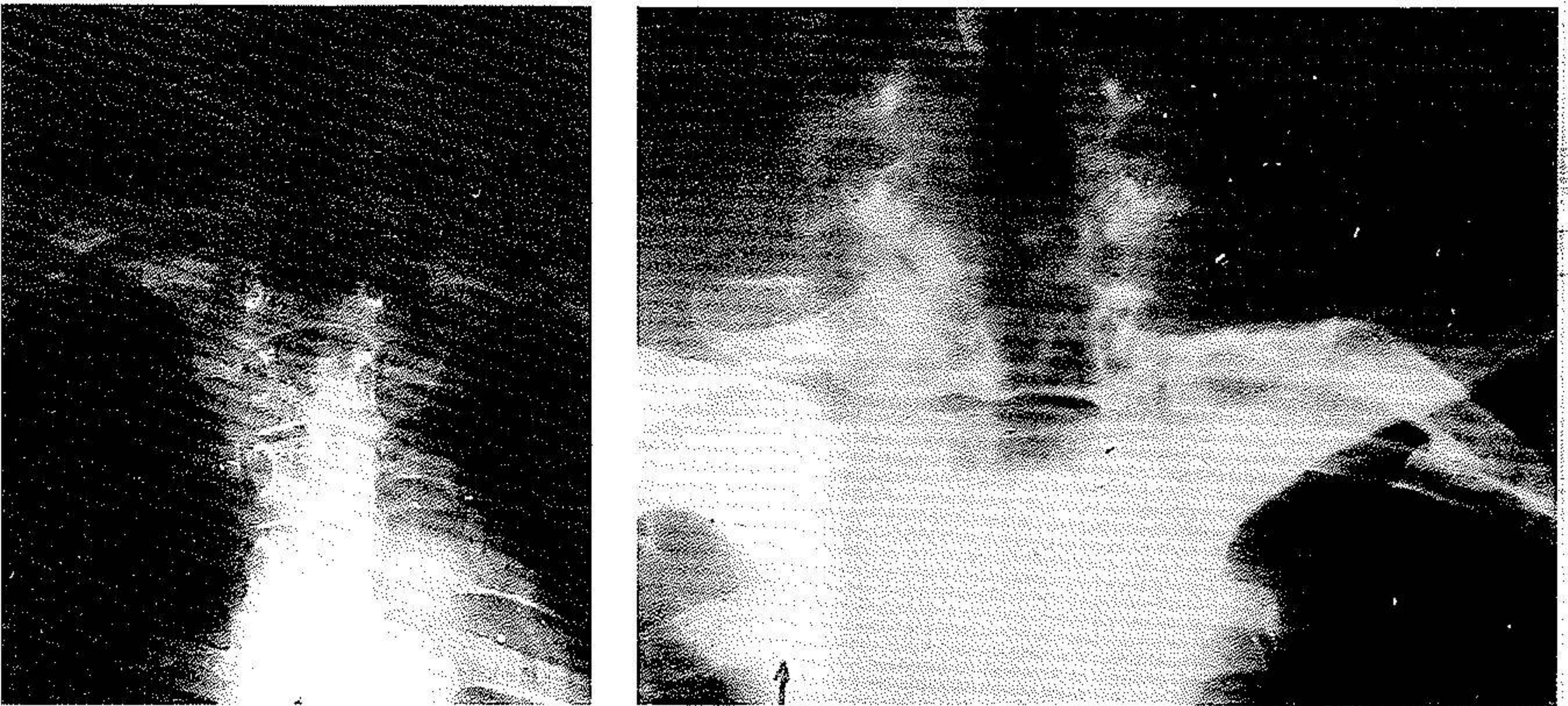


Fig. 3. (case 2). Aneurysmal bone cyst of D1. There is expansion of the body and transverse process with apparent bony septa crossing the lesion. Note "eggshell" borders of the left transverse process of D1.

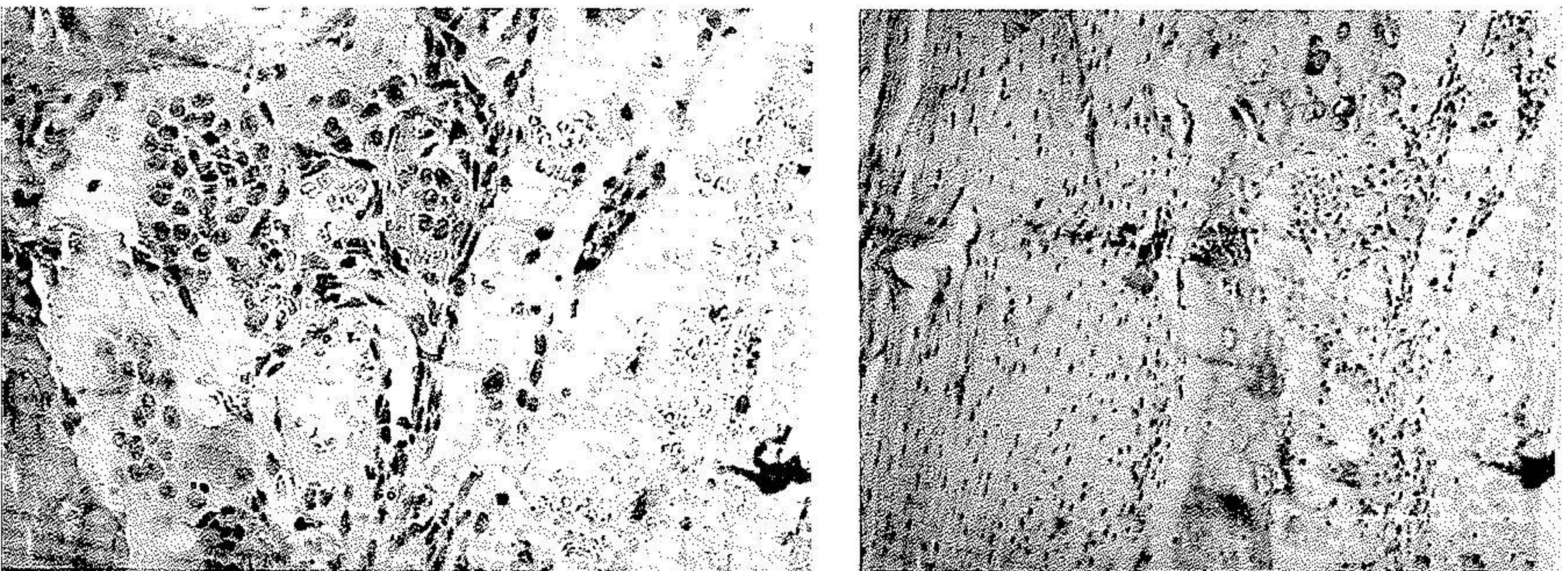


Fig. 4. The wall of the many vascular channels spaces do not contain muscle or elastic fibers. Abundant giant cells and hemosiderin noted in the fibrous tissue. This is typical for an aneurysmal bone cyst.  
(Pathology department. Tehran medical school)

### OPERATION

Because of involvement of the body and neural arch satisfactory operation was not possible and only biopsy of transverse process was carried out.

### Microscopic Examination

Typical appearance of an aneurysmal bone cyst was seen. Large vascular spaces between irregular pieces of bone (Fig. IV). Lining the cavities was loose fibroblastic tissue.

This patient was treated by radiotherapy (2000r) and after two years under observation no change was noted in the size of the lesion and no neurological disturbances seen.

### DISCUSSION

**Pathologic features:** The lesion consists of blood-filled, honeycombed spaces lined by vascular fibrous tissue. This tissue was heavily permeated with vascular capillaries and areas of free hemorrhage in various stages of organization. The vessels had no muscle in their walls and no aneurysmal changes. Frequently, numerous giant cells were located in connective tissue which possibly represented organised hemorrhage. It is these areas which cause confusion by suggesting a giant cell tumor to some histologists. (1,2,-3,8,9,10).

The cyst may cause fracture or rupture into soft tissues and hemorrhage may finally result in myositis ossificans. Histologically these lesions have been mistaken for giant cell tumor, osteosarcoma, fibrous dysplasia and myositis ossificans (8,10).

**Clinical Features:** Aneurysmal bone cyst occurs mostly in the younger age groups. The majority is seen between ten and twenty years and its incidence seems to be equal in both sexes. In most cases the first symptom reported is a bulge on the affected bone or sometimes a quickly growing tumor. There is no pulsation on palpation of the cyst. Pain is usually mild. In the spine if the cord is compressed by the cyst, neurological signs will be noted. The most severe symptoms are caused by fast growing tumors. (1,8,-9,10).

**Radiological Features:** The vertebral column is a frequent site of aneurysmal bone cyst. The neural arch appears to be the site of predilection as the lamina seems to be involved in every instance. (1,10). The lesion is usually eccentric in position, beginning as an area of rarefaction with little or no internal structure and barely discernible borders (Fig 1,III). Eventually an expanding multiloculated process is seen extending into the soft parts with "eggshell" borders. When the vertebral bodies are involved, it usually collapses sooner or later in the course of the disease. When complete collapse is occurred its roentgen diagnosis may be impossible.

**Differential diagnosis:** Aneurysmal bone cyst must be differentiated from giant-cell tumor (1,6,7,9,10). In the latter condition the trabeculation is as a rule more uniform and do not occur in children. Also giant cell tumors are extremely rare in the vertebrae, one of the favored locations for aneurysmal bone cysts. The differences in post irradiation reaction are significant. After irradiation giant cell tumor presents more marked osteolysis and the bony shell is absent and after several weeks traces of ossification becomes visible in the radiological picture. Aneurysmal bone cyst ossifies rapidly very often during radiation treatment.

**Fibrous dysplasia of bone:** Monostotic forms of bone dysplasia may sometimes resemble aneurysmal bone cyst to a great extent. In the past aneurysmal bone cyst was often misdiagnosed as fibrous dysplasia. Histological examination is necessary to establish the diagnosis. Unicameral bone cyst: Centrally situated aneurysmal bone cyst may be indistinguishable from unicameral bone cyst without surgical exploration.

Ossifying hematoma and some forms of myositis ossificans may sometimes resemble aneurysmal bone cyst. These lesions are always entirely extraosseous and a tangential radiogram may be very helpful.

Radiological appearance of cavernous hemangioma in the vertebral bodies is characteristic and well known.

Some metastatic (from renal carcinoma, Angiosarcoma or telangiectatic form of osteogenic sarcoma) may appear to resemble aneurysmal bone cyst. However malignancy is obvious in most cases.

### TREATMENT

The treatment is predominantly surgical and is aimed at exposure and eradication of the lesion by curetting supplemented by bone graft as required or possibly replacement of a vertebral body (8,9,10). When the lesion is in an inaccessible area, roentgen therapy has proved beneficial, and in some cases, produced a permanently satisfactory result.

When applying radiation therapy one should bear in mind that the shape and size of an irradiated tumor may remain unchanged after treatment. Doses should not exceed approximately 2500r. In cases in which radical removal is impossible combined resection and irradiation is indicated.

### SUMMARY

Two new cases of aneurysmal bone cyst of the spine are presented. In one of them only the spinous process was involved, and in the second case the neural arch and the body were involved.

A brief review of the literature with clinical, radiological and pathological features of this benign lesion is made and its differential diagnosis, specially from giant cell tumor of the spine emphasised.

### RESUME

Deux nouveaux cas de kystes aneurysmaux du rachis sont présentés dont l'un localisé uniquement sur l'apophyse épineuse et l'autre sur l'arc neural et le corps vertébrale.

Les auteurs ont fait une revue de la littérature sur le plan clinique, pathologique et radiologique de ces genres de lésion avec une part importante sur le diagnostic radiologique différentiel et le traitement de ces affections bénignes.



---

**References**

- 1- Clough J.R., et al (1958). Aneurysmal bone cyst. Review of twelve cases. *J. Bone and joint surg.* 50:116-127.
- 2- Arvin ei. Robinson, M.D., Raymond I. Thomas, M.D. and Donald M. Monson, M.D. (1967). Aneurysmal bone cyst of the rib. A report of two unusual cases. *Brit. J. of roentgenology* 526-529.
- 3- Bruscoel P. et al. (1967) Observation of an unusual location of an aneurysmal cyst at the sacrum- 23: 71-86.
- 4- Nobler M.D., et al. (1968). The cure of aneurysmal bone cyst. Irradiation superior to surgery in an analysis of 33 cases.
- 5- Roy E. Buck, M.D. and Robert W. Bailly, M.D. Ann Arbor, Michigan *J. bone and joint surg.*, 51A: 1956-1959-1960.
- 6- Hess, W.E. (1960) Giant-cell tumor of the cervical spine. A case report *J. Bone and joint surg.* 42 A: 480-484.
- 7- Fitzpatrick, H.F. Bossart, P.A. A.M.A (1964) Aneurysmal bone cyst of rib; differential diagnosis and treatment.
- 8- A. Modjtabai, S. Sarkisian, H. Saleh (1966). Aneurysmal bone cyst (Report of four cases). *Acta medica Iranica* 9: 719.
- 9- G. Serrtrice et J. Legré (1957). Kystes anevrysmaux ou tumor a myeloplaxes du rachis? *J. de radiologie d'electrologie et médecine nucléaire* 40 No II Nov. 713-717.
- 10- Jack Edeiken, M.D. J. Hodes M.D. (1967). *Diagnosis of diseases of bone* 541, 588. The Williams & Wilkins Co. Baltimore.