

Pulmonary Lobectomy in Haemophilia

I. Shoai^{*}, D. Kazemi^{**}, F. Ala^{*}

We present below the first documented case of major thoracic surgery in a patient affected by haemophilia.

Surgery in patients with congenital haemostatic defects, more particularly Haemophilia and Christmas Disease, has become increasingly widespread and adventurous in recent years. Greater experience and closer teamwork between surgeon, physician and laboratory consultant account for a major part of the relative safety of surgical intervention in these cases. The greatest credit, however, must go to the wider spectrum of specific plasma fractions available to the clinician, and their greater potency. The valuable experience of pioneers in this field has sophisticated the utilization and control of this replacement therapy so that trauma or surgery, which would have been irrevocably fatal only ten years ago can be managed with a success beyond the wildest hopes of Rasputin's fevered imagination.

* Tehran University, Haematology Department, Pahlavi Medical Centre.

** Professor of Surgery, Tehran University.

The central problem presented by the post-operative or the injured haemophilic is replacement of the deficient coagulation factor, and this involves the infusion of materials containing antihemophilic globulin (AHG). Treatment is limited by the maximum volume of intravenous fluid which can be tolerated; by the limited supply of these costly materials; and by the risk of developing inhibitors or in-activators of AHG, particularly after administering animal concentrates which provoke the formation of antibodies.

In covering major surgery, fresh plasma alone, even at the maximal tolerable doses of 20 mls. per kilogram body weight, cannot provide a sufficiently favourable AHG activity/volume ratio to prevent haemorrhage. Even then, sustained treatment with these quantities of plasma will usually cause hypervolaemia unless intensive diuretic therapy is concomitantly instituted.

Concentrated AHG can be prepared by alcohol, ether, amino-acid or cryo-precipitation, which is many times more potent, volume per volume, than plasma. The advantage of preparations of human concentrates is that they are not allergenic, and resistance to human AHG does not occur as it does with animal preparations. Human fractions are expensive, however, and animal AHG has the advantage of being approximately ten times more potent than many human concentrates. These animal fractions are, therefore, most suited for emergencies such as very severe injuries or those rare cases where a potent anti-Factor VIII has developed in a haemophilic. For more ordinary cases, great care must be exercised in the use of animal AHG since severe anaphylaxis or renal damage with nephrotic syndrome may develop in some instances.

Materials & Methods

Laboratory reagents and methods employed were those of Biggs and Macfarlane (1). Porcine AHG standard for their two-stage Factor VIII assay and Factor VIII Inhibitor Assay, as well as the required Bovine Factor V, were obtained from Diagnostic Reagents Ltd., Thame, Oxon, England. Phospholipid was provided as Cephaloplastin, by Dade Reagents Ltd. Euglobulin Lysis was by the method of Buckell (2).

Blood for assays was drawn into 3.8 % trisodium citrate (9:1), using siliconized glassware. Post-operative assays of Factor VIII were carried out on plasma drawn immediately before, and ten minutes after the termination of AHG infusions in all cases. The actual determinations were carried out the same day and in duplicate.

Porcine and Bovine Antihaemophilic Globulin were obtained from Maw's Ltd., Barnet, Herts, England.

Cryoprecipitated AHG was prepared by the method of Pool and Shannon (3), with the single modification that a rapid thaw method at 10 degrees C. was employed in place of the 4 degree thaw advised in the original method. This modification resulted in a better yield of antihaemophilic activity.

CASE HISTORY

I.H., aged 25 years, when first seen in 1966, is a haemophilic affected with moderate severity (Factor VIII level 2.5 %). He gave a 3-year history of recurrent and increasingly severe episodes of haemoptysis, accompanied by periods of pyrexia. The radiological changes accompanying one of these episodes of particularly severe haemoptysis, are illustrated in (Figure 1). Investigations aimed at excluding hydatid infestations (Casoni testing on several occasions), were inconclusive at the time.

When first seen at the Haematology Department, Pahlavi Hospital, the patient was enjoying a period of relatively good health. There was no family history of abnormal bleeding; indeed, the patient himself did not admit to anything but the mildest haemorrhagic tendency following trauma. It was

noted that the blood eosinophil count was strikingly elevated, and tomography of the left lung field demonstrated a rounded opacity in the lower zone, but no evidence of calcification. This lesion was taken as presumptive evidence of a hydatid cyst, particularly since the patient later admitted that his dog had made a habit of sharing his bed for the past eight years!

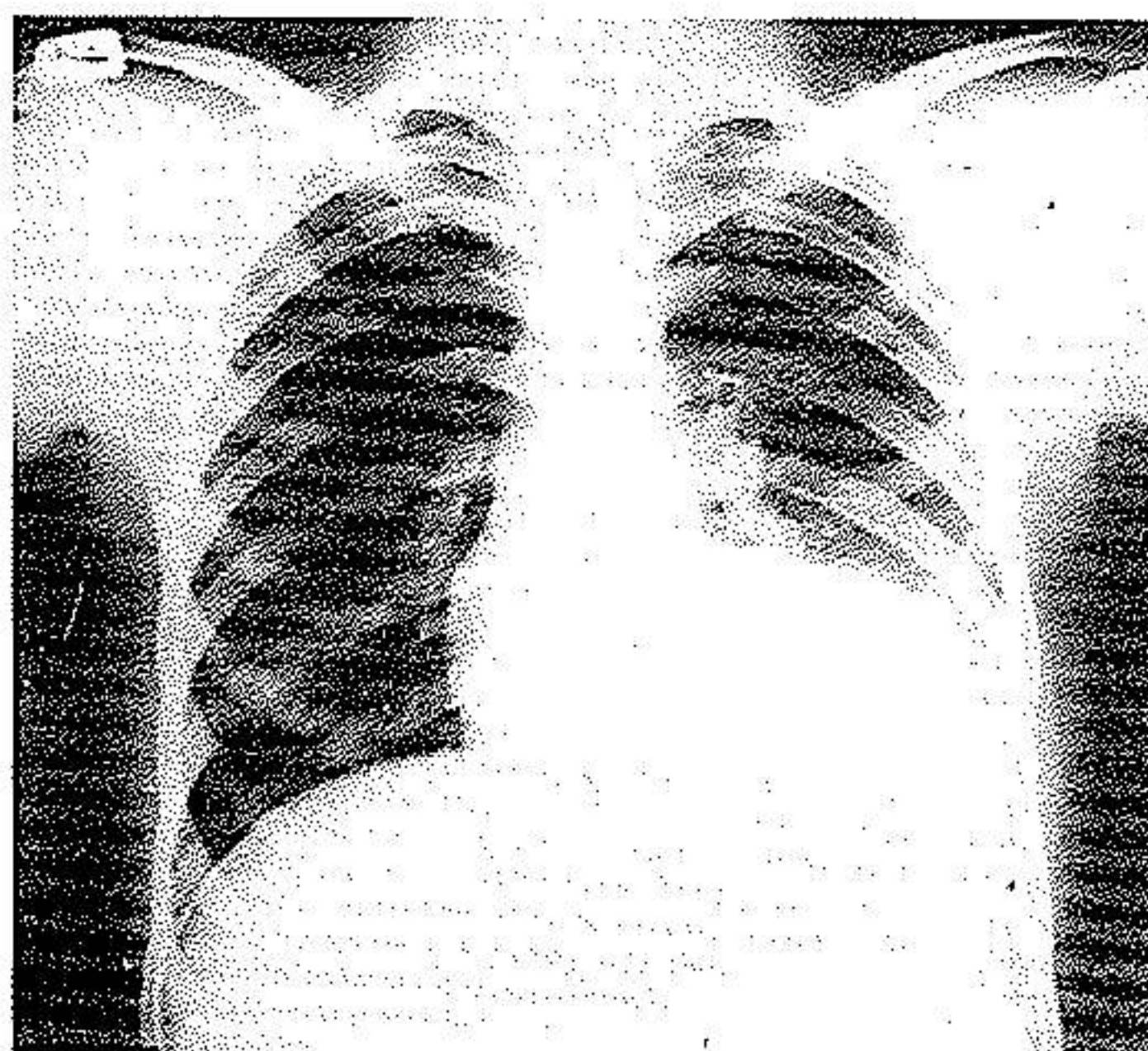


Fig. 1. Chest film taken pre operatively during an acute exacerbation of haemorrhage.

Apart from brief and widely separated episodes of haemoptysis treated with infusions of fresh-frozen plasma, a relatively quiescent 2-year period followed. In 1968, however, he was readmitted to the Haematology Unit with a severe exacerbation of pulmonary haemorrhage, requiring the transfusion of four units of whole blood. On this occasion, several complete "daughter cysts" were coughed up with considerable effort and distress, and the diagnosis of hydatid disease was incontrovertibly established.

Haemorrhage continued unabated, and at this stage, it was considered that surgical intervention was mandatory. Accordingly, on 5.3.68, thoracotomy and exploration of the left chest cavity were carried out by Dr. D. Kazemi (anaesthesia was managed by Dr. Oskou'i), under cover of 4000 Units of Porcine AHG. The Factor VIII level rose to 100%. A large, unilocular hydatid cyst was found occupying the greater portion of the left lower lobe, with much surrounding fibrosis. Since little normal lung tissue remained, it was decided that a total lobectomy should be carried out. The

operation was terminated uneventfully and the patient was transferred to the Haematology Unit immediately after recovering from anaesthesia. Four hours later, 2 litres of blood had drained from the intrathoracic tube and the pulse became thready and rapid. Five units of whole blood were transfused but the patient's condition continued to deteriorate as haemorrhage persisted. Eight hours after operation, a further 4000 Units of Porcine AHG were rapidly administered. Blood loss from the intrathoracic drain ceased almost immediately and the signs of hypovolaemia were progressively abolished by the subsequent infusion of eight more units of blood.

Twice daily or daily infusions of Porcine AHG were continued in doses and at intervals dictated by the Factor VIII levels, monitored before and after every infusion (Figure 2). Such was the anxiety caused by the patient's immediate post-operative condition, and in view of the theoretical consideration that the release of Tissue Activator from lung trauma might cause abnormal fibrinolysis and further haemorrhage, that it was decided that Epsilon Amino Caproic Acid would be administered (2.1 G. per kg.) intravenously every day. It should be noted, however, that no laboratory evidence of pathological fibrinolysis was obtained at any time.

After this stormy beginning, the patient's subsequent progress was relatively smooth, but on the 7th post-operative day, the patient's poor response to Porcine AHG clearly indicated that resistance was developing towards this material. The following day, pre-infusion levels of Factor VIII were below 20 % and a large dose of over 40 Units per kilogram of Porcine AHG produced almost no elevation of the plasma Factor VIII activity. The Bovine Fraction was accordingly substituted, with good effect, and continued for eleven days. Plasma infusions (at a dose of 15 mls. per kg.) were continued twice daily for a further week and substitution therapy was discontinued thereafter.

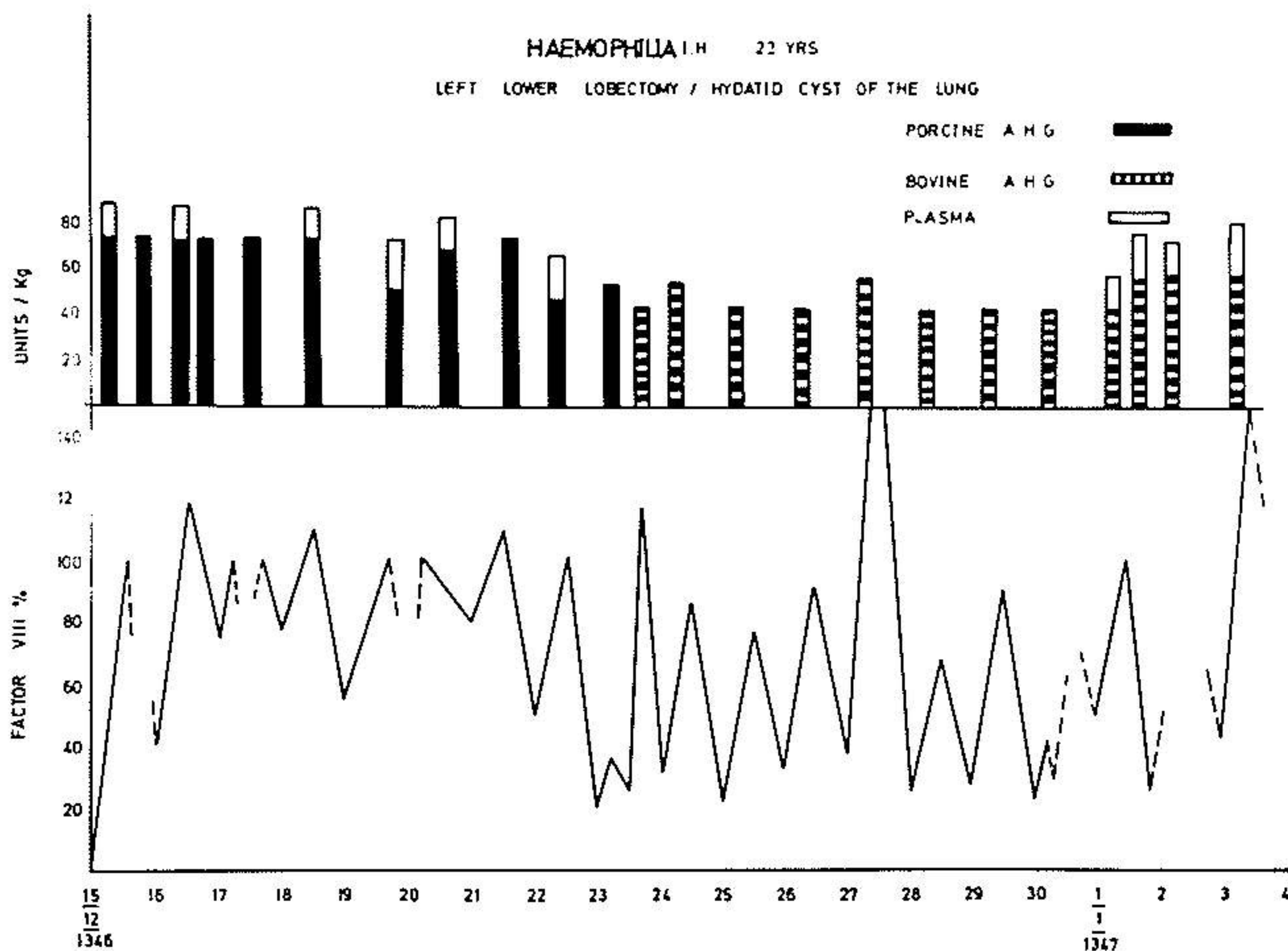


Fig. 2. Factor VIII assays estimated during post operative period and schematically showing treatment administered.

A haemopneumothorax and wound haematoma complicated the recovery period, but these gradually resolved and the patient made steady progress towards a complete recovery. Cloxacillin and Ampicillin (1.5 G. of each daily) were given for two weeks from the day of operation, and no evidence of infection was manifested at any time. Repeated Factor VIII-Inhibitor assays were negative throughout and at no time was there any evidence of pathological fibrinolysis.

Minor haemoptyes recurred some 2 months after the operation. A bronchogram showed that the left lower lobe bronchus stump was sound (Figure 3) and this recrudescence of blood stained sputum remained a transient and unexplained phenomenon. At follow-up, the patient has been entirely well, although organization and fibrosis of the intrathoracic blood effusion have caused some mediastinal and chest wall deformity. We feel that this may have been due to our use of anti-fibrinolytic drugs.

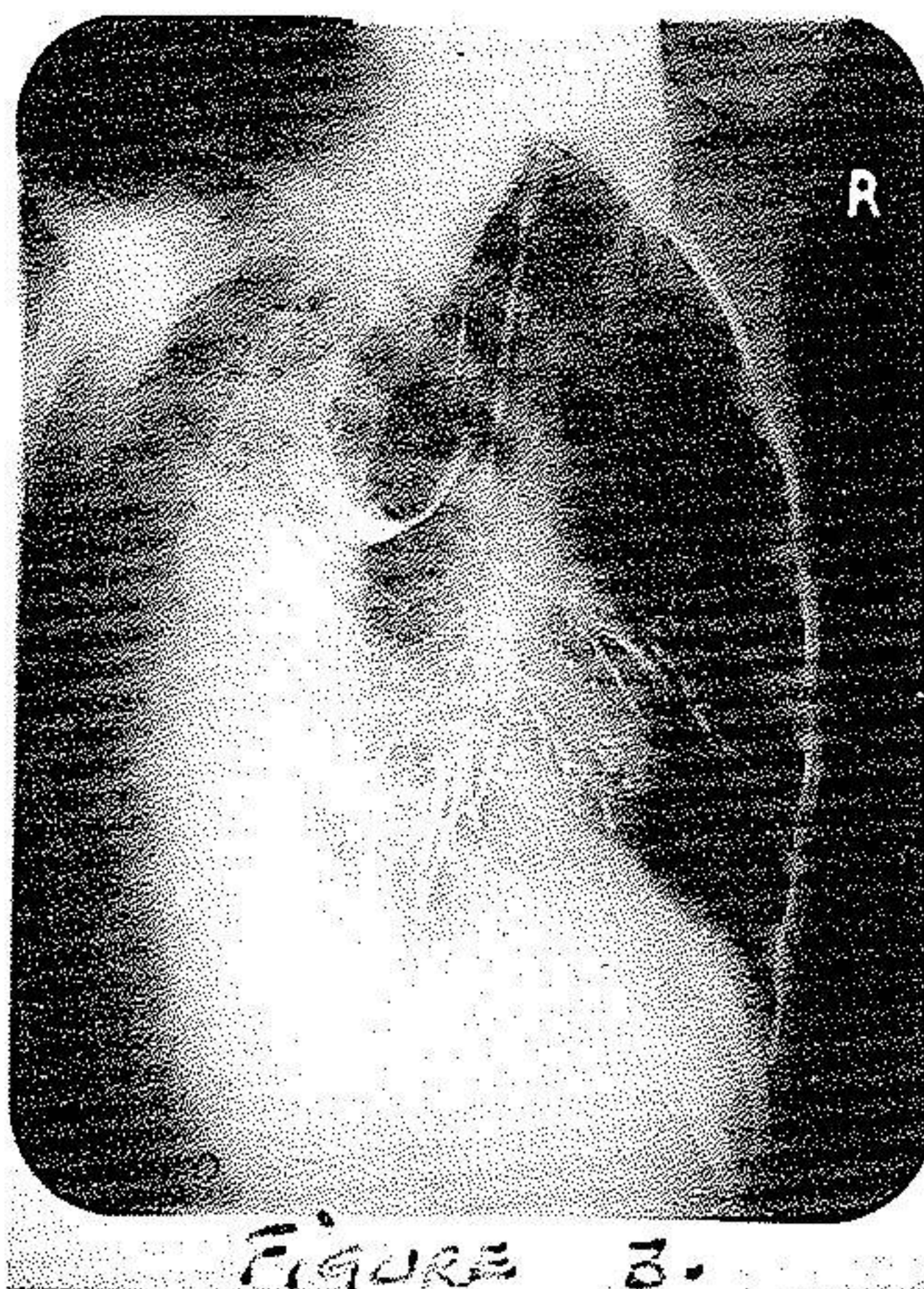


Fig. 3. Post operative bronchogram showing integrity of bronchiae stump.

CONCLUSION

It is clearly demonstrated that the control of haemophilic bleeding requires constant attention to the levels of plasma Factor VIII. Differences in AHG consumption may be quite marked and different individuals respond differently to a given dose of Fraction. Errors in judgement in this respect are paid for heavily, and even a transient insufficiency of Factor VIII may cause haematomas, wound disruption and infection which vitiate or delay healing and may indeed prove fatal. Thus, meticulous attention to detail and the close cooperation of a team are required to ensure success.

The use of antifibrinolytic drugs in a wide variety of haemorrhagic conditions, is enjoying quite a vogue at the present. These drugs are used for haemophilic haemarthroses, haematuria, and mucosal bleeding, particularly after tooth extractions. It is our feeling that these drugs are of great value in reducing or stopping bleeding from the gums, the nose and per vaginam (in those with von Willebrand's disease). In tooth extraction EACA

will greatly reduce the patient's AHG requirements. On the other hand, we strongly feel that these drugs should not be used in cases where bleeding has occurred into a closed space, such as the joints, the urinary tract or the thoracic cavity. Although bleeding may be stopped, in these situations, we feel that interference with the fibrinolytic mechanism impairs the natural "clearance" mechanism whereby blood is removed from these body spaces; that organization and subsequent fibrosis of the clot occurs which may well cause organ dysfunction and deformity. With regard to the kidney, it may be that prolonged prospective studies will show slight but progressive impairment of renal function in those who have been regularly treated with anti-fibrinolysis. In retrospect we feel that we should not have used EACA in our patient for these very reasons.

SUMMARY

An account of the management of a haemophilic patient is presented who developed severe, prolonged haemoptyses caused by hydatid lung disease, and who ultimately required thoracotomy and lobectomy of the lungs.

RÉSUMÉ

Un cas d'hémophilie est présenté où le malade souffrait d'hémoptyses très sévères provoquées par la présence d'un kyste hydatique du poumon gauche. Telle fût la gravité de l'hémorragie qu'une intervention chirurgicale avec une lobéctomie du poumon droit fût indispensable. Les soins pré et post opératoires suivent dans ce cas, peu commun, son brièvement décrits.

References

- 1) Biggs, R., and Macfarlane, R. G., (1966). Treatment of Haemophilia and other coagulation disorders. P. 337, 2nd Ed., Blackwell Publication Co., Oxford.
- 2) Buckell, M., (1958). The effect of citrate on euglobulin methods of estimating fibrinolytic activity. J. Clin. Path. 11: 403.
- 3) Pool, J. G., Shannon, A., (1965). Production of high-potency concentrates of anti-haemophilic globulin in a closed bag system. New Eng. J. Med. 273: 1443.