

## Bilateral Stenosis of the internal carotid artery, associated with aneurysm of the basilar trunk.

A.A. MORSHED, M.D.

Internal carotid artery stenosis in upper cervical, were seen more often on one side, but bilaterally is exceptionally rare.

D. Michel in Jan. 1971 has reported (1) "A series of 11 cases of bilateral thrombosis of the internal carotid artery."

G. Martinelli in Nov. 1968 reported (2) a case of thrombosis of the internal carotid artery in one side and aneurysm of the basilar trunk.

This patient presents bilateral thrombosis of the internal carotid artery associated with aneurysm of the basilar trunk.

**Case Report:** On February 15, 1974, a 31-year-old right handed unmarried woman with a congenital left hemiparesis and no history of epileptic fits or subarachnoid hemorrhage developed a sudden headache with vomiting, and soon after she was admitted to the hospital.

On examination, she was drowsy, restless, lethargic and irritable.

Examination of the cranial nerves were normal. The blood pressure was 120/75 mm Hg. Blood tests and urinalysis were within normal limits. Her left visual field has been narrowed. The lumbar puncture revealed uniform bloody cerebro-spinal fluid (C.S.F.). X-ray of the skull was normal. A carotid angiography was attempted on both sides, which showed bilateral thrombosis of the internal carotid artery (Fig. 1-2). A catheter was introduced through the femoral artery into the aortic arch and cerebral angiography carried out which confirmed obliteration of both internal carotids with aneurysm of the basilar trunk (Fig. 3).



No treatment was contemplated. She gradually recovered, and left the hospital following a month's rest with good general condition and no sequelae.

Our patient has 2 brothers and one sister. The eldest is a man of 34, with a height of 150 cm; and cleft lip which was repaired. The other brother is 28 with a height of 125 cm, who is very nervous. The sister is 25 years of age with medium height and quite normal. Our patient had congenital left sided hemiplegia which improved gradually by physiotherapy. She can walk normally, but her hand is atrophic and useless. Her historical background shows nervousness, hysteria and anxiousness. Before this hemorrhage, the patient was normal and after a long hot-bath the onset occurred.

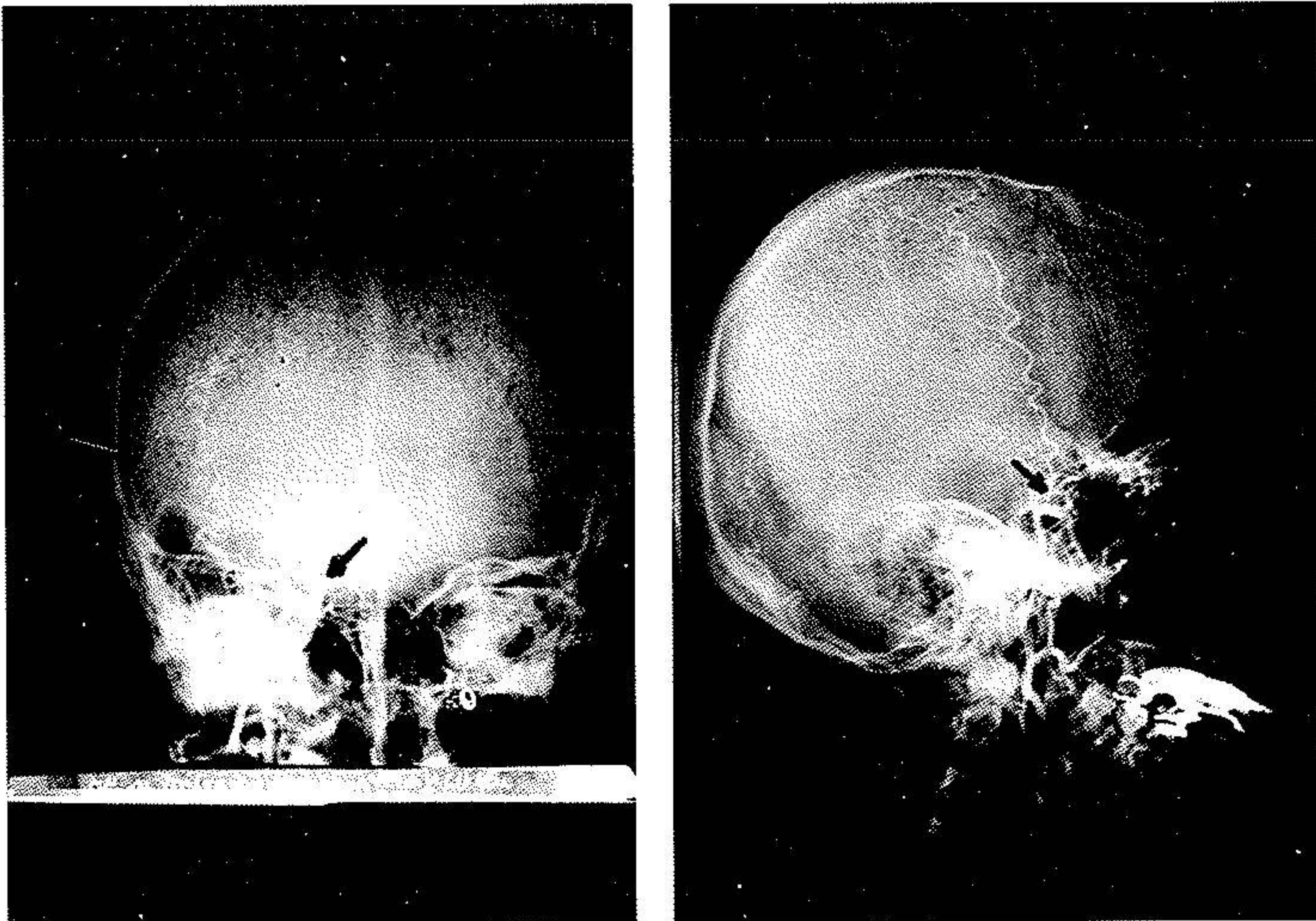


Fig. 1 (A.P., Lateral): Left carotid thrombosis.



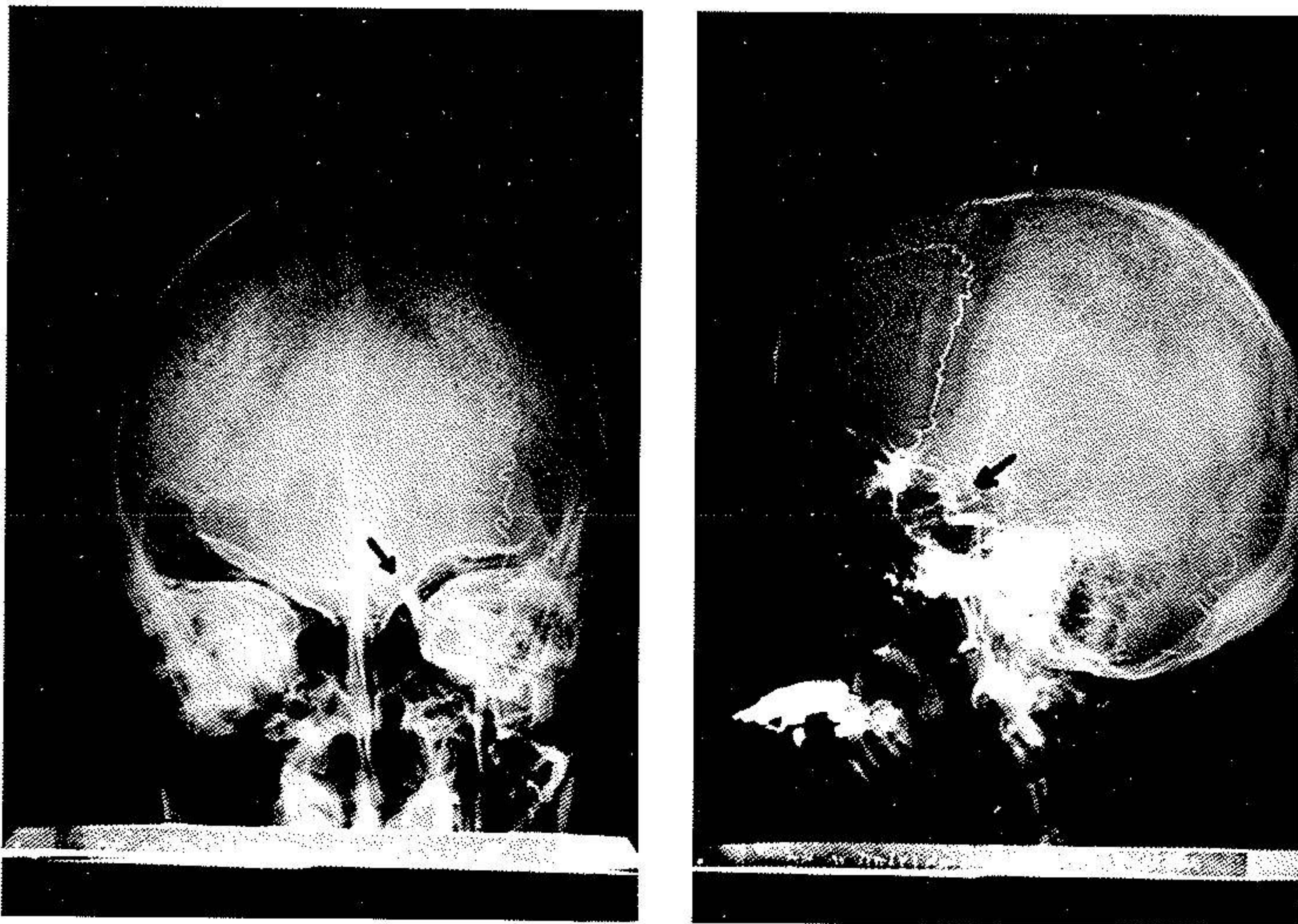


Fig. 2 (A.P., Lateral): Right carotid thrombosis.



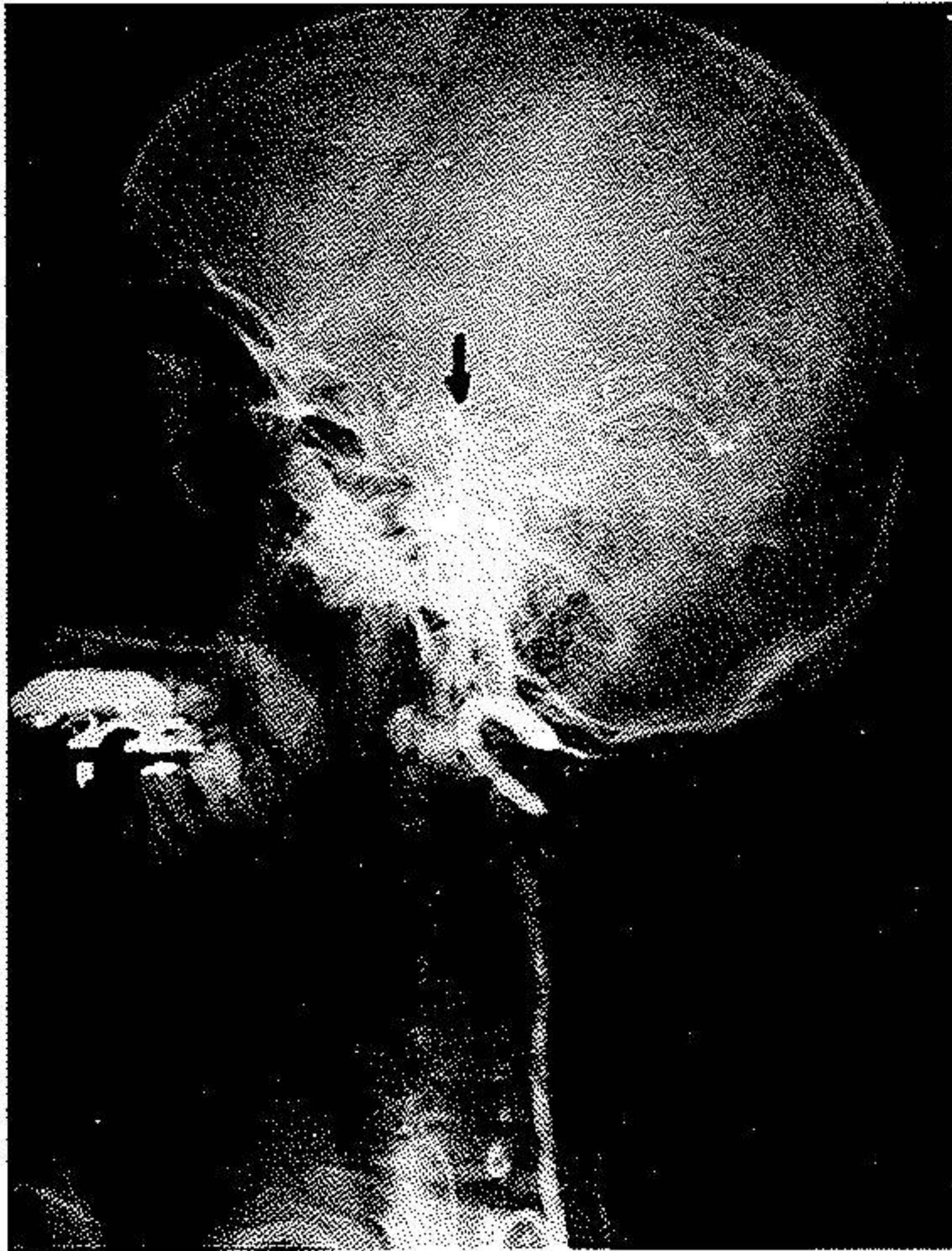


Fig. 3: Bilateral carotid thrombosis with aneurysm of the basilar trunk.

### DISCUSSION

Reviewing the literature, only one case with stenosis in one side of internal carotid artery and aneurysm on the basilar system is reported.

Considering the family and her own congenital deformity, we can assume the fact that stenosis of both internal carotids and aneurysm on the basilar system is a congenital deformity.

Definitely, in this case any surgical intervention seemed impossible and dangerous.

Reviewing the literature, similar case has not been reported.

D. Michel reported 11 cases of bilateral thrombosis of the internal carotid with no aneurysm in basilar trunk. The via femoral angiography is a better mean of demonstrating thrombosis of the internal carotids and in the meantime the vertebral artery and basilar trunk.

### SUMMARY

- 1) A case of bilateral stenosis of the internal carotid artery with aneurysm of basilar trunk is reported.
- 2) Via femoral angiography confirmed the diagnosis which is strongly recommended in diagnosing such cases.
- 3) No surgical treatment is considered.
- 4) No similar case has been reported in literature.

### RESUME

- 1) Un cas de stenosis bilateral de l'artère carotide interne avec anéurisme du tronc basillaire est rapporté.
- 2) L'angiographie par voie l'artère femorale est vivement conseillée pour confirmer ce diagnostique.
- 3) Nous ne conseillons aucun traitement chirurgical.
- 4) Aucun cas analogue n'a été rapporté dans la littérature.

### REFERENCES

1. A series of 11 cases of bilateral stenosis of the internal carotid artery. Discussion about the aspect of bilateral hypoplasia of the internal carotid arteries in 3 cases, Michel D., et al. *J Med Lyon* 52:5-61, Jan. 71 (Eng. Abstr.) (Fre).
2. Thrombosis of the internal carotid associated with aneurysm of the basilar trunk. Martignelli G., et al. *Nunt Radiol* 34: 1241-50, Nov. 68 (Ita).
3. Thrombosis of internal artery following injuries of head and neck. Mazurowski W. *Pol Przegl Chir* 41: 1706-10. Dec. 69.