

## SUPERNUMERARY NIPPLE

### First case report in Iran

B.V.Seyedi, M.D.      A. Mohabat-Ayin, M.D.

Supernumerary nipple, although a common occurrence, but there are few reports in the literature.

This is the first reported case in Iran, well documented by clinical observation as well as histological studies.

#### CASE REPORT

The patient, a 22 year-old married female, had noticed, since early childhood, an asymptomatic growth on the right side of her abdominal wall (Fig. 1).

During her pregnancy, two years ago, it showed slight swelling and a few drops of milky fluid were excreted by this extra nipple.

The diameter of this nipple was 0.5 cm. and increased to a height of 1 cm. after manipulation. a small central hole was visible, but no obvious areola or hairs could be detected. The remainder of the physical examination was normal.

The following laboratory tests were normal: complete blood count, sedimentation rate, fasting blood sugar, elec-

---

Associate professor of dermatology, Razi Medical School, Tehran University Professor of Pathology, Razi Medical School, Tehran University.

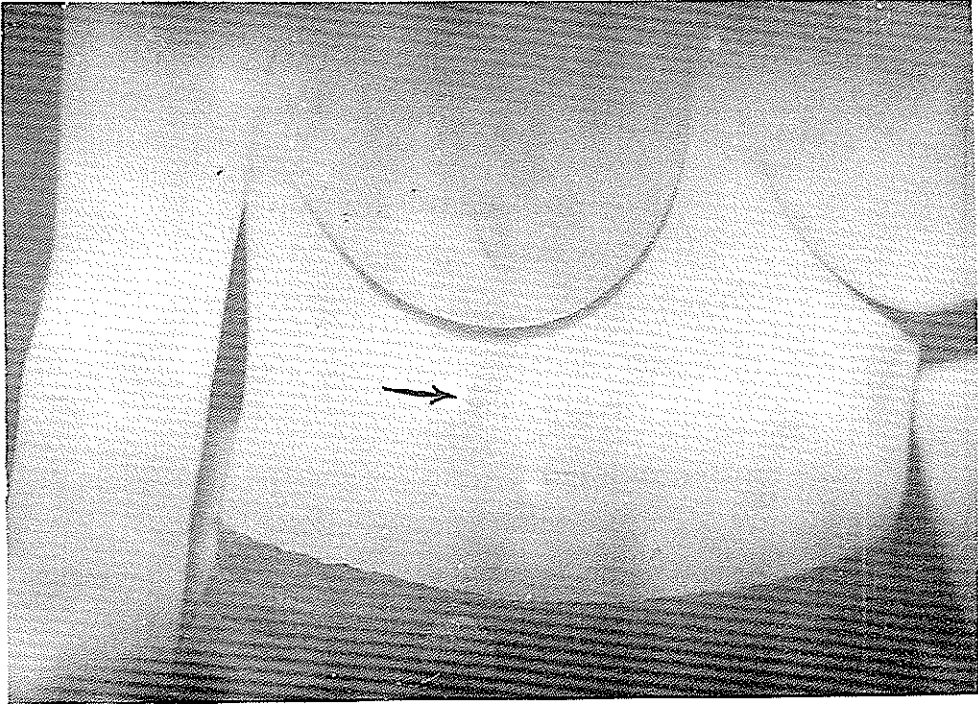


Fig. 1 :Clinical appearance of the lesion; it is indicated by arrow.

trolytes, blood urea and total proteins. Family history was irrelevant. The lesion was completely excised. (Fig.2).

The histological study confirmed the clinical diagnosis of super numerary nipple. The section showed a tumour covered with normal epidermis and consisted mainly of fibrous tissue with a few smooth muscle bundles. In the mid dermis two structures suggestive of mammary ducts are visible. In the deeper parts some dermal appendages such as sebaceous glands and sweat glands are detectable. (Fig. 3,4,5,6).

Special staining by Van Gieson and Masson's trichrome revealed the nature of the smooth muscle bundles seen in the tissue.

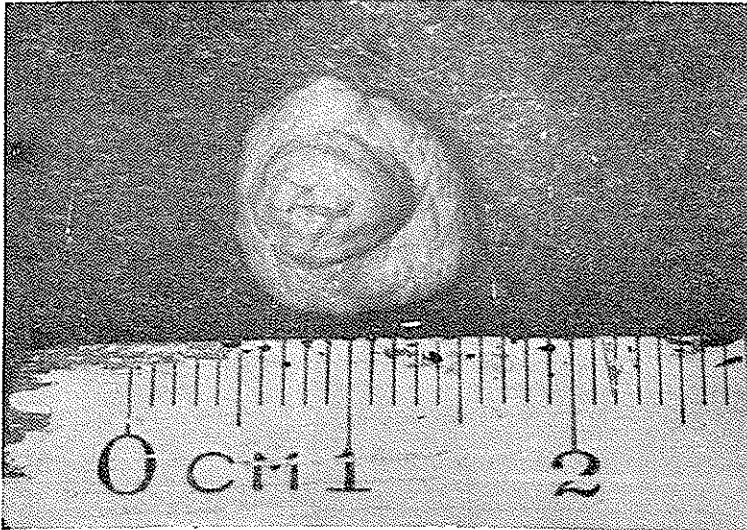


Fig. 2 : Gross appearance after total excision.  
at bottom on left side.

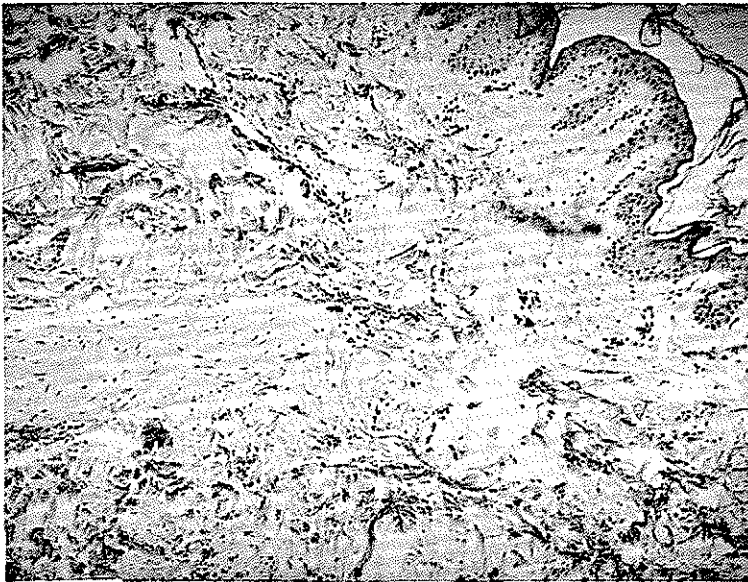

Fig. 3 : The covering skin on the upper right ,  
and some smooth muscle

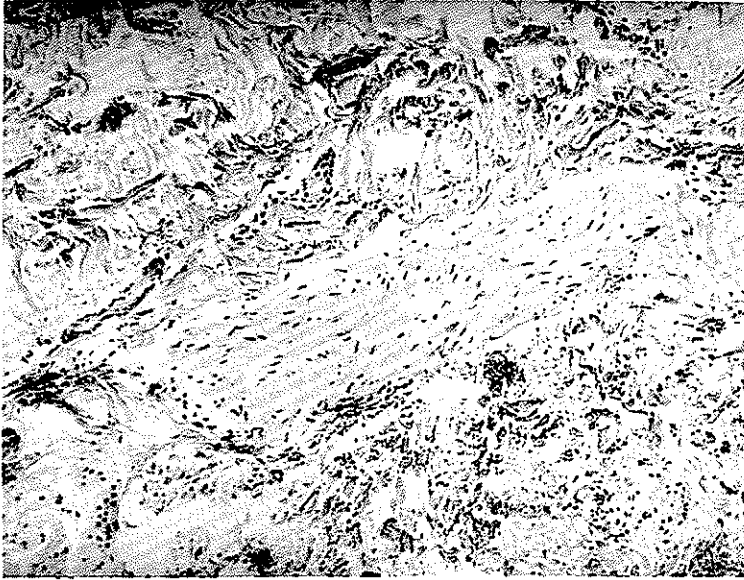


Fig. 4 : The smooth muscle bundles :  
Medium magnification.

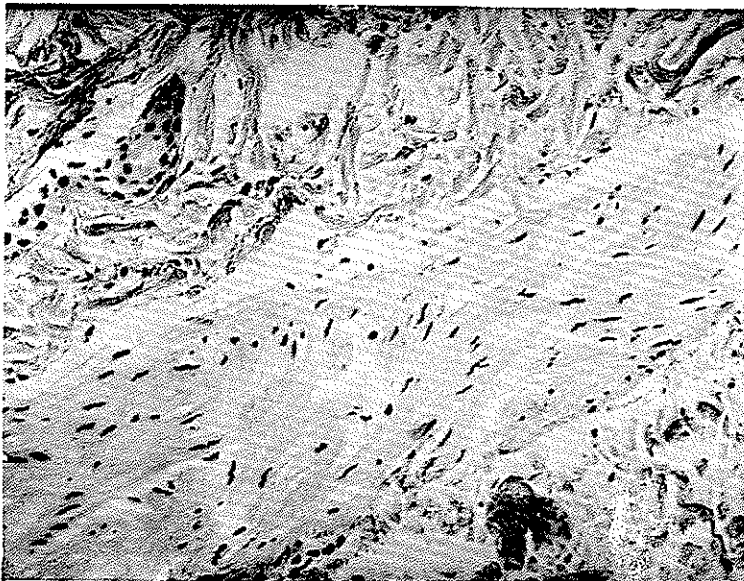

Fig. 5 : Higher magnification of smooth muscle  
fibres. Note elongated nuclei, several with  
blunt edges.

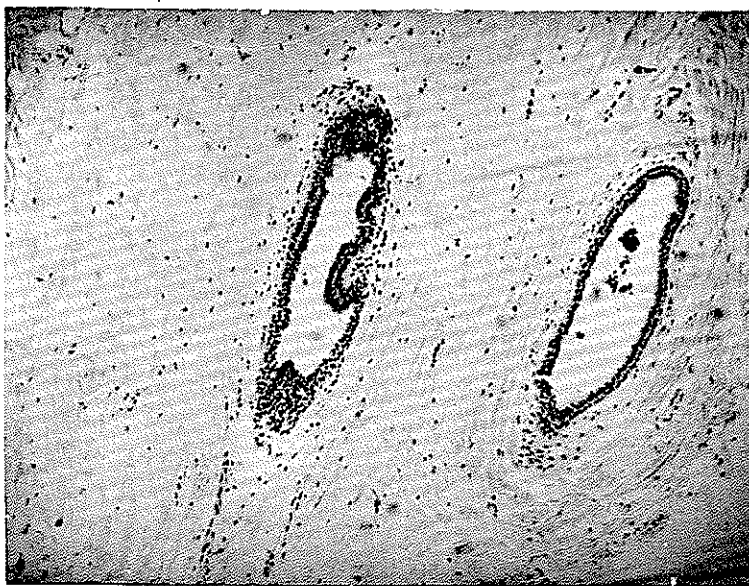

Fig. 6 : Two structures suggestive of mammary ducts.

#### Commentary

The first case of supernumerary nipple in Iran is reported and the literature is reviewed with following conclusions;

1 - Supernumerary nipple is a common occurrence but there are few reports in the literature.

2 - It can develop anywhere along the line, rarely other parts of body, and it is classified into eight categories.

3 - As accessory nipple may undergo malignant changes, such growths should be kept under observation or, preferably, be excised.

4 - It may be associated with other anomalies such as cardiovascular diseases.

5 - In some cases there is a hereditary predisposition.

**NOTE :** Polymastia is supernumerary breast; polythelia is supernumerary nipple.

---

### Reference

1. Becker RF, Wilson JW., Gehweiler JH; *The anatomical Basis of Medical Practice*, Williams & Wilkins, Baltimor, 434, 1971.
2. Czernicka H : *Wielobrodakowatosc (polythelia) a choroby ukladu Krazenia*, *Pol Tyg Lek* 19 : 1232 , 1964.
3. Ewans W : *Polythelia in cardio-arterial disease*. *Brit. Heart J* 21 : 130 , 1959.
4. Greer KE: *Accessory axillary breast tissue*. *Arch Derm* 109: 88 1974.
5. Guest EM: *Polythelia*. *Brit Med J* 2: 85, 1923.
6. Kajava Y, quoted by Brightmore T : *Bilateral double nipples*. *Brit. J Surg* 59: 55, 1972.
7. Klinkerfuss GH : *Four generations of polymastia*. *JAMA* 82 : 1247 , 1924.
8. Miriam Schewach-Millet , Fisher BK : *Cutis* 17 : 384, 1976.
9. Rook A, Wilkinson Ds , Ebling FJG: "*Textbook of Dermatology*" ed. 2, P. 1743, London, Blackwell Scientific Pub. , 1972
10. Tow SH, Shanmuggaratnam K: *Br. Med. J* II, 1236, 1962