

Benign Duodenocolic Fistula: a Case Report

Marzieh Soheili¹, Shirin Honarmand², Heshmatollah Soleimani³, and Anvar Elyasi³

¹ School of Medicine, Kermanshah University of Medical Sciences, Kermanshah, Iran

² Department of Medicine, School of Medicine, Kurdistan University of Medical Sciences, Kurdistan, Iran

³ Department of Surgery, School of Medicine, Kermanshah University of Medical Sciences, Kermanshah, Iran

Received: 3 Sep. 2013; Accepted: 22 Oct. 2014

Abstract- Benign duodenocolic fistula (DCF), known as a fistula between the duodenum and colon with or without cecum of nonmalignant origin, is an unusual complication of different gastrointestinal diseases. The present paper records a case in which the patient presented with chronic diarrhea, abdominal pain, weight loss as well as having a history of gastric ulcer. Most frequently the condition presents with signs of malabsorption such as weight loss and diarrhea, but other symptoms include nausea, vomiting (sometimes with fecal), and abdominal pain. Gastrointestinal inflammatory conditions are the usual causes. The most common ones are perforated duodenal ulcer and Crohn's disease. Barium enemas are usually diagnostic. Treatment consists of excising the fistula and repairing the duodenal and colonic defects. Closure of the fistula provides quick relief.

© 2015 Tehran University of Medical Sciences. All rights reserved.

Acta Med Iran 2015;53(8):512-515.

Keywords: Benign; Duodenocolic Fistula; Enterolysis

Case Report

A 60-year-old man was admitted to the surgery department. He was suffering from severe watery, non-bloody diarrhea from 8 months ago. He was complaining of tenesmus, nausea, and vomiting, decreased appetite, weight loss and abdominal pain which were relieved by defecation. There was not any complaint of constipation. He had a history of gastric ulcer operation fifteen years ago. The documents of his surgical procedure were not available. Also, he had a positive history of smoking (12pcs/year) and opium use with negative history of medication.

His general appearance was investigative of cachexia with no icterus. His vital signs were stable. Physical examinations of head, neck, heart and lungs were normal. In abdominal examination, there was a midline incision related to his previous surgery having mild epigastric tenderness.

Lab tests: Hb: 11.6, HCT: 35, WBC: 4.7×10^3 .

K: 4.1, Na: 145, urea: 19, Cr: 0.8, Alb: 3.4, Total protein: 5.6, LFT (Liver Function Tests): NL, stool: NL.

The upper endoscopic procedure revealed gastritis. There was not any pathologic evidence in colonoscopy. In upper GI x-ray series, the transverse colon NIL relating colon to duodenal-bulb (Figure 1).

Abdominopelvic CT Scan with contrast proved an internal fistula. There was not any pathologic evidence in abdominopelvic ultrasound. Echocardiography revealed mild TR, LVEF=50%, PAP (pulmonary arterial pressure): 50mmHg. In order to evaluate the risk of surgery, spirometry and PPN (peripheral parenteral nutrition) was done.

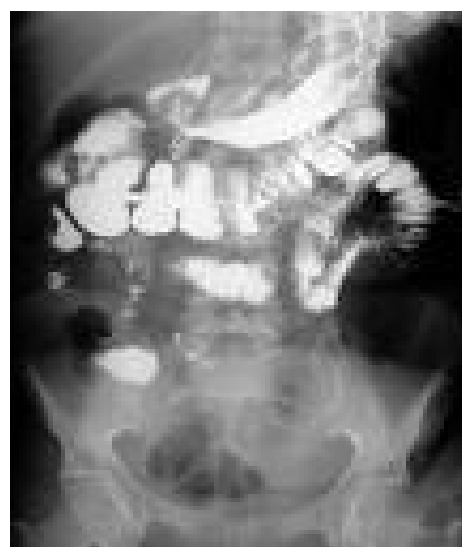


Figure 1. The transverse colon NIL relating colon to duodenal-bulb

Corresponding Author: A. Elyasi

Department of Surgery, School of Medicine, Kermanshah University of Medical Sciences, Kermanshah, Iran
Tel: +98 21 42910700, Fax: +98 21 42910703, E-mail address: a.elyasi@kums.ac.ir

To sum up, it seemed the manifestations of the patient about the benign process were due to a duodenal ulcer and its fistula formation in the colon. After prophylactic antibiotic, the patient underwent for operation. Then, the duodenum was explored through a midline incision and regional enterolysis. A fistula tract of 2-3 cm length between the second part of duodenum and transverse colon was investigated. No tumor or metastasis, as well as fluid, were found in the abdomen. The fistula was cut by the ends followed by repairing colon and duodenum in two layers of silk sutures. Hand sewn loop gastrojejunostomy bypass was done in order to prevent partial obstruction and maintain gastrointestinal function. The abdominal cavity was washed after homeostasis and finally the layers of its wall were repaired according to their anatomic structure. The pathologic evaluation demonstrated a benign process in the formation of fistula from duodenum to the colon.

Discussion

Duodenocolic fistulae are defined as an abnormal communication between a portion of the duodenum and an abdominal visceral cavity which leads to form an internal fistula, or between a segment of the bowel and surface of the body making an external fistula (1). They can be classified into two groups of primary and secondary. A primary fistula is the consequence of duodenocolic fistula occurrence in patients without a relevant surgical history. A secondary duodenocolic fistula is typically a complication of an invasive gastrointestinal procedure (2,3). Primary coloduodenal fistulae are not extensively addressed in the literature and are just limited to case series. This group is again divided into two subclasses: benign and malignant (4). A benign duodenocolic fistula is known as a tract between duodenum and colon or cecum with nonmalignant origin (5). These fistulas, less common than the malignant fistulas may be secondary to peptic ulcer disease, biliary tract disease, ulcerative colitis, regional enteritis, appendicitis, caseating tuberculous lymph nodes, or perforating duodenal diverticula. These fistulas should not be confused with the gastrojejunocolic fistula caused by virulent marginal ulceration at the site of gastroenterostomy (6). Post-bulbar ulcers account for 5% or fewer of all duodenal ulcers; most arise in the vicinity of the ampulla of Vater (7).

But totally, primary duodenocolic fistula is a rare complication of Crohn's disease, peptic ulcer disease, infections or cancer (mostly colon adenocarcinoma)

(8,9).

The benign duodenocolic fistula has gastrointestinal features consisting of abdominal pain (79%), diarrhea (75%), and weight loss (64%), nausea and vomiting (10). One helpful feature in diagnosis may be an episode of acute upper abdominal pain probably due to perforation of the duodenal ulcer followed by sudden diarrheas which sometimes lasts for several years without any response to treatment (11). The mortality rate in external fistulas is much higher than internal ones. The more lethal aspect of external fistula depends on the loss of fluid and electrolytes and dehydration, oliguria, pre-renal azotemia and sometimes, very serious skin and tissue changes around the fistulous opening. Sometimes duodenal leakage to the peritoneal cavity can worsen the situation (1).

Physical examination is usually not informative, other than to reveal the general wasting associated with chronic diarrhea and weight loss (12).

Benn *et al.*, in 1997 recorded a case in which the patient presented severe metabolic acidosis as a complication of alkali loss. After correcting the acidosis and the azotemia through bicarbonate infusion and hemodialysis, excision of the fistula and repair of the duodenal and colonic defects was performed (5).

Sharma *et al.*, in 1995 described an occurrence of a duodenocolic fistula of benign etiology in a 13-year-old boy who presented with chronic diarrhea and severe growth retardation. Their patient had been symptomatic since he was 1-year-old. They believe that the fistula was either congenital in origin or resulted from a pre-existing congenital diverticulum herniated into the transverse colon (13).

In 1953, a case of benign duodenocolic fistula was presented in which the gallbladder, duodenum and hepatic flexure of the colon were involved in acute inflammation. According to the history and the operative findings, the gallbladder was the etiologic factor in the creation of this fistula, rather than a duodenal ulcer. In the first operation the gallbladder was removed, the fistula was taken down and the opening part of the duodenum was closed. Because of the high amount of inflammation in the transverse colon, 13 cm of the latter were resected, and a temporary colostomy performed. The colostomy was closed three weeks later (14).

There are lots of possible causes of massive intestinal bleeding. So working up a case in which the only symptom is hematochezia may take a long time. Upper and lower gastrointestinal endoscopy as well as small bowel x-ray studies or enteroscopy are generally adequate for finding the site of bleeding. But about the

Benign duodenocolic fistula

patient reported by Perri *et al.*, in 1993, no signs of new bleeding were noted on either initial esophagogastroduodenoscopy or proctosigmoidoscopy despite the fact that active bleeding had occurred only a few days before those evaluations. Also, the graphs of small bowel x-rays were not demonstrative of any sign for bleeding. The authors reported a post-bulbar ulcer as the main reason of bleeding in this patient. Although post-bulbar ulcers are fairly rare, their hemorrhagic potential is high, and they must be considered as a possible cause of unexplained intestinal bleeding. The location of these ulcers is so critical that they may not be detectable through standard endoscopic techniques. Most cases of duodenocolic fistulas with different etiologies such as malignancy or Crohn's disease require surgical treatment but ulcerogenic fistulas such as the case described by Perri *et al.*, could be closed after medical therapy (15).

The diagnosis of gastrocolic fistula may be made by upper gastrointestinal barium studies; however, if such a diagnosis is suspected, the fistula can be demonstrated by barium enema, but not by barium meal because a barium enema is of greater accuracy in demonstrating the fistula. Barium enema will usually outline the fistula in over 90 per cent of cases whereas upper gastrointestinal study is associated with an accuracy of approximately 25 per cent (11,16). Kamath *et al.*, in 2011 have found that a combination of radiologic imaging and endoscopy can be a complete evaluation for identifying the location and etiology of duodenocolic fistulae (4).

The treatment of benign duodenocolic fistula involves treating the underlying disorder. It consists of preparing preoperative procedures adequately and then resection of the fistula in a single stage procedure if possible (16). Resection can be performed safely with low perioperative mortality. Also, it has been demonstrated that although operative morbidity was not negligible, most complications resolve with conservative management. Surgical resection is definitely necessary for patients with duodenocolic fistulae suffering from both malignant and benign etiologies who can tolerate a complex resection (4). However, Hureau *et al.*, reported a spontaneous closure in a patient after antimicrobial treatment of tuberculosis (17). Some surgeons believe that resection or closure of duodenal diverticula carries a significant morbidity and mortality related primarily to the development of a lateral duodenal fistula (18). For this reason, a safer form of duodenal closure was applied by them (6). Of course, closure of the aperture in the colon or limited colonic resection may be performed

depending on the size of the fistulous opening in the colon and the amount of inflammation. In gastrocolic fistulas, definitive surgery of the stomach is carried out and is usually gastric resection along with vagotomy or vagotomy with a gastroenteric bypass to overcome the likelihood of ulcer existence. It will be unusual to have a two stage procedure if preoperative preparation and postoperative care is done carefully (16).

Some scientists have shown the effectiveness of serosal patch technique in different patients. In all these reports, the authors present histologic evidence demonstrating that with serosal patch repair, the serosal surface covering the duodenal defect is encased by scar tissue and the ingrowth of duodenal mucosa within two weeks (19). Moreover, there are some other methods such as enteroenterostomy to bypass the patching jejunal loop (20). But anyway, before performing any form of primary repair of a duodenocolic fistula, there should be a great consideration to the patient's nutritional status. After achieving a satisfactory nutritional status, fistula repair may be attempted (6).

This report is affiliated with Emam Reza (A) Hospital, Kermanshah University of Medical Sciences.

References

1. Craighead CC, Raymond AH Jr. Duodenal Fistula with Special Reference to Choledochoduodenal Fistula Complicating Duodenal Ulcer. *Am J Surg* 1954;87(4):523-33.
2. Guraya SY, Murshid KR. Malignant duodenocolic fistula. Various therapeutic surgical modalities. *Saudi Med J* 2004;25(8):1111-4.
3. Liu S, de Blacam C, Lim FY, et al. Magnetic Foreign Body Ingestions Leading to Duodenocolonic Fistula. *J Pediatr Gastroenterol Nutr* 2005;41(5):670-2.
4. Kamath AS, Iqbal CW, Pham TH, et al. Management and Outcomes of Primary Coloduodenal Fistulas. *J Gastrointest Surg* 2011;15(10):1706-11.
5. Benn M, Nielsen FT, Antonsen HK. Benign Duodenocolic Fistula: A Case Presenting with Acidosis. *Dig Dis Sci* 1997;42(2):345-.
6. Kellum JM, Bouche JK, Ballinger WF. Serosal Patch Repair for Benign Duodenocolic Fistula Secondary to Duodenal Diverticulum. *Am J Surg* 1976;131(5):607-10.
7. Ong E, Bohmler U, Wurbs D. Splenic injury as a complication of endoscopy: two case reports and a literature review. *Endoscopy* 1991;23(5):302-4.
8. Shapiro M, Greenstein AJ, Byrn J, et al. Surgical management and outcomes of patients with duodenal Crohn's disease. *J Am Coll Surgeons* 2008;207(1):36-42.

9. Xenos ES, Halverson JD. Duodenocolic fistula: case report and review of the literature. *J Postgrad Med* 1999;45(3):87-9.
10. Spirit M, Sachar DB, Greenstein AJ. Symptomatic differentiation of duodenal from gastric fistulas in Crohn's disease. *Am J Gastroenterol* 1990;85(4):455-7.
11. Winter J. Benign Duodenocolic Fistula. *J Facul Radiol* 1959;10:221-22.
12. Fekguson CHM, Moncuke AC. Benign Duodenocolic Fistula. *Dis Col Rect* 1985;28(11): 852-4.
13. Sharma BC, Yachha SK, Kulshreshta A, et al. Duodenocolic fistula in a child. *Pediatr Surg Int* 1995;10:396-7.
14. Neville WE. Duodenocolic fistula due to acute cholecystitis. *Am J* [HYPERLINK "http://www.ncbi.nlm.nih.gov/pubmed/13114574"](http://www.ncbi.nlm.nih.gov/pubmed/13114574)Surg 1953;87(2):300-2.
15. Perri F, Annese V, Federici T, et al. Benign duodenocolic fistula: an unusual case of gastrointestinal bleeding. *Gastrointest Endosc* 1993;39(6):827-30.
16. Herrington JL. Duodenocolic Fistula with Perforation Secondary to Peptic Ulcer. *Am J Surg* 1967;113(2):285-8.
17. Hureau J, Vayre P. Tuberculose peritoneo-intestinale aigue avec fistule duodeno-colique. *Sem Hop Paris* 1972;48(18):1278-80.
18. Jones TW, Merendino KA. The perplexing duodenal diverticulum. *Surgery* 1960;48:1068-84.
19. Wolfman EF, Trevino G, Heaps KK, et al. An operative technic for the management of acute and chronic lateral duodenal fistulas. *Ann Surg* 1964;159:563-9.
20. Jones SA, Gazzaniga AB, Keller TB. The serosal patch: a surgical parachute. *Am J Surg* 1973;126(2):186-96.