

# Hemolytic Anemia after Aortic Valve Replacement: a Case Report

Feridoun Sabzi<sup>1</sup> and Donya Khosravi<sup>2</sup>

<sup>1</sup> Department of Cardiovascular Surgery, Imam Ali Heart Center, Kermanshah University of Medical Sciences, Kermanshah, Iran

<sup>2</sup> Department of Gynecology and Obstetrics, Preventive Gynecology Research center, Imam Hussein Hospital, Shahid Beheshti University of Medical Science, Tehran, Iran

Received: 06 Mar. 2014; Accepted: 23 Dec. 2014

**Abstract-** Hemolytic anemia is exceedingly rare and an underestimated complication after aortic valve replacement (AVR). The mechanism responsible for hemolysis most commonly involves a regurgitated flow or jet that related to paravalvar leak or turbulence of subvalvar stenosis. It appears to be independent of its severity as assessed by echocardiography. We present a case of a 24-year-old man with a history of AVR in 10 year ago that developed severe hemolytic anemia due to a mild subvalvar stenosis caused by pannus formation and mild hypertrophic septum. After exclusion of other causes of hemolytic anemia and the lack of clinical and laboratory improvement, the patient underwent redo valve surgery with pannus and subvalvar hypertrophic septum resection. Anemia and heart failure symptoms gradually resolved after surgery.

© 2015 Tehran University of Medical Sciences. All rights reserved.

*Acta Med Iran* 2015;53(9):585-589.

**Keywords:** Hemolytic anemia; Mitral valve repair; Regurgitated jet; Heart failure

## Introduction

Ross JC for the first time in 1954 showed that the new prosthetic valves design and the use of more biocompatible materials had greatly reduced their traumatic effects and minimized hemolysis after prosthetic valve replacement. Sayed HM exhibits that this type of hemolytic anemia was documented to be produced by mechanical damage and red cell fragmentation against a foreign surface that is exacerbated by the high speed of circulation. Prevention of such damage has been considered in the designing of new prosthetic valves with low thrombogenic surface. New innovations in the construction of modern valves have been associated with decreasing in the rate of valve-associated hemolytic anemia. Indeed, the incidence of thrombus formation on surface of prosthetic valves far outstrips to their hemolytic damage of red blood cells so with new designing of valve with non thrombogenic material the incidence hemolytic anemia is now reported as an a rare phenomenon. Rajiv M reported that some degree of hemolysis after prosthetic heart valve surgery is relatively common, but hemolysis that required blood transfusion is very rare and showed that mechanical trauma is the main cause of hemolysis and, the mechanism most frequently associated with

hemolysis is turbulence of outflow caused by a valve's configuration and or functioning and exclusively not related to mechanical valve. The purpose of this article was to describe a case of a rare cause of hemolytic anemia, as well as to highlight mild trans-prosthetic gradient as a possible cause of hemolytic anemia.

## Case Report

A 52-year-old man with a history of AVR was admitted to hospital due to acute shortness of breath without typical angina. She also complained of dark urine, jaundice, and right abdominal pain. Laboratory values showed normocytic and normochromic anemia of 8.5 g/L, elevated levels of transaminase, , and alkaline phosphatase, hyperbilirubinemia (6 mg/dL) with a direct fraction of 4.3, an elevated lactate dehydrogenase level of 3211 IU/L, low haptoglobin, hemoglobinuria, and the presence of fragmented red cells in a blood smear. Echocardiography revealed reduced left the ventricular function and trans prosthetic valve gradient of 30 mmHg, and normal aortic valve function but with subvalvar pannus formation. Therefore, the indication for aortic valve replacement or cleaning was scheduled. Cardiopulmonary bypasses (CPB) were instituted in a standard manner; a two-staged venous cannula was

**Corresponding Author:** D. Khosravi

Department of Gynecology and Obstetrics, Preventive Gynecology Research center, Imam Hussein Hospital, Shahid Beheshti University of Medical Science, Tehran, Iran

Tel: +98 21 73430 Fax: +98 21 77557069, E-mail address: dr\_khosravi@yahoo.com

## Hemolytic anemia after aortic valve replacement

placed in the right atrium.

Moderate body hypothermia in the range of 28 to 30 degrees was obtained by CPB. After cross-clamping of ascending aorta and induction of cardiac arrest by cardioplegin, a left atrial vent was used for decompression of the left ventricle. Cold bloody cardioplegia was delivered through aortic root or through the coronary ostia and repeated retrograde cardioplegia was performed every 20 to 30 minutes. The diseased prosthetic aortic valve was carefully evaluated intraoperatively. There was a small pannus formation in left ventricular aspect of prosthetic valve immediately below of valve, prosthetic valve was not restricted but hypertrophic septum, mildly narrowed left ventricular

outflow tract, and this protrusion of septal muscle in sub prosthetic aortic valve was meticulously removed. After the unimpeded opening and closing of the prosthetic valve was ensured aortotomy was closed using double-layer suture of 4-0 polypropylene. We found normal prosthetic aortic valve function with mild subvalvar stenosis (Figures 1-5), which was likely to be the cause of such severe hemolysis. Two months after surgery clinical and laboratory symptoms and signs of hemolysis gradually regressed and patient fully recovered in the 4th month of post surgery and follow-up echocardiography exam revealed normalization of trans valvar gradient.

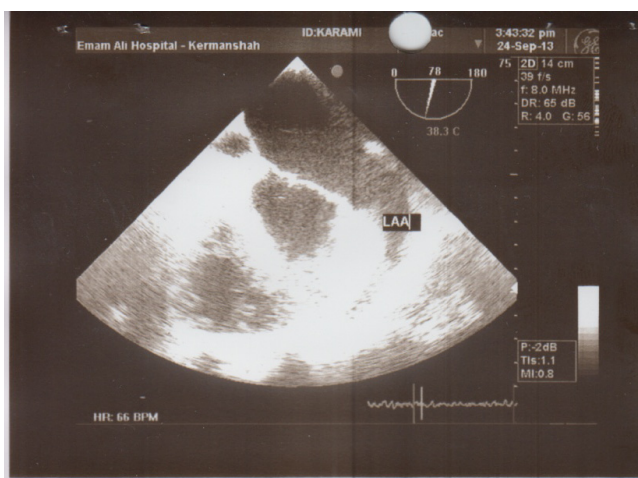


Figure 1. Shows prosthetic valve and tissue growth in subaortic valve

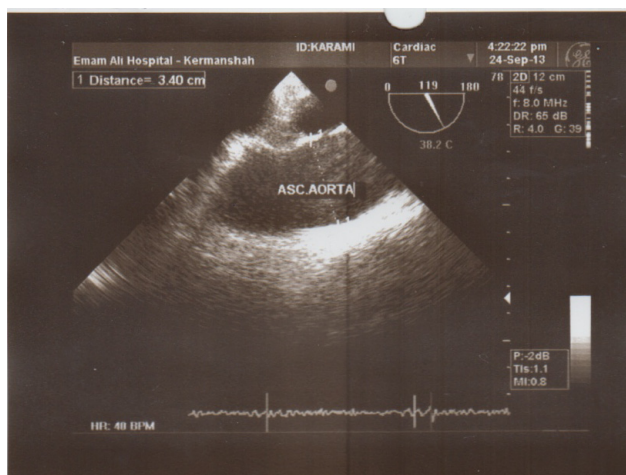


Figure 2. Shows normal diameter of ascending aorta (black arrow)

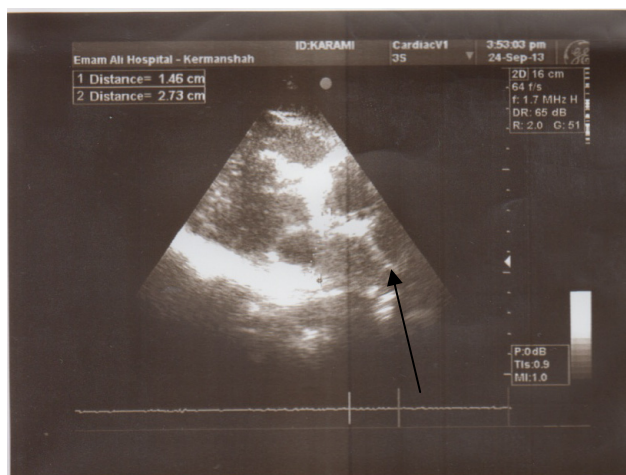


Figure 3. Shows pannus in subaortic valve in four chamber view (black arrow)

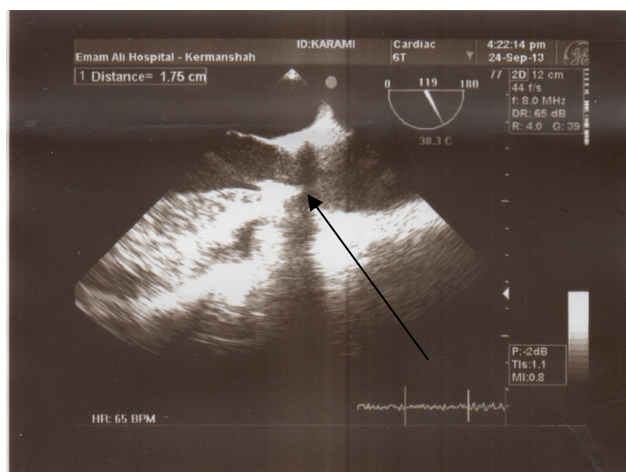


Figure 4. Shows pannus in aortic valve area (black arrow)

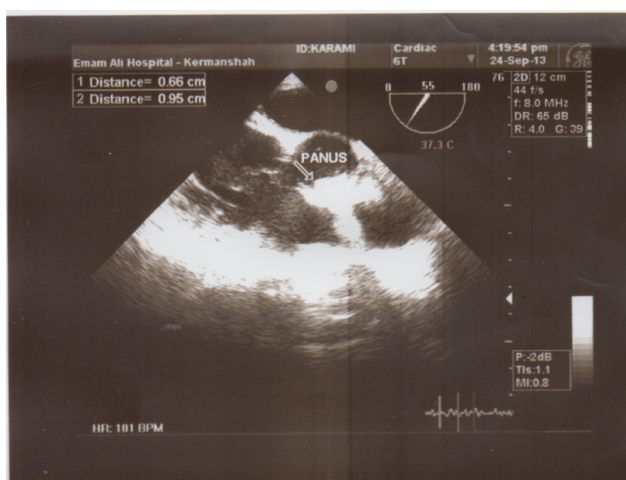


Figure 5. Shows pannus in short axis view

## Discussion

Blackshear in experimental study revealed that in aqueous suspension, the red cell membrane can tolerate shear stress of up to 15,000 dyne/cm<sup>2</sup>.<sup>15</sup>, such size of shear stress was not produced in vivo by measuring of trans valvar gradient across the prosthetic valve, but laboratory evidence of red cell life span, serum haptoglobin level, and serum lactic dehydrogenase concentration in patients with hemolysis in valvular disorders suggests that some hemolysis takes place. Nevaril in an experimental study simulated a cone-plate viscosimeter function as prosthetic valve and showed that hemolysis observed when the amount of shear stress across of plastic- tissue interfaces is more than 2000-2500 dyne/cm<sup>2</sup> (24). The most of shear stress is detected in interfaces of artificial prosthetic valves that are covered with various materials such as synthetic plastic or carbon or metallic compound.

These surface thin mantles are finally covered by a thin endothelial layer. Indeed, this integument does not firmly attached to the underlying materials, and if this layer is extirpated, red blood cells in the rapidly circulated blood flow would be injured by compact with the artificial material. Suedkamp showed that in subjects with prosthetic valves in the aortic site, if the serum level of LDH raises more than 400 U/l, presence of events such as valvular malfunction or paravalvular leak is necessary however exclusion of non-cardiac factors for hemolytic anemia are necessary. However, the presence of paravalvular leakage could be considered without the huge increased level of LDH. Haptoglobin has not considered as a diagnostic modality because in the most of cases it is reduced. The severity of hemolysis does not associate with degree of trans valvular gradient or internal diameter of prosthesis valve. In Astapov A study, a patient with multiple heart valve surgery had a complicated postoperative course by intravascular hemolytic anemia.

In this case prosthetic valve function was normal and no evidence of paravalvular leak was detected. The patient also had a good hemodynamic reaction to the stress of the operation. Replacement of both aortic and mitral valves underwent with a metallic prosthesis and stented biologic porcine valve consequently. The cause of thrombocytopenia was explained by the impact of platelets against of prosthetic valve or destruction of platelets by activation on the surface of foreign body. The paravalvular leak not only is a cause of hemolysis but also may be lead to thromboembolic events.

Skoularigis showed that hemolytic anemia occurred in a large group of patients with prosthetic valves that have normal function. The existence and degree of hemolytic event were evaluated on the basis of serum lactic dehydrogenase levels, amount of haptoglobin, blood, hemoglobin level, and reticulocyte count with the existence of some type of schistocytes. Yuda T showed that there was no any relation between the degrees of hemolysis with internal diameter of prostheses.

The level of LDH, remained high on discharge and declined gradually during postoperative observation, and signs of compensated intravascular hemolysis were demonstrated in all cases by determination of lactic dehydrogenase activity and free hemoglobin in the serum. The author found no correlation between the type and number of prosthetic heart valves and the incidence of hemolysis.

With a rare number of this type of complication, significant intravascular hemolysis is a cause of major concern, not only for cardiac surgeons, but also for cardiologists and internal medicine professionals, even when the prosthetic valve movement is considered adequate

## References

1. Ross JC, Hufnagel CA, Fries ED, et al. The hemodynamic alterations produced by plastic valvular prosthesis for severe aortic insufficiency in man. *J Clin Invest* 1954;33(6):891-900.
2. Sayed HM, Dacie JV, Handley DA, et al. Haemolytic anaemia of mechanical origin after open heart surgery. *Thorax* 1961;16(4):356-60.
3. Rajiv M, Larry J, Alfred I, et al. Evaluation of hemolysis in patients with prosthetic heart valves. *Clin Cardiol* 1998;21(6):387-92 .
4. Mestres C. Intravascular hemolysis after mitral valve repair: a word of caution. *Eur J Cardiothoracic Surg*. 1992;6(2):103-5 .
5. Inoue M, Kaku B, Kanaya H, et al. Reduction of hemolysis without reoperation following mitral valve repair. *Circ J* 2003;67(9):799-801.
6. Blackshear PL Jr, Dorman FD, Steinbach JH, Maybach EJ, Singh A, Collingham RE: Shear wall interaction and hemolysis. *Trans Am Soc Artif Intern Organs* 1966;12(2):113-20.
7. Nevaril CG, Lynch EC, Alfrey CP, et al. Erythrocyte damage and destruction induced by shearing stress. *J Lab Clin Med* 1968;71(5):784-90.
8. Okumiya T, Ishikawa-Nishi M, Doi T, et al. Evaluation of

- intravascular hemolysis with erythrocyte creatine in patients with cardiac valve prostheses. *Chest* 2004;125(6):2115-20.
9. Suedkamp M, Lercher AJ, Mueller-Riemenschneider F, et al. Hemolysis parameters of St. Jude Medical: Hemodynamic Plus and Regent valves in aortic position. *Int J Cardiol* 2004;95(1):89-93.
  10. Astapov DA, Zheleznev SI, Semenova EI. A case of severe intravascular hemolysis after double mechanical heart valve implantation. *Kardiologiia* 2013;53(5):94-5.
  11. Mecozzi G, Milano AD, De Carlo M, et al. Intravascular hemolysis in patients with new-generation prosthetic heart valves: a prospective study. *J Thorac Cardiovasc Surg* 2002;123(3):550-6.
  12. Lund O, Emmertsen K, Nielsen TT, et al. Impact of size mismatch and left ventricular function on performance of the St. Jude disc valve after aortic valve replacement. *Ann Thorac Surg* 1997;63(5):1227-34.
  13. Grob ty M, Venetz JP, Genton CL, et al. Malfunction of a mitral bioprosthesis, hemolysis and acute renal insufficiency. *Schweiz Med Wochenschr* 1995;125(36):1679-83.
  14. Skoularigis J, Essop MR, Skudicky D, et al. Frequency and severity of intravascular hemolysis after left-sided cardiac valve replacement with Medtronic Hall and St. Jude Medical prostheses, and influence of prosthetic type, position, size and number. *Am J Cardiol* 1993;71(7):587-91.
  15. Yuda T, Morishita Y, Arikawa K, et al. Intravascular hemolysis after prosthetic valve replacement. *Nihon Kyobu Geka Gakkai Zasshi* 1990;38(2):270-4.
  16. Febres-Roman PR, Bourg WC, Crone RA, et al. Chronic intravascular hemolysis after aortic valve replacement with Ionescu-Shiley xenograft: comparative study with Bjork-Shiley prosthesis. *Am J Cardiol* 1980;46(5):735-8.
  17. Heilmann E, Bender F, Tasche V. Proceedings: Studies on mechanically induced hemolysis following prosthetic heart valve replacement. *Schweiz Med Wochenschr* 1975;105(51):1790-1.
  18. Slater SD, Prentice CR, Bain WH, et al. Fibrinogen-fibrin degradation product levels in different types of intravascular haemolysis. *Am J Clin Pathol* 1973;3(5878):839-42.