

## Fraccaro Syndrome: Report of Two Iranian Cases: An Infant and an Adult in A Family

Fatemeh Hadipour<sup>1</sup>, Yousef Shafeghati<sup>1,2</sup>, Eiman Bagherizadeh<sup>1</sup>, Farkhondeh Behjati<sup>1,2</sup>, and Zahra Hadipour<sup>1</sup>

<sup>1</sup> Department of Medical Genetics, Sarem Cell Research Center & Hospital, Tehran, Iran

<sup>2</sup> Genetics Research Center, University of Social Welfare and Rehabilitation Sciences, Tehran, Iran

Received: 10 Jun. 2012 ; Accepted: 27 Feb. 2013

**Abstract-** 49,XXXXY is rare chromosomal pattern and these patients have mental retardation, small penis, cryptorchidism and skeletal anomalies. We reported a 10 month-old boy who has hypotonia, microcephaly, hypertelorism, depressed nasal bridge, epicanthic folds and bilateral multiple ear tags, high arched palate, down set ears, micrognathia and congenital heart disease such as patent ductus arteriosus (PDA), Atrial septal defect (ASD), mild pulmonary stenosis. Among the skeletal anomalies, he has kyphoscoliosis, clinodactyly of the fourth and fifth fingers of both hands, and bilateral club foot and unilateral dysplasia of the hip. Karyotype was found as 49,XXXXY[44]/48,XXXY[6] and this cytogenetic analysis was help to establish clinical diagnosis Fraccaro syndrome.

© 2013 Tehran University of Medical Sciences. All rights reserved.

*Acta Medica Iranica*, 2013; 51(12): 907-909.

**Keywords:** 49,XXXXY; Fraccaro syndrome; Facial dysmorphism; Skeletal anomalies

### Introduction

Klinefelter syndrome is a common sex chromosomal abnormality observed in humans, with a prevalence of 1 in 500 males (1-3). The clinical features are variable but often include infertility, gynecomastia, eunuchoidism, small testes and penis and hypergonadotropic hypogonadism. Klinefelter syndrome is a frequent genetic sexual alteration in males, and is usually caused by the presence of one additional X chromosome (47,XXY aneuploidy), however, rare syndrome variants with X and Y polysomy, mosaicisms and aberrant chromosomes have been reported, including 46,XX, 48,XXXXY, 48,XXYY, 49,XXXXXY, 47,XXY/48,XXXXY and 48,XXXXY/49,XXXXXY among others (4).

The 49,XXXXY chromosomal constitution was described by Fraccaro in 1960 (5). Despite being usually considered as a Klinefelter variant, the 49,XXXXY aneuploidy shows a distinct phenotype and more severe clinical features (6,7). More than one hundred cases have been reported, with a frequency of 1 in 85,000 males (1,8). Mosaics with three or more different chromosomal lines are very rare. Here, we describe a case with 49,XXXXY[44]/48,xxxy6 in 10 months old boy with clinical features of Fraccaro syndrome, and his affected relatives who is 45 years old infertile male. Our

cases are the second Iranian known case of Fraccaro syndrome.

The origin of the extra X chromosomes has been traced to successive nondisjunction in maternal meiosis I and II in a few cases studied by molecular methods. No instances of maternal mosaicism for X aneuploidy have been reported (2).

### Case Report

Our first and main case as the second known case of Iranian origin of Fraccaro syndrome is a 10 months old boy. His parents were unrelated. His mother was 32 years old and his father was 38 years olds. He was born by cesarean section at week 39 due to fetal arrhythmias, transient tachypnea of newborn and intrauterine growth retardation. He had a 2850 g birth weight, 49 cm body length and 34 cm cephalic circumference. His mother had done second trimester screening which was normal, and during her pregnancy, everything is normal. The patient's clinical examinations revealed several congenital abnormalities such as hypotonia, microcephaly, hypertelorism, bilateral multiple ear tags, high arched palate, low nasal bridge, epicanthal folds, low-set ears, micrognathia, and congenital heart diseases. In his echocardiography reveals patent ductus

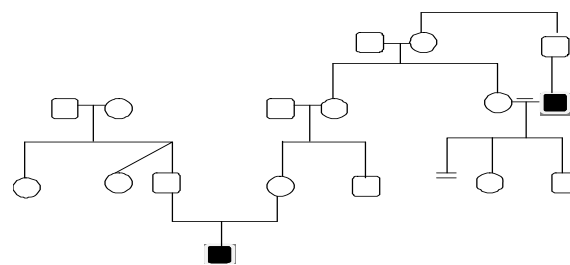
**Corresponding Author:** Zahra Hadipour

Department of Medical Genetics, Sarem Cell Research Center & Hospital, Tehran, Iran  
Tel: +98 21 44670888, Fax: +98 21 44633283, E-mail: Dr.hadipour@yahoo.com

## Fraccaro syndrome

arteriosus (which is closed now), Atrial septal defect (ASD), mild pulmonary stenosis. He has several skeletal anomalies such as kyphoscoliosis, clinodactyly of fourth and fifth fingers of hands, unilateral polydactyly and bilateral club foot, and unilateral dysplasia of the hip. He has hypergonadotropic hypogonadism, cryptorchidism, and micropenis. For these complications he receives replacement therapy. In his renal sonography, microlithiasis was found. In brain MRI was detected mild ventriculomegaly and hydrocephaly. Laboratory studies were normal. Ultrasonography of the abdomen was unremarkable. Cytogenetic study by GTG banding of peripheral lymphocytes showed a 49,XXXXY [44]/48,XXXY[6] (Figure 1).

The most interesting finding of our case is that another relatives of him, is also an adult case of Fraccaro syndrome, who is cousin of his grandmother (mother of his mother). He is 45 years old man, with mild mental retardation and infertility. His infertility was managed by artificial reproductive techniques. His karyotype was 49,XXXXY which was carried out more than 10 years ago. Figure 2 shows the pedigree of this family with two Fraccaro syndromes.

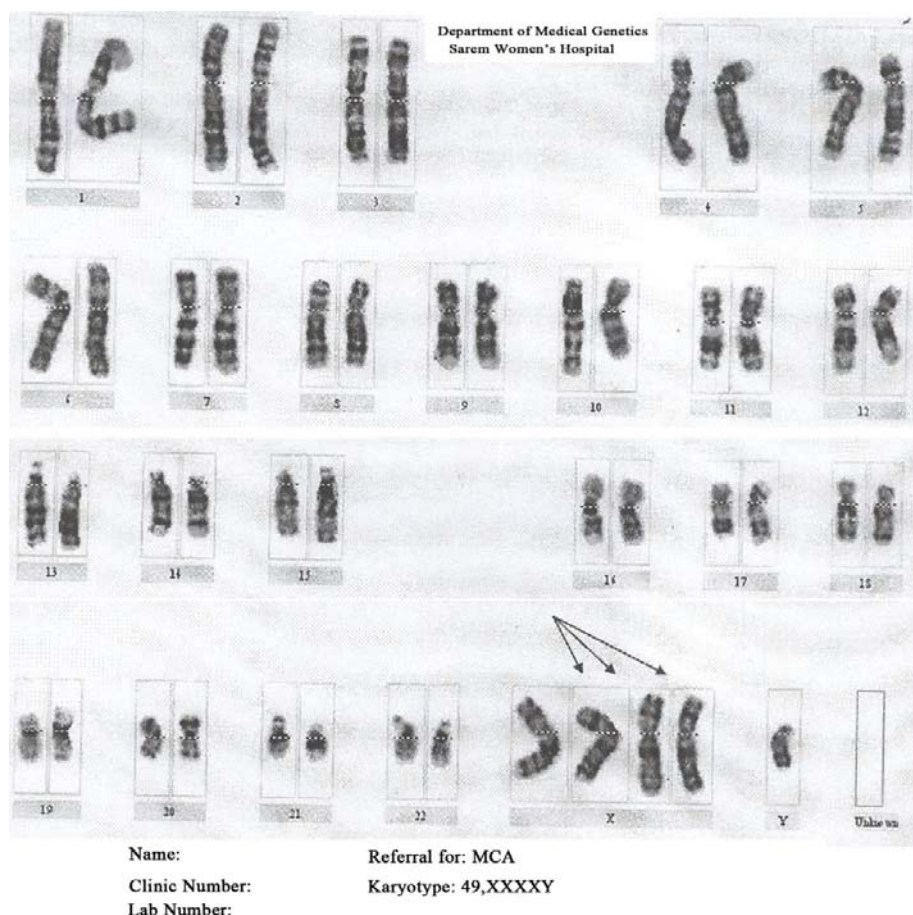


**Figure 2.** Pedigree of the family with two Fraccaro syndrome

## Discussion

Fraccaro syndrome is caused by 49,XXXXY chromosomal aneuploidy and is a rare condition often classified as a Klinefelter syndrome variant, however, as stated by Peet *et al.* and Hou, who propose that it should be diagnosed as an independent clinical syndrome (8,7).

The 49,XXXXY syndrome has not been reported to be associated with maternal age or a hereditary disease (9).



**Figure 1.** The karyotype of the presented case.

The extra X chromosomes result sporadically from either meiotic non disjunction where a chromosome fails to separate during the first or second division of gametogenesis or from mitotic non disjunction in the developing zygote. In some study, the likelihood of X chromosome non-disjunction increases with advancing maternal age. It is believed that 49,XXXXY syndrome occurs during maternal non-disjunction both in meiosis I and II (10,11).

We conclude that the 49,XXXXY syndrome is different from the Klinefelter syndrome in many ways. Chromosome karyotyping is warranted in the presence of facial dysmorphism or other somatic abnormalities, to exclude underlying sex chromosomal aneuploidy disorders such as the 49,XXXXY syndrome. Evaluation of exceptional instances of segregation failure may be useful in improving our understanding of the general mechanisms of non-disjunction. Molecular techniques could be useful for the pre- and post-natal diagnosis of the common aneuploidies and for determining their parental origin. This kind of study will improve knowledge about the mechanisms of the development of aneuploidies, and provide an opportunity to study the effect of the 49,XXXXY syndrome on the phenotype, and enable Appropriated and rapid genetic counseling.

## References

1. Visootsak J, Graham JM Jr: Klinefelter syndrome and other sex chromosomal aneuploidies. *Orphanet J Rare Dis* 2006;1:42.
2. G. Shashidhar Pai, Raymond C. Lewandowski, Jr., Digamber S. Borgeonkar: *Hand book of Chromosomal Syndromes*: ISBN: 978-0-471-37217-2 ,342-343
3. Klinefelter HF, Reifenstein EC, Albright F: Syndrome characterized by gynecomastia aspermatogenes without A-Leydigism and increased excretion of follicle stimulating hormone. *J Clin Endocrinol Metab* 1942, 2:615-627.
4. Hirschhorn K, Hirschhorn R, Fraccaro M, Book JA. Incidence of familial hyperlipemia. *Science* 1959;129(3350):716-7.
5. Fraccaro M, Kaijser K, Lindsten J. A child with 49 chromosomes. *Lancet* 1960;2(7156):899-902.
6. Wattendorf DJ, Muenke M. Klinefelter syndrome. *Am Fam Physician* 2005;72(11):2259-62.
7. Peet J, Weaver DD, Vance GH. 49,XXXXY: a distinct phenotype. Three new cases and review. *J Med Genet* 1998;35(5):420-4.
8. Hou JW. 49, XXXXY syndrome. *Chang Gung Med J* 2004;27(7):551-4.
9. Lia EN, Otero SAM, Ferraz M, Gonçalves LPV. Oral aspects of 49, XXXXY syndrome: a case report. *J Dentist Child* 2007;74(2):136-9.
10. Guzel AI, Demirhan O, Pazarbasi O, Ozgunen FT, Kocaturk-Sel S, Tastemir D. Detection of parental origin and cell stage errors of a double nondisjunction in a fetus by QF-PCR. *Genet Test Molec Biomark* 2009;13(1):73-7.
11. Celik A, Eraslan S, Gokgoz N, Ilgin H, Basaran S, Bokesoy I, Kayserili H, Yuksel-Apak M, Kirdar Betul. Identification of the parental origin of polysomy in two 49, XXXXY cases. *Clin Genet* 1997;51(6):426-9.