

Disseminated Tuberculosis in An AIDS/HIV-Infected Patient

Zahra Abdi-Liae, Pardis Moradnejad, Neda Alijani, Hamide Khazraian,
Sedigh Mansoori, and Naseh Mohammadi

Department of Infectious Disease, Imam Khomeini Hospital, Tehran University of Medical Sciences, Tehran, Iran

Received: 7 Mar. 2012; Received in revised form: 12 Dec. 2012; Accepted: 15 Feb. 2013

Abstract- Disseminated tuberculosis (TB) is commonly seen in HIV-infected patients and is major cause of death in these patients. In HIV-infected patients disseminated tuberculosis is frequently undiagnosed or misdiagnosed. In this article we report a case of disseminated TB in a HIV-infected patient with a relatively long history of fever and other complaints without definite diagnosis. Diagnosis of disseminated TB was confirmed by bone marrow biopsy and polymerase chain reaction analysis (PCR) of the ascitic fluid. With anti-TB treatment signs and symptoms improved.

© 2013 Tehran University of Medical Sciences. All rights reserved.

Acta Medica Iranica, 2013; 51(8): 587-589.

Keywords: Disseminated tuberculosis; HIV-infection; Intravenous drug user

Introduction

Tuberculosis (TB) is one of the most common diseases among HIV-infected persons. There is an annual risk of TB development of 3-13% in HIV infected patients. TB can occur in any stage of HIV infection. In late stages of HIV infection a primary TB-like pattern is more common, but this pattern currently is becoming less common because of the expanded use of antiretroviral treatment. Extrapulmonary TB is common in HIV-infected patients and disseminated TB is one of the most common forms of extrapulmonary TB (1).

Disseminated TB is due to hematogenous spread of tubercle bacilli. Clinical manifestations are nonspecific and protean, depending on the predominant site of involvement. Fever, night sweat, anorexia and weight loss are presenting symptoms in the majority of cases. Physical findings include hepatomegaly, splenomegaly and lymphadenopathy. Chest x-ray reveals a reticulonodular pattern. Also hematologic abnormalities may be seen. Tuberculin skin test may be negative in half of cases. Autopsy studies have shown that many of these cases are not diagnosed before death (2,3). It is also known that without treatment, military TB is lethal (1).

Case Report

A 36-year-old male was presented to emergency department because of fever and chills, generalized abdominal pain, nausea, vomiting and anorexia since 2

months before presentation. He also mentioned 20 kg weight loss during past 2 months.

He was a known case of AIDS (acquired immunodeficiency syndrome) since 8 years ago and had received highly active anti-retroviral therapy (HAART) regimen as medical treatment irregularly.

He also mentioned a history of Hepatitis C involvement 6 years ago without any documents to confirm diagnosis. He was a case of intravenous drug abuse from 18 years ago; also he had been incarcerated 8 years ago for 3 months.

During 2 months before presentation to us he has suffered from fever, anorexia and abdominal pain for which was evaluated in other centers without definite diagnosis.

In physical examination: temperature: 38.5°C, pulse rate: 93 per minute, blood pressure: 100/50 mmHg and respiratory rate: 16 per minute. There was conjunctival paleness, cervical lymphadenopathy, attenuation of pulmonary sounds in basal lobes of both lungs and generalized abdominal tenderness.

On admission laboratory data was as shown below: WBC: 16200/mm³, Hb: 6.8g/dl, PLT: 62000/mm³, ESR: 120, CRP=3+, PBS: hypochromia, reticulocyte count: 0.3%, AST: 102 U/l, ALT: 35 U/l, ALP: 1700 U/l, total bilirubin: 3 mg/dl, direct bilirubin: 2.4 mg/dl, LDH: 750 U/l; BCx2: negative, PPD skin test: 2.5 mm, anti-HIV antibody: reactive, anti-HAV antibody (IgM): negative, HBs antigen: negative, anti-HCV antibody: reactive, anti-HBc antibody (total): negative, anti-HBc antibody

Corresponding Author: Pardis Moradnejad

Department of Infectious Disease, Imam Khomeini Hospital, Tehran, Iran
Tel: +98 21 61192811, Fax: +98 21 61192811, E-mail: Parmorad@gmail.com

Disseminated tuberculosis in an AIDS/HIV-infected patient

(IgM): negative, CD4 count: 25/mm³.

Ascitic fluid analysis showed ADA: 9 U/l, smear and culture: negative, protein: 2.2 g/dl, albumin: 0.9 g/dl (serum albumin=1.4 g/dl), WBC: 677/mm³ (neutrophil: 70%, lymphocyte: 30%).

First ultrasonographic study 1 month before admission was normal, second ultrasonographic study 5 days before admission showed multiple hypoechoic lesions in para-aortic and retroperitoneal areas suspicious to lymphadenopathy which was again reported at repeat ultrasonography after admission in addition to para-celiac lymphadenopathy and mild splenomegaly.

Our initial impression was cholangitis or intra-abdominal infections such as spontaneous bacterial peritonitis (SBP) and to rule-out disseminated TB, therefore intravenous ceftriaxone 1g twice daily and clindamycin 900 mg three times daily were started.

Regarding abdominal pain, jaundice and elevated levels of serum ALP (alkaline phosphatase) and to rule-out obstructive jaundice MRCP (magnetic resonance cholangiopancreatography) was performed which was unremarkable.

A computerized tomography scanning (CT scan) 25 days before admission had shown no abnormality in liver, spleen and kidneys except for mesenteric lymphadenopathy.

A second CT scan imaging with contrast 3 days after admission showed multiple para-celiac and superior para-aortic lymphadenopathy and also small hypodense foci in both kidneys and in spleen, more suggestive for lymphoma or lymphoproliferative lesions (Figure 1). Chest CT scan showed air space lesion in basal segments of right lower lobe and diffuse "tree in bud" appearance and right lung effusion suggesting some types of infectious bronchiolitis such as TB bronchiolitis (Figure 2).

Because of occasional delirium, brain MRI without contrast was ordered which was normal except for diffuse mild brain atrophy.

PCR analysis of the ascitic fluid was positive for *Mycobacterium tuberculosis* DNA. Based on above finding disseminated TB or lymphoma was very probable, so the patient underwent bone marrow aspiration and biopsy (BMB) in which a hypocellular bone marrow with positive Acid-Fast Bacilli (AFB) was reported. So final diagnosis of disseminated TB was confirmed and anti-TB drug regimen of isoniazid (INH) 300 mg daily, rifampin 600 mg daily, ethambutol 800 mg daily and pirazinamide 1250 mg daily was started on 4th days of admission in the infectious disease service.

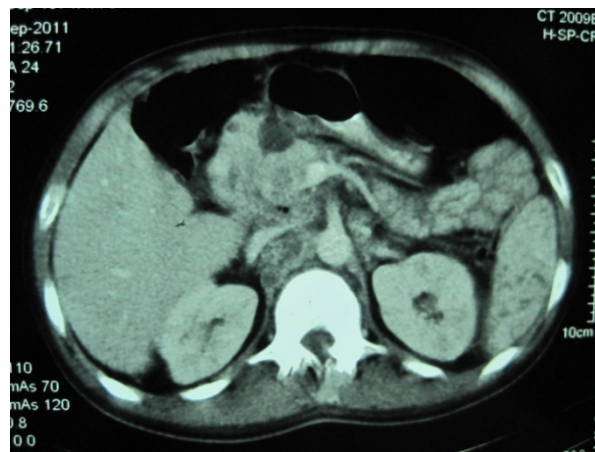


Figure 1. CT scan imaging with contrast 3 days after admission. Multiple para-celiac and superior para-aortic lymphadenopathy and also small hypodense foci in both kidneys and in spleen are seen.

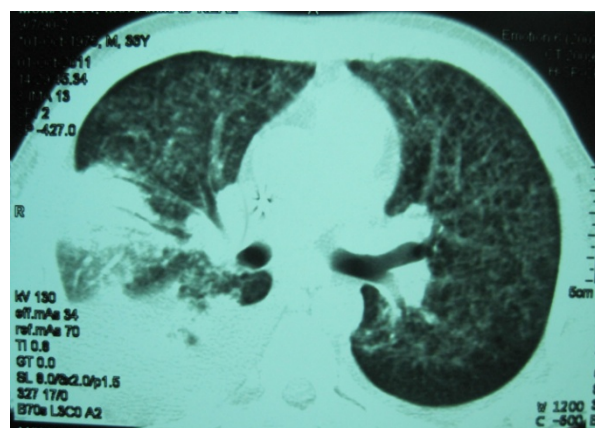


Figure 2. Chest CT scan 10 days after admission. Air space lesion in basal segments of right lower lobe, diffuse "tree in bud" appearance and right lung effusion are seen

Two days later jaundice was aggravated and serum ALT and AST level elevated to 44 U/l and 259 U/l respectively and bilirubin level was 12.8 mg/dl (direct: 5.9 mg/dl) suggesting drug induced hepatotoxicity. Thereafter INH, rifampin and pirazinamide was discontinued and amikacin 500 mg twice daily and ofloxacin 400 mg twice daily were started. 5 days later INH 100 mg daily started increasing to 300 mg. During the next days fever disappeared, abdominal pain was reduced and general condition of patient was better. 15 days after medical treatment he was discharged. During the next 4 months the disease was under control.

Discussion

Disseminated TB in HIV-infected patients usually is misdiagnosed or undiagnosed and has a high fatality rate

and it has been reported that disseminated TB, is the most common cause of death in patients co-infected with HIV and living in TB-endemic countries (2,3). Our patient had a 2 months history of symptoms before attending our center.

In this case abdominal ultrasonography showed multiple para-aortic and para-celiac lymphadenopathy, also mild splenomegaly was reported but liver, kidneys and pancreas were reported as normal. Patel *et al.* using ultrasound in a study on 267 patients with disseminated TB reported that abdominal lymphadenopathy is correlated with active TB in 55.3% of cases (4).

In this case initial impression was an intra-abdominal bacterial infection causing sepsis. It has been reported that disseminated TB occasionally presents with septic shock (5). It is very rare for disseminated TB to present simultaneously with both cerebral and mesenteric abscess as in our case (6). Association of splenic tuberculosis with intravenous drug using has been reported in one study (7) as there was in our patient.

This case showed a high serum AST and LDH level. It has been reported that serum AST and LDH levels is more elevated in patients with tuberculosis than those with non-tuberculous mycobacterial disease (8).

Lee *et al.* reported that HIV-infected patients who are co-infected with pulmonary TB usually have low CD4 count ($102/\text{mm}^3$) and even lower in those with miliary tuberculosis ($40/\text{mm}^3$) (9) as in our case

As in our patient, PPD skin test has been reported to be significantly anergic in patients with disseminated TB (11). Some investigators recommend empiric therapy for TB in patients with advanced HIV co-infection and fever more than two weeks, especially patients with CD4 counts less than $100 \text{ cells}/\text{mm}^3$ (10).

In conclusion, clinicians practicing in areas endemic for mycobacterium tuberculosis should have a high index of suspicion when facing with a HIV-infected patient and should consider immediate empiric anti-TB therapy while waiting for paraclinic data to confirm diagnosis.

References

1. Raviglione MC, O'Brien RJ. Tuberculosis. In: Longo DL, Kasper DL, Jameson JL, Fauci AS, Hauser SL, Loscalzo J, editors. Harrison's Principles of Internal medicine. 18th edition. McGraw Hill 2012; p. 1348-50.
2. Lucas S B, Hounnou A, Peacock C, Beaumel A, Djomond G, N' Gbichi JM, Yeboue K, Honde M, Diomande M, Giordano C. et al. The mortality and pathology of HIV infection in a West African city. *AIDS* 1993;7:1569-79.
3. Ansari N A, Kombe A H, Kenyon T A, Hone NM, Tappero JW, Nyirenda ST, Binkin Ny, Lucas SB. Pathology and causes of death in a group of 128 predominantly HIV-positive patients in Botswana, 1997-1998. *Int J Tuberc Lung Dis* 2002; 6: 55-63.
4. Patel MN, Beningfield S, Burch V. Abdominal and pericardial ultrasound in suspected extrapulmonary or disseminated tuberculosis. *S Afr Med J* 2011;101(1):39-42.
5. Nancoz O, Kherad O, Perrin E, Hsu C, Lobrinus JA, Nendaz M. Disseminated tuberculosis presenting with polymorphonuclear effusion and septic shock in an HIV-seropositive patient: a case report. *J Med Case Reports*;4:155
6. Pandit V, Valsalan R, Seshadri S, Bahuleyan S. Disseminated tuberculosis presenting as mesenteric and cerebral abscess in HIV infection: Case report *Braz j infect Dis* 2009;13(5):383-6
7. Gonzalez-Lopez A, Drona F, Alonso-Sanz M, Chaves F, Fernandez-Martin I, Lopez-Cubero L. Clinical significance of splenic tuberculosis in patients infected with human immunodeficiency virus. *Clin Infect Dis* 1997; 24(6):1248-51.
8. Dos Santos, R.P.; Scheid, K.L.; Goldani, L.Z. Laboratory features for presumptive diagnosis of disseminated tuberculosis in HIV-infected patients. *Int J Tuberc Lung Dis* 2008;12(11):1340-3.
9. Lee MP, Chan JW, Ng KK, Li PC. Clinical manifestations of tuberculosis in HIV-infected patients. *Respirology* 2000; 5(4):423-6.
10. Von Reyn CF, Kimambo S, Mtei L, Arbeit RD, Maro I, Bakari M, Matee M, Lahey T, Adams LV, Black W, Mackenzie T, Lyimo J, Tvaroha S, Waddell R, Kreiswirth B, Horsburgh CR, Pallangyo K. Disseminated tuberculosis in human immunodeficiency virus infection: ineffective immunity, polyclonal disease and high mortality. *INT J TUBERC LUNG DIS* 2011; 15(8):1087-92.
11. Hira SK, Dupont HL, Lanjewar DN, Dholakia YN. Severe weight loss: the predominant clinical presentation of tuberculosis in patients with HIV infection in India *Natl Med J India* 1998;11(6):256-8.