

# Intra-Abdominal Desmoplastic Small Round Cell Tumor in A 45-Year-Old Man: A Case Report

Mandana Ashrafi, Hiva Saffar, Seyed Rasoul Mirsharifi, and Seyed Mohammad Tavangar

*Department of Pathology, Tehran University of Medical Sciences, Tehran, Iran*

*Received: 21 Jun. 2012; Received in revised form: 3 Feb. 2013; Accepted: 5 Jan. 2013*

**Abstract-** Intra-abdominal desmoplastic small round cell tumor is a rare entity with a few reports worldwide. This tumor commonly occurs in children and adolescent and occurrence in adult age group is very rare. Here, we describe an adult male with symptoms of intestinal obstruction due to abdominal mass, located in splenic flexure. After resection, the diagnosis of intra-abdominal desmoplastic small round cell tumor was established by pathologic and immunohistochemical studies. We emphasize that albeit being rare, this tumor should be mentioned as one of the differential diagnoses of widespread intra-abdominal lesions in any age group. A brief review of epidemiology, clinical manifestations as well as pathological and molecular features is also included in the paper.

© 2013 Tehran University of Medical Sciences. All rights reserved.

*Acta Medica Iranica*, 2013; 51(8): 583-586.

**Keywords:** Adult; Desmoplastic small round cell tumor; Intra-abdominal

## Introduction

Intra-abdominal Desmoplastic small round cell tumor (IADSRCT), a distinct and rare entity among the small round cell tumors (1-7) is of uncertain histogenesis, (8-10) and its biological behavior, genetic and morphologic characteristics are yet to be elucidated (11). It was first described by Gerald & Rosai from Memorial Sloan Kettering Cancer Centre, New York (11,12). This highly aggressive neoplasm mostly affects adolescents and young adults (1,2) in their early twenties (11) and is very unusual in the elderly population (13). It typically originates in the abdominal cavity and harbors certain immunohistochemical and cytogenetic features (1,2), which are helpful to distinguish this neoplasm from other small round cell tumors.

Here, we introduce a 45-year-old man with IADSRCT and briefly review the literature about clinical, diagnostic and prognostic features of the tumor.

## Case Report

The patient was a 45-year-old man with 2 month history of abdominal discomfort and fullness admitted for excessive constant abdominal pain, vomiting and obstipation. There was no history of melena, haematemesis, jaundice or urinary symptoms. The

patient past medical history was unremarkable except for diabetes mellitus which was diagnosed 2 years before admission and was under-control by taking Metformin. On physical examination, the abdomen was tender and hard mass mostly localized in Left Lower Quadrant (LLQ) and para-umbilical region was noted. Other organs and systems revealed no significant abnormality. The consultant surgeon, candidate the patient for laparotomy.

On laparotomy, a bosselated tumoral mass with firm consistency and gray-white color measuring 8.5×5.5 cm attached to the external surface of the large bowel and adjacent mesentery identified, with invasion to diaphragm, spleen and pancreas. The bulk of the tumor was located in the mesentery and led to pressure effect on large bowel and narrowing of the lumen. Also, a mass shape irregularity measuring 1.5×1×1cm noted, which was resected by impression of liver metastasis.

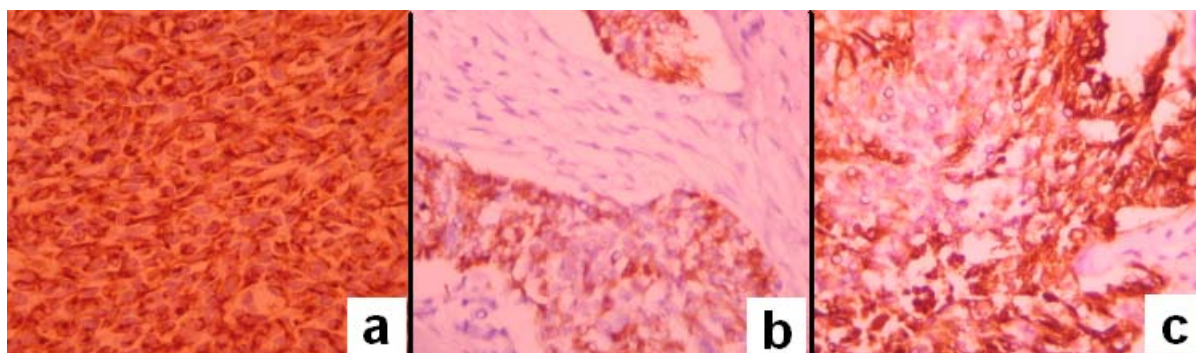
Partial colectomy and splenectomy performed, all removed specimens fixed in %10 buffered formalin and sent for pathologic evaluation.

On pathologic examination, representative tissue samples prepared, processed, 4µm thick sections were cut from each paraffin block and stained with Hematoxylin and Eosin. On microscopy, a malignant neoplasm composed of variable sized nests and sheets of tumor cells separated by desmoplastic cellular stroma.

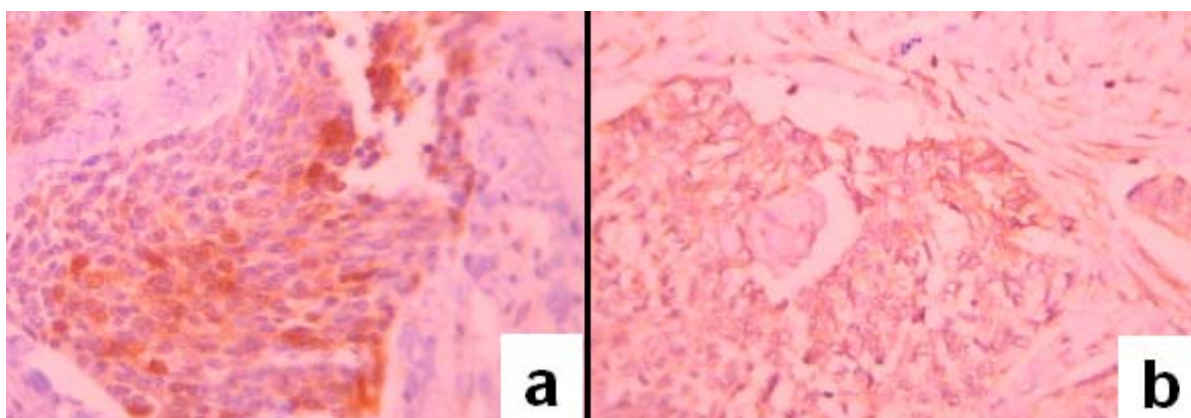
**Corresponding Author:** Seyed Mohammad Tavangar

Department of Pathology, Shariati Hospital, Tehran University of Medical Sciences, Tehran, Iran  
Tel: +98 21 84902187, 912 1485080, E-mail: Tavangar@ams.ac.ir, Tavangar\_md@yahoo.com

## Intra-abdominal desmoplastic small round cell tumor



**Figure 1.** Immunohistochemical staining of the tumor: (a) Dot-like staining of desmin in tumor cells. (b) Positive cytoplasmic reaction to CK. (c) Positive membranous staining of EMA in tumor cells.



**Figure 2.** Immunohistochemical staining of the tumor: (a) Cytoplasmic reaction of NSE in tumor cells. (b) Positive cytoplasmic staining of CD99 in tumor cells.

The tumor cells were small in size with round to oval nuclei, inconspicuous nucleoli and scant clear to pinkish cytoplasm. Occasional alveolar arrangement of cells also seen. Of note were few mitotic figures and areas of necrosis. Perineural and lymphatic invasion was present.

Immunohistochemistry performed using antibodies against CK (Cytokeratin), CK7,CK20, EMA (epithelial membrane antigen), desmin, SMA (smooth muscle actin), myogenin, synaptophysin, chromgranin, S100, HMB-45, C-kit, CD99, NSE (neuron specific enolase) and LCA (leukocyte common antigen) (Table 1). Of these markers, EMA and desmin were positive in the majority of tumor cells and cytokeratin, NSE and CK7 were positive in some tumor cells. CD99 also revealed cytoplasmic reaction. All other markers were negative.

The histological and immunohistochemical findings were in favor of intra-abdominal desmoplastic small round cell tumor (IADSRCT) as final diagnosis.

## Discussion

IADSRCT is an extremely rare neoplasm (7). The cell of origin is not yet known (11). However, its predilection

for serosal involvement indicates the possibility of the mesothelial origin (8,11). This condition commonly affects pediatric age group and adolescents with a male predominance of 4/1(13-15). Occurrence in adulthood, especially after 3<sup>rd</sup> decade as in our patient is rarely reported.

For example in a large series of 32 patients, the mean age was 25 years and most of them had tumors of the abdominal cavity (16). In another series of 14 patients, none was 40 years or older (17). The characteristic presentation of IADSRCT is massive abdominal mass and discomfort with or without pain (11), sometimes accompanied by ascites (1). In a Chinese series of 18 patients, most had involvement of the abdominal cavity with four cases by involvement of root of tongue, fossa orbitalis, soft tissue of eyeball and umbilicus (18).

The most common diagnostic tool is CT-scan, which usually shows multiple intra-abdominal masses with no apparent relationship to primary organ (5,7). There are a wide range of differential diagnoses for IADSRCT including various non-neoplastic and neoplastic diseases such as peritoneal carcinomatosis, desmoid tumor,

fibrous histiocytoma and peritoneal tuberculosis . However, the diagnosis is mainly based on histopathological and immunohistochemical findings. Microscopically, it is categorized as “small round cell tumor” group that include lymphoma, Ewing sarcoma, Wilm’s tumor, rhabdomyosarcoma, primitive neuroectodermal tumor and neuroblastoma (1,13,19,20).

The unique immunohistochemical profile of this tumor plays a great role in distinguishing it from other small round cell tumors. The tumor cells are immunoreactive for epithelial (EMA, keratin), mesenchymal (vimentin), myogenic (desmin) and neural (NSE) markers (6,9,13,21). In myogenic markers, SMA can be positive, but this was not true for our patient. Characteristic dot-like staining pattern with desmin (13) also is of useful features for diagnosis.

Furthermore, a specific cytogenetic abnormality, consists of chromosomal translocation t (11;22) (p13;q12) results in fusion of Ewing sarcoma gene and Wilm’s tumor gene, which can assist in diagnosis of problematic cases (13,16,22).

It is not unusual to expect cytoplasmic reaction against MIC2(CD99) in this tumor,(like ours) as opposed to membranous staining pattern seen in Ewing sarcoma (13).

The course is generally downhill, and the prognosis is very poor (17).

Regarding our limited knowledge about pathologic nature of the disease the optimal therapeutic procedure for this neoplasm is not clear (23). Multimodal therapy consists of aggressive surgical debulking and systemic chemotherapy with or without radiation show survival benefit (13,24,26). Myeloablative chemotherapy with stem cell rescue may also improve progression-free survival (8).

By reporting this case, we emphasis that despite rare occurrence of IADSRCT in adult age and although the characteristic age of the patient is one of the important points that facilitates the diagnosis (9), IADSRCT should be considered as one of differential diagnoses of intra-abdominal small cell tumors.

## References

1. Stuart-Buttle CE, Smart CJ, Pritchard S, Martin D, Welch IM. Desmoplastic small round cell tumor: A review of literature and treatment points. *Surg Oncol* 2008;17(2):107-12.
2. Dufresne A, Cassier P, Couraud L, Marec-Bérard P, Meeus P, Alberti L, Blay JY. Desmoplastic Small Round Cell Tumor: Current Management and Recent Findings. *Sarcoma* 2012;2012:ID:714986, doi.10.1155/2012/714986
3. Gerald WL, Miller HK, Battifora H, Miettinen M, Silva EG, Rosai J. Intra-abdominal desmoplastic small round-cell tumor. Report of 19 cases of a distinctive type of high-grade polyphenotypic malignancy affecting young individuals. *Am J Surg Pathol* 1991;15(6):499-513.
4. Kushner BH, LaQuaglia MP, Wollner N, Meyers PA, Lindsley KL, Ghavimi F, Merchant TE, Boulad F, Cheung NK, Bonilla MA, Crouch G, Kelleher JF Jr, Steinherz PG, Gerald WL. Desmoplastic small round-cell tumor: prolonged progression-free survival with aggressive multimodality therapy. *J Clin Oncol* 1996;14(5):1526-31.
5. La Quaglia MP, Brennan MF. The clinical approach to desmoplastic small round cell tumor. *Surg Oncol* 2000;9:77-81
6. Gerald WL, Ladanyi M, de Alava E, Cuatrecasas M, Kushner BH, LaQuaglia MP, Rosai J. Clinical, pathologic, and molecular spectrum of tumors associated with t(11;22)(p13;q12): desmoplastic small round-cell tumor and its variants. *J Clin Oncol* 1998;16(9):3028-36.
7. Mingo L, Seguel F, Rollan V. Intraabdominal desmoplastic small round cell tumor. *Pediatr. Surg Int* 2005;21(4):279–81.
8. Raja V, Lin JT, Xiao SY. Unusual abdominal tumors. *J Clin Oncol* 2003;21(5):951-3.
9. Philip B, Clement Robert H. Young. The peritoneum. In: Stacey E. Mills, ed. *Sternberg,s Diagnostic Surgical Pathology*. 5th ed. Wolters Kluwer/Lippincott Williams & Wilkins 2010;pp.2400-2.
10. Zeeshan-ud-din, Yaqoob N, Pishoroi T, Rafique MZ, Kamran A . Intra-abdominal desmoplastic small round cell tumor. *J Pak Med Assoc* 2006;56(12):608-10.
11. Biswal BM, Naik VR, Shamim SE. Intra-abdominal desmoplastic small round cell tumor: Presentation of four cases and review of the literature .*Indian J Med Paediatr Oncol* 2010;31(1):24-7.
12. Gerald WL, Rosai J, Ladanyi M. Characterization of genomic breakpoint and chemic transcripts in the EWS-WT1 gene fusion of desmoplastic small round cell tumor. *Proc Natl Acad Sci USA* 1995;92(4):1028-32.
13. Baz W, El-Soueidi R, Nakhf F, Aoun N, Chin N, Dhar M. Desmoplastic small round cell tumor: An adult with previous exposure to Agent Orange. *Jpn J Clin Oncol* 2010;40(6):593-5.
14. Ordóñez NG. Desmoplastic small round cell tumor: a histopathologic study of 39 cases with emphasis on unusual histological patterns. *Am J Surg Pathol* 1998;22(11):1303-13.

## Intra-abdominal desmoplastic small round cell tumor

15. Gerald WL, Rosai J. Desmoplastic small cell tumor with multi-phenotypic differentiation. *Zentralblatt Pathol* 1993;139(2):141-51.
16. Lae ME, Roche PC, Jin L, Lloyd RV, Nascimento AG. Desmoplastic small round cell tumor: a clinicopathologic, immunohistochemical, and molecular study of 32 tumors. *Am J Surg Pathol* 2002;26(7):823-35
17. Pickhardt PJ, Fisher AJ, Balfe DM, Dehner LP, Huettner PC. Desmoplastic Small Round Cell Tumor of the Abdomen: Radiologic-Histopathologic Correlation. *Radiology* 1999;210(3):633-8.
18. Liping Cao, Jun Ni, Risheng Que, Zhengrong Wu, Zhenya Song. Desmoplastic small round cell tumor: a clinical, pathological, and immunohistochemical study of 18 Chinese cases. *Int J Surg Pathol* 2008;16(3):257-62.
19. da Silva RC, Medeiros Filho P, Chioato L, Silva TR, Ribeiro SM, Bacchi CE. Desmoplastic small round cell tumor of the kidney mimicking Wilms tumor: a case report and review of the literature. *Appl Immunohistochem Mol Morphol* 2009;17(6):557-62.
20. d'Amore ES, Ninfo V. Soft tissue small round cell tumors: morphological parameters. *Semin Diagn Pathol* 1996;13(3):184-203.
21. Zhang J, Dalton J, Fuller C. Epithelial marker-negative desmoplastic small round cell tumor with atypical morphology: definitive classification by fluorescence in situ hybridization. *Arch Pathol Lab Med* 2007;131(4):646-9.
22. Sawyer JR, Tryka AF, Lewis JM. A novel reciprocal chromosome translocation t(11;22)(p13;q12) in an intraabdominal desmoplastic small round-cell tumor. *Am J Surg Pathol* 1992;16(4):411-6.
23. Koniari K, Mahera H, Nikolaou M, Chatzis O, Glezakou O, Magiasis V, Kiratzis G. Intraabdominal desmoplastic small round cell tumor: Report of a case and literature review. *Int J Surg Case Rep* 2011;2(8):293-6.
24. Schwarz RE, Gerald WL, Kushner BH, Coit DG, Brennan MF, La Quaglia MP. Desmoplastic small round cell tumors: Prognostic indicators and results of surgical management. *Ann Surg Oncol* 1998;5(5):416-22.
25. Lal DR, Su WT, Wolden SL, Loh KC, Modak S, La Quaglia MP. Results of multimodal treatment for desmoplastic small round cell tumors. *J Pediatr Surg* 2005;40(1):251-5.