

Assessment of Contrast Sensitivity and Aberrations After Photorefractive Keratectomy in Patients with Myopia Greater than 5 Diopters

Alireza Fahim¹, Bijan Rezvan¹, and Hassan Hashemi^{1,2}

¹ Noor Ophthalmology Research Center, Noor Eye Hospital, Tehran, Iran

² Eye Research Center, Farabi Eye Hospital, Tehran University of Medical Sciences, Tehran, Iran

Received: 15 Oct. 2012; Received in revised form: 30 Jan. 2013; Accepted: 22 Feb. 2013

Abstract- This study aimed to assess changes in contrast sensitivity and aberrations in cases of myopia greater than 5.0 diopter (D) who had photorefractive keratectomy (PRK). In this semi-experimental study, 20 eyes of ten patients were studied. Inclusion criteria were at least 5.0 D of myopia, stable refraction in the past year, no history of refractive surgery, a minimum corneal thickness of 480 μm , and having surgery in both eyes. Exclusion criteria were the presence of any corneal condition. In addition to the routine tests, aberrometry and assessment of contrast sensitivity was done using the WaveLight Allegro Analyzer and the VectorVision CSV-1000. After PRK using the Concerto Excimer Laser (WaveLight, Alcon), patients were scheduled to have follow-up visits at 1 month, 3 months, and 1 year after surgery. Contrast sensitivity with glare showed an increasing trend only at the spatial frequency of 3 cycles per degree (cpd) ($P=0.013$). Contrast sensitivity without glare increased postoperatively at special frequencies of 3, 6, and 18 cpd ($P<0.05$). The preoperative level of higher order aberrations root mean square (HOA RMS) of 0.24 ± 0.08 reached 0.71 ± 0.25 at 12 months after surgery. Assessment of comma and trefoil showed no significant difference between preoperative and postoperative values, but the amount of spherical aberration changed from a mean preoperative value of 0.0 ± 0.09 to 0.27 ± 0.15 at 12 months after surgery. In the treatment of myopia greater than 5.0 D, PRK with the Concerto Excimer Laser can improve contrast sensitivity in certain spatial frequencies. This is while HOA RMS and spherical aberration increase.

© 2013 Tehran University of Medical Sciences. All rights reserved.

Acta Medica Iranica, 2013; 51(8): 520-524.

Keywords: Aberration; Contrast sensitivity; Myopia; Photorefractive keratectomy; Spherical aberration

Introduction

In cases of moderate to severe myopia, laser *in situ* keratomileusis (LASIK) is the preferred treatment, because it offers a quick and painless recovery and there is less risk for epithelial opacities. On the other hand, the procedure comes with complications such as inadequate intraoperative flaps, flap folds, ectasia, and increased traumatic eye fragility. In addition, an insufficient residual stroma is a contraindication for LASIK (1). Alternative treatment options for extreme myopia include photorefractive keratectomy (PRK), laser assisted epithelial keratomileusis (LASEK), and epithelial LASIK (Epi-LASIK). In these modalities, flap related complications and mechanical instability are reduced (2), but visual recovery is delayed and there is increased risk of corneal opacification. Such complications are observed more commonly in the

treatment of more severe cases of myopia (2-4). Many studies suggest the use of mitomycin-C to reduce the risk of corneal opacities after PRK (5,6).

Another potential complication of PRK is reduced contrast sensitivity after surgery, especially when higher degrees of refractive errors are corrected (7). However, some studies contradict this and report that contrast sensitivity improves after PRK (8). Since contrast sensitivity is indicative of a qualitative aspect of visual performance, and plays an important role, it needs to be taken into account in comparisons and assessments of surgical efficacy in refractive surgery (9).

Considering the inconclusive results in the literature, and in light of advances in tools and techniques for refractive surgery, we designed the present study to assess changes in contrast sensitivity in cases of myopia greater than 5.0 diopters (D) who had PRK using the Concerto Excimer Laser (WaveLight, Alcon). In

Corresponding Author: Hassan Hashemi

Noor Eye Hospital, #96 Esfandiar Blvd., Valil'asr Ave, Tehran, 19686, Iran

Tel: +98 21 88651515, Fax: +98 21 88651514, E-mail: hhashemi@noorvision.com

addition, we studied changes in aberrations for the assessment of visual performance after surgery.

Materials and Methods

In this semi-experimental study, the target population was cases of myopia of 5.0 D or more. Ten patients, 8 women and 2 men, were enrolled and 20 eyes were studied.

Inclusion criteria were at least 5.0 D of myopia, stable refraction in the past year, no history of refractive surgery such as radial keratotomy (RK), PRK, or LASIK, a minimum corneal thickness of 480 μm , and having surgery in both eyes. Exclusion criteria were the presence of any corneal condition such as herpetic keratitis, keratoconus, vernal keratoconjunctivitis (VKC), history of glaucoma, uveitis, cataracts, diabetes, and collagen vascular disease.

After patient selection, the routine preoperative tests included measurement of uncorrected visual acuity (UCVA), best corrected visual acuity (BCVA), subjective, manifest and cycloplegic refraction, and a complete ophthalmic examination with the slit lamp, indirect ophthalmoscopy, ultrasound pachymetry, standard topography, and Orbscan if necessary. Also, aberrometry and assessment of contrast sensitivity was done using the WaveLight Allegro Analyzer and the VectorVision CSV-1000.

The study was approved by the Institutional Review Board of Noor Ophthalmology Research Center, and all participating patients signed written informed consents.

All surgeries were performed by a single surgeon. After achieving local anesthesia with Tetracaine 0.5%, first, the central 8.0 mm of the cornea was mechanically debrided and then refractive correction was done using the Concerto excimer laser. At the end of the ablation, a 0.02% mitomycin-C solution was used. The application time was 25 seconds for a correction of 5.0 D, and we added 10 seconds to this time for every extra 1.0 D. At the end, the stromal bed was irrigated with 20 ml of normal saline, a bandage contact lens (Air Optix, CIBA Vision, USA) was placed, and chloramphenicol eye drops were instilled. Postoperative medications included betamethasone eye drops 4 times daily for 2 weeks, chloramphenicol eye drops 4 times daily until 2 days after removing the bandage lenses, Artelac artificial tears, Biofenac eye drops 3 times daily, Flucort (FML) drops starting from the third week after surgery after discontinuing betamethasone. Patients were scheduled to have follow-up visits at 1 month, 3 months, and 1 year after surgery, and they had tests for UCVA, BCVA,

refraction (subjective, manifest, and cycloplegic), aberrometry, and contrast sensitivity. In addition, patients completed questionnaires, which inquired about their vision and symptoms such as halos, decreased vision, and double vision. Collected data was entered and analyzed using the SPSS software version 11.5. For the descriptive analysis, we summarized the data in means and standard deviations, and then we used the repeated measures analysis of variance and the Wilcoxon test to assess changes. The analysis method in this study was the intention to treat.

Results

During the study period, 20 eyes of 10 people were evaluated. The patients comprised 8 women and 2 men, and their mean age was 24.6 ± 3.1 (range, 21 to 31) years. Mean preoperative sphere and cylinder errors were -6.8 ± 0.9 D and -1.0 ± 0.8 D, respectively. Mean preoperative pupil diameter was 6.2 ± 1.1 (range; 4.1 to 8) mm.

As demonstrated in figure 1, the mean spherical equivalent in our patients was about 0.1 D at the first, third, and 12th month after surgery. The repeated measures analysis of variance demonstrated a significant difference between preoperative and first, third, and 12th month postoperative results in terms of spherical equivalent ($P < 0.001$), but no significant difference among 1st, 3rd, and 12th month postoperative results ($P = 0.240$). At 3 months, 18 of the 20 eyes (90%) had a spherical equivalent within ± 0.5 D of emmetropia. At 12 months, the spherical equivalent was within 0.5 D of emmetropia in all eyes and 78% enjoyed emmetropia.

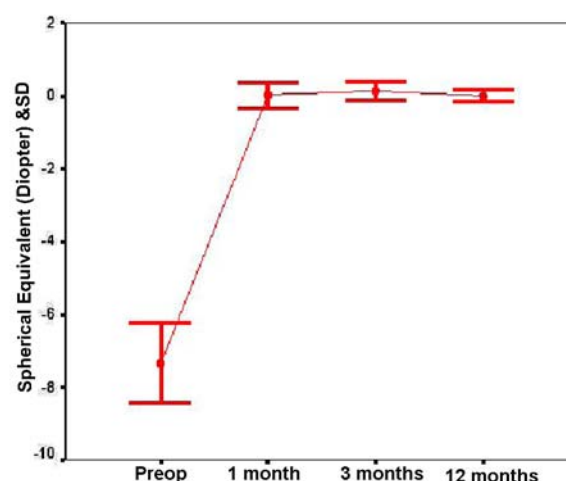


Figure 1. Changes in the spherical equivalent of the treated eyes.

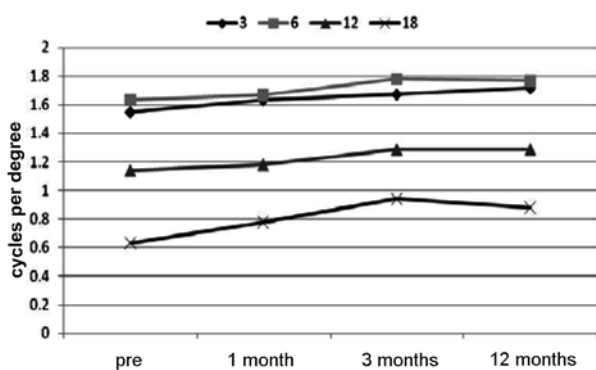


Figure 2. Changes of contrast sensitivity with glare in the treated eyes.

In all eyes, the preoperative UCVA was count fingers. At 1 month and 3 months postoperatively, the mean UCVA improved to 0.04±0.06 LogMAR (9/10) and 0.0±0.0 LogMAR (10/10), respectively. At 12 months after surgery, mean UCVA had a significant increase, compared to preoperative UCVA ($P=0.010$).

The mean preoperative BCVA was 0.0 LogMAR; in other words, the BCVA was 10/10 in all eyes. At 1 month after surgery, mean BCVA was 0.01 LogMAR, and 4 eyes had lost 1 line of BCVA compared to their preoperative data. At 3 and 12 months after surgery, all

eyes had 10/10 BCVA.

Figure 2 and 3 shows the details of contrast sensitivity measurements with and without glare, respectively. Contrast sensitivity with glare showed an increasing trend only at the spatial frequency of 3 cycles per degree (cpd) ($P=0.013$). Contrast sensitivity without glare increased postoperatively at special frequencies of 3, 6, and 18 cpd ($P<0.05$).

Figure 4 demonstrates pre and postoperative levels of aberrations. As summarized in this figure and table 1, the preoperative level of higher order aberrations root mean square (HOA RMS) of 0.24 ± 0.08 reached 0.71 ± 0.25 at 12 months after surgery. Assessment of different aberrations such as coma and trefoil showed no significant difference between preoperative and postoperative values, but the amount of spherical aberration changed from a mean preoperative value of 0.0 ± 0.09 to 0.27 ± 0.15 at 12 months after surgery. This indicates that total increase in HOA is mainly due induced spherical aberration.

At the 1st postoperative month, halo vision and decreased visual acuity occurred in 7 and 8 eyes, respectively, and at the 3rd postoperative months, the incidence was 3 and 1, respectively. At 12 months after surgery, none of the patients complained of halos, decreased vision, or double vision.

Table 1. Preoperative and 12 month postoperative levels of aberrations.

	Pre-op		Post-op	
	Mean	SD	Mean	SD
RMS	0.24	0.08	0.71	0.25
Trefoil 6	-0.02	0.11	-0.08	0.09
Coma y	0.05	0.10	-0.11	0.44
Coma x	-0.00	0.06	0.04	0.46
Trefoil 9	0.00	0.11	-0.04	0.15
Spherical aberration	0.00	0.09	0.27	0.15

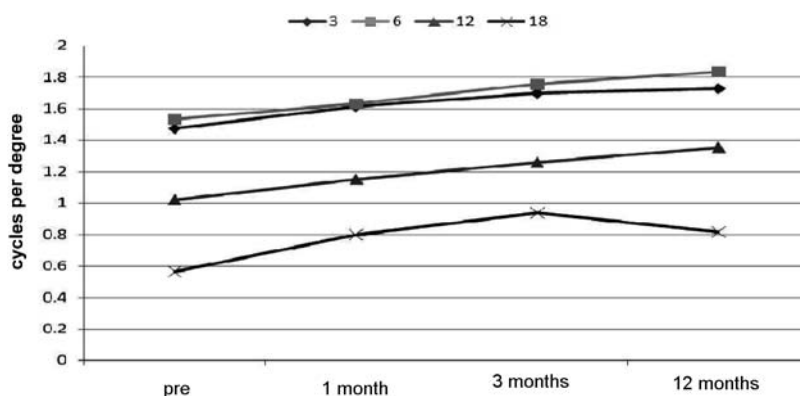


Figure 3. Changes of contrast sensitivity without glare in the treated eyes.

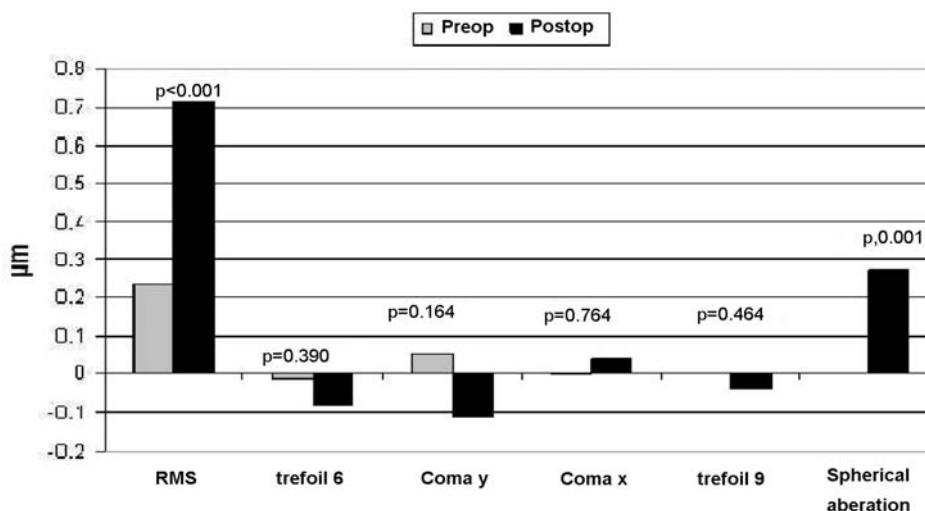


Figure 4. Changes in the level of higher order aberrations.

Discussion

PRK is an acceptable, safe, and effective method for the treatment of mild to moderate myopia, but the correction of extreme cases of myopia is still a challenge. Preliminary efforts of correcting high myopia had unsatisfactory results that showed risk of corneal opacification, loss of BCVA, and delayed visual rehabilitation. Newer techniques and equipment improved the results of PRK in cases of moderate to severe myopia (10). Since previous studies reported different results with different Excimer Laser systems, our main objective in this report is to present the outcome of laser surgery with the Concerto for the correction of myopia higher than 5 D. The Concerto is one of the new generation Excimer Lasers, which delivers optimized ablation profiles, and it has a higher frequency and smaller beam diameter compared to other available Excimer Laser systems (11).

Contrast sensitivity is an important indicator of visual quality and visual performance after laser refractive surgery. In the assessment of small postoperative changes, measurement of contrast sensitivity serves better than visual acuity tests. As mentioned in the results section, the visual acuity improved postoperatively, while contrast sensitivity with glare showed an increasing trend only at the spatial frequency of 3 cpd ($P=0.013$). In terms of contrast sensitivity without glare, an increasing trend was seen at spatial frequencies of 3, 6, and 18 cpd ($P<0.05$).

Many studies have shown decreased contrast sensitivity in myopic eye after PRK. In a study of 56 eyes of 31 patients by Sakata *et al.*, PRK for myopia was found to decrease contrast sensitivity (7). There is

evidence of decreased contrast sensitivity after LASIK as well (12). According to Seiler *et al.*, the decrease is proportionate to the amount of refractive correction (13). With these reports in mind, despite our expectations, we found improvements of contrast sensitivity in some spatial frequencies in the studied eyes. In line with our results, some other reports indicate improvements in contrast sensitivity after refractive surgery (8). Improved contrast sensitivity in our study is probably due to advances in laser refractive surgery equipment in terms of the ablation profile and the beam diameter. To our knowledge, results of new and old generation laser systems have not been compared or reported. In general, it is believed that smaller beam diameters and optimized ablation profiles provide for more accurate corrections of the corneal shape (14). These apply to the Concerto and may be an explanation for better postoperative vision quality in the treated eyes.

It must be noted that irregular astigmatism and higher order aberrations can contribute to reduced contrast sensitivity (15,16), and this can be an interesting topic for future studies.

The eye is not a perfect optical system and aberrations can reduce the quality of vision. In refractive surgery, alterations in the corneal shape can induce more aberrations. Therefore, measuring the amount of aberrations was another aspect of our study.

Previous studies demonstrated increased levels of optical aberrations and decreased visual performance after myopic corrections (13,17). In our study, we observed increased HOA RMS and spherical aberration after surgery compared to preoperative values, and this can be explained in light of previous studies. Possible explanations for the induced spherical aberration include

flattening of the central cornea with myopic correction profiles and reduced Excimer Laser energy in the corneal periphery. With optimized ablation profiles, however, less induction of spherical aberration. In the report by Randleman *et al.*, the difference in ablation profiles between conventional and wavefront optimized is suggested to be responsible for different levels of HOA after surgery with these two approaches. In their study, there was no significant change in the level of spherical aberration in the group, which had wavefront-optimized Excimer Laser treatment (14). The smaller beam diameter of the Concerto Excimer Laser system (11,18) used in our study further raises this expectation. Our study was different in that we had enrolled cases of myopia greater than 5.0 D, and the observed increase in HOA RMS, which was only significant for spherical aberration, could be within acceptable limits. In conclusion, in the treatment of myopia greater than 5.0 D, PRK with the Concerto Excimer Laser can improve contrast sensitivity in certain spatial frequencies. This is while HOA RMS and spherical aberration increase.

References

1. Wallau AD, Campos M. Photorefractive keratectomy with mitomycin-C versus LASIK in custom surgeries for myopia: a bilateral prospective randomized clinical trial. *J Refract Surg* 2008;24(4):326-36.
2. Esquenazi S, He J, Li N, Bazan NG, Esquenazi I, Bazan HE. Comparative in vivo high-resolution confocal microscopy of corneal epithelium, sub-basal nerves and stromal cells in mice with and without dry eye after photorefractive keratectomy. *Clin Experiment Ophthalmol* 2007;35(6):545-9.
3. Ghirlando A, Gambato C, Midena E. LASEK and photorefractive keratectomy for myopia: clinical and confocal microscopy comparison. *J Refract Surg* 2007;23(7):694-702.
4. Moilanen JA, Vesaluoma MH, Müller LJ, Tervo TM. Long-term corneal morphology after PRK by in vivo confocal microscopy. *Invest Ophthalmol Vis Sci* 2003;44(3):1064-9.
5. Hashemi H, Taheri SM, Fotouhi A, Kheiltash A. Evaluation of the prophylactic use of mitomycin-C to inhibit haze formation after photorefractive keratectomy in high myopia: a prospective clinical study. *BMC Ophthalmol* 2004;14;4:12.
6. Carones F, Vigo L, Scandola E, Vacchini L. Evaluation of the prophylactic use of mitomycin-C to inhibit haze formation after photorefractive keratectomy. *J Cataract Refract Surg* 2002;28(12):2088-95.
7. Sakata N, Tokunaga T, Miyata K, Oshika T. Changes in contrast sensitivity function and ocular higher order aberration by conventional myopic photorefractive keratectomy. *Jpn J Ophthalmol* 2007;51(5):347-52.
8. Padmanabhan P, Mrochen M, Basuthkar S, Viswanathan D, Joseph R. Wavefront-guided versus wavefront-optimized laser in situ keratomileusis: contralateral comparative study. *J Cataract Refract Surg*. 2008;34(3):389-97.
9. Lee JE, Choi HY, Oum BS, Lee JS. A comparative study for mesopic contrast sensitivity between photorefractive keratectomy and laser in situ keratomileusis. *Ophthalmic Surg Lasers Imaging* 2006;37(4):298-303
10. Cennamo G, Rosa N, Breve MA, di Grazia M. Technical improvements in photorefractive keratectomy for correction of high myopia. *J Refract Surg* 2003;19(4):438-42.
11. Mearza AA, Muhtaseb M, Aslanides IM. Visual and refractive outcomes of LASIK with the SCHWIND ESIRIS and WaveLight ALLEGRETTO WAVE Eye-q excimer lasers: a prospective, contralateral study. *J Refract Surg* 2008;24(9):885-90.
12. Yamane N, Miyata K, Samejima T, Hiraoka T, Kiuchi T, Okamoto F, Hirohara Y, Mihashi T, Oshika T. Ocular higher-order aberrations and contrast sensitivity after conventional laser in situ keratomileusis. *Invest Ophthalmol Vis Sci* 2004;45(11):3986-90.
13. Seiler T, Kaemmerer M, Mierdel P, Krinke HE. Ocular optical aberrations after photorefractive keratectomy for myopia and myopic astigmatism. *Arch Ophthalmol* 2000;118(1):17-21.
14. Randleman JB, Perez-Straziota CE, Hu MH, White AJ, Loft ES, Stulting RD. Higher-order aberrations after wavefront-optimized photorefractive keratectomy and laser in situ keratomileusis. *J Cataract Refract Surg* 2009;35(2):260-4.
15. Tomidokoro A, Soya K, Miyata K, Armin B, Tanaka S, Amano S, Oshika T. Corneal irregular astigmatism and contrast sensitivity after photorefractive keratectomy. *Ophthalmology* 2001;108(12):2209-12
16. Oshika T, Okamoto C, Samejima T, Tokunaga T, Miyata K. Contrast sensitivity function and ocular higher-order wavefront aberrations in normal human eyes. *Ophthalmology* 2006;113(10):1807-12.
17. Verdon W, Bullimore M, Maloney RK. Visual performance after photorefractive keratectomy. A prospective study. *Arch Ophthalmol* 1996;114(12):1465-72.
18. Iseli HP, Mrochen M, Hafezi F, Sellar T. Clinical photoablation with a 500-Hz scanning spot excimer laser. *J Refract Surg* 2004;20(6):831-4.