

Spontaneous Transanal Protrusion of Ventriculoperitoneal Catheter: A Case Report

Alireza Sharifian¹, Abbas Abdollahi², Ghodrattollah Maddah³, Fakhryalsadat Anaraki⁴, Mina Alvandipour⁵,

Mehdi Abbasi Sahebi³, Noora Bigdeli³, and Ali Mohammad Hasanzadeh⁶

¹ Department of Anesthesiology, Ghaem Hospital, Faculty of Medicine, Mashhad University of Medical Sciences, Mashhad, Iran

² Surgical Oncology Research Center, Imam Reza Hospital, Faculty of Medicine,
Mashhad University of Medical Sciences, Mashhad, Iran

³ Endoscopic and Minimally Invasive Surgery Research Center, Ghaem Hospital, Faculty of Medicine,
Mashhad University of Medical Sciences, Mashhad, Iran

⁴ Department of Surgery, Mahdieh Hospital, Shahid Beheshti University of Medical Sciences, Tehran, Iran

⁵ Department of Surgery, Emam Hospital, Mazandaran University of Medical Sciences, Mazandaran, Iran

⁶ Faculty of Nursing and Midwifery, Mashhad University of Medical Sciences, Mashhad, Iran

Received: 31 Jan. 2012; Received in revised form: 28 Jul. 2012; Accepted: 5 Jan. 2013

Abstract- Ventriculoperitoneal (VP) shunt placement that diverts the cerebrospinal fluid (CSF) into the peritoneal cavity is the most common method of treatment of hydrocephalus. This shunt has a high incidence of malfunction mainly due to catheter obstruction or infection. About 20% of these complications are abdominal that may occur at any time after shunt placement from 1 week to several years. This study reports a case of 2.5-year old child with a history of hydrocephalus who had a VP shunt placed which was protruded from the anus on the day of referral. The patient was treated successfully after extrusion of the shunt through the anus, receiving antibiotics and being carefully observed. He was discharged from the hospital after one week.

© 2013 Tehran University of Medical Sciences. All rights reserved.

Acta Medica Iranica, 2013; 51(2): 135-138.

Keywords: Ventriculoperitoneal shunt; Hydrocephalus; Intestinal perforation

Introduction

Hydrocephalus is defined as enlargement of the ventricles of the brain due to excessive accumulation of cerebrospinal fluid (CSF). The average adult produces about 500 cc of CSF daily, most of which is produced in the ventricle. The CSF passes into the subarachnoid space from the ventricles and then is absorbed into the venous system through the arachnoid granulations. Hydrocephalus is divided into two main types of obstructive and communicating. In obstructive type, any obstruction in CSF circulation causes ventricular dilatation proximal to the obstruction. Obstructive hydrocephalus may occur suddenly. Therefore, to prevent brain herniation an emergent ventriculoperitoneal (VP) shunt placement is required (1). Communicating hydrocephalus is considered by many to be due to obstruction to cerebrospinal fluid outflow (2).

The VP shunt placement is an effective method in

the treatment of hydrocephalus which diverts the CSF into the peritoneal cavity. Unfortunately, shunt placement has a high incidence of malfunction. For example, catheter obstruction, infection or intestinal perforation which may occur at any time after shunt placement (from 1 week to several years). The incidence of intestinal perforation is between 1 to 7% (3).

We report a case of hydrocephalus in a 2.5-year old child in whom the VP shunt had protruded from the anus. Successful treatment of the patient was achieved only by extrusion of the catheter through the anus.

Case Report

A 2.5-year old child was admitted to the Pediatric Emergency Unit for whom a surgical consultation was obtained. He was a known case of cerebral palsy and hydrocephalus from birth in whom a VP shunt had been placed at 6 month after birth. No problem occurred

Corresponding Author: Abbas Abdollahi

Surgical Oncology Research Center, Imam Reza Hospital, Faculty of Medicine, Mashhad University of Medical Sciences, Mashhad, Iran
Tel: +98 511 8022677, 915 3141917, Fax: +98 511 8525255, E-mail: AbdollahiA@mums.ac.ir

Spontaneous transanal protrusion

during this period, until the shunt was protruded from the anus on the day of referral. On examination, the catheter was protruded from the anus for a length of 15 cm and watery excretion was seen at the catheter's point of exit (Figure 1).

On physical examination, the child was described as ill and restless who tolerated oral feeding and did not have nausea, vomiting and fever. His vital signs were also normal. Abdominal examination revealed no significant findings, except for mild abdominal distention. On examination, the shunt was seen on the right parietal side of the scalp without any pathologic finding. Generally the patient did not show growth retardation except for lower limb atrophy due to which he was not able to move them effectively. Also, on examination of the central nervous system (CNS), no signs of meningitis or any other unusual findings were detected.

Plain abdominal radiography showed the distal part of the catheter within gastrointestinal (GI) tract with no signs of occlusion or perforation of the intestine. Also there was no free air in the peritoneal cavity (Figure 2). In brain computed tomography (CT) scan, little air was observed in the brain ventricle (Figure 3). Laboratory examination showed no abnormality.

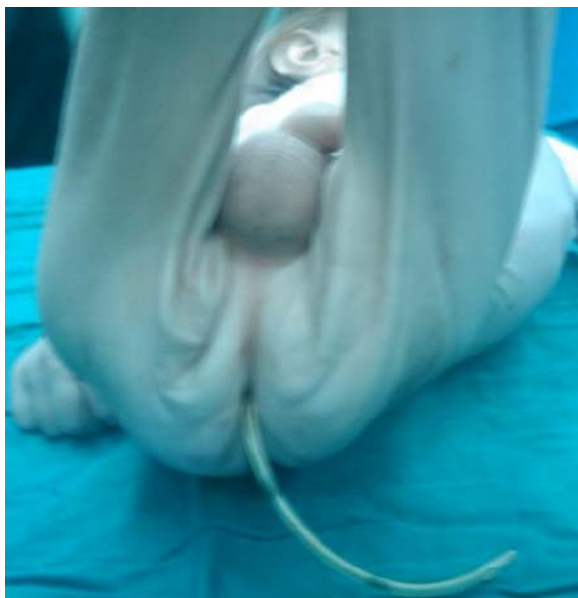

Figure 1. Extrusion of VP shunt from the anus.

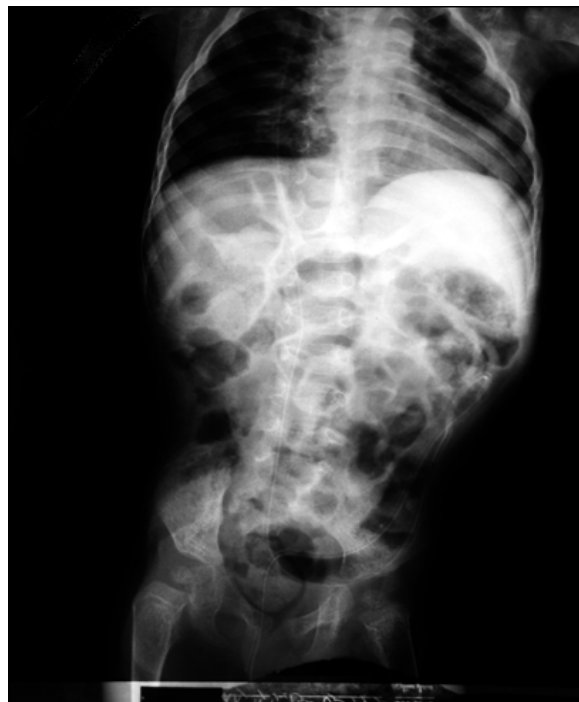

Figure 2. Plain abdominal radiography showing the distal part of the catheter within gastrointestinal (GI) tract.

The catheter was extruded from the anus, because it was protruded through the intestinal lumen without any obvious complications. After extrusion of the catheter, the patient was observed for abdominal signs. No abnormal findings were seen, so a clear liquid diet was started on the 2nd postoperative day. Finally he was discharged from the hospital on 7th day after admission.

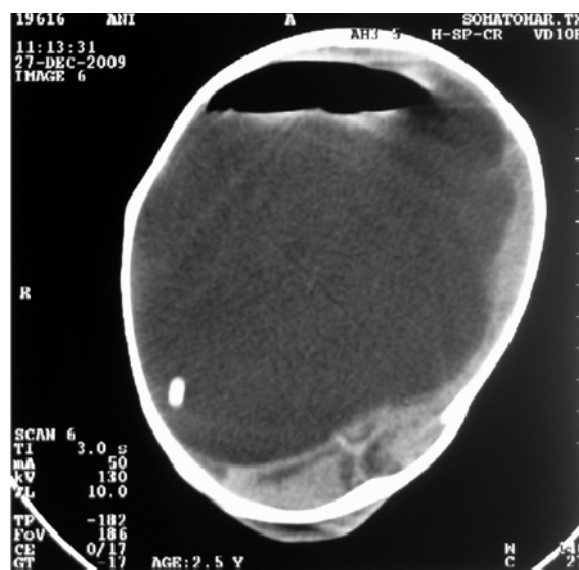


Figure 3. CT scan of the brain showing contralateral subdural hematomas with pneumocephalus.

Discussion

The VP shunt placement is an effective method of treatment in hydrocephalus patients, having some major complications in up to 25% of cases that may occur at any time after shunt placement. Infection and blockage of the shunt are the most common complications related to this operation. Uncommon complications include pseudocyst formation, obstruction, spontaneous protrusion of the shunt and subsequent intestinal perforation (4).

The etiology of intestinal perforation is still unknown, though some theories have been suggested. The formation of a local inflammatory reaction and fibrosis around the distal catheter and also the local pressure effect may result in intestinal perforation. The Types and materials of catheters and the length of its abdominal part are also considered as the other important factors involved in perforation of the intestine (3). Several cases of catheter related intestinal perforation have been reported.

If a definitive diagnosis of peritonitis is established, performing an urgent laparotomy is mandatory. But if catheter protrusion through the intestinal wall causes a partial intestinal obstruction, it can be managed with catheter extrusion. Laparotomy should be performed if there is any sign of complete obstruction (5,6).

Neither peritonitis nor intestinal obstruction was identified in this patient, so the catheter was extruded. Finally he was discharged with good general condition.

In 2009, Birbilis *et al.* reported a 54-year old Greek man with spontaneous perforation of sigmoid colon as a complication of distal ventriculoperitoneal shunt displacement. The patient was received antibiotics who showed no response to medical treatment, so he underwent intestinal resection and anastomosis (3). Nakahara *et al.* described an obese 64-year old woman with secondary hydrocephalus and subarachnoid hemorrhage who underwent VP shunt placement. On the 10th postoperative day, the abdominal wall was perforated by the distal end of the VP shunt and a subcutaneous cyst filled with CSF was formed around the catheter. Finally, the distal catheter was surgically replaced in the peritoneal cavity (7).

In addition to the abdominal complications of the shunt, intra-thoracic problems were also reported. For example, reports which describe distal shunt migration into the heart have been rare, and only 11 cases have been reported until now. Due to venous circulation, coupled with negative intrathoracic pressure, the distal

catheter is migrated through jugular vein into the heart (8).

A rare case of catheter protrusion from the mouth was also reported that the patient was treated with removal of the catheter and laparotomy was not needed (9).

The evaluation of CSF regarding infection is an important step in management of such patients with intestinal perforation, because there is possibility of retrograde contamination of CSF and high probable incidence of meningitis (10).

There are some reports that advocate the catheter removal by rectosigmoidoscopy or colonoscopy, though in cases of peritonitis or abscess performing laparotomy is needed (11). Some complications such as pseudocyst, catheter displacement, infection, malfunction and hernia can be safely managed through laparoscopy (12). In conclusion, in cases of catheter protrusion from the intestinal lumen leading to intestinal perforation, if a definitive diagnosis of peritonitis is established, an urgent laparotomy is required. But, if peritonitis does not occur or it results in partial obstruction of the intestine, it is enough to extrude the catheter through the anus, then institute antibiotic therapy and observe the patient carefully.

Acknowledgment

The authors gratefully acknowledge the contribution of Ms. M. Hassanpour for editing the manuscript.

References

1. Smith ML, Bauman JA, Grady MS. Neurosurgery, in: Brunicaardi FC, Andersen DK, Billiar TR, Dunn DL, Hunter JG, Matthews JB, Pollock RE, eds. Schwartz's Principles of Surgery. 9th ed. New York, NY: McGraw-Hill, 2010, p 1554.
2. Nagra G, Wagshul ME, Rashid S, Li J, McAllister JP 2nd, Johnston M. Elevated CSF outflow resistance associated with impaired lymphatic CSF absorption in a rat model of kaolin-induced communicating hydrocephalus. *Cerebrospinal Fluid Res* 2010; 7(1):4.
3. Birbilis T, Zazos P, Liratzopoulos N, Oikonomou A, Karanikas M, Kontogianidis K, Kouklakis G. Spontaneous bowel perforation complicating ventriculoperitoneal shunt: a case report. *Cases J* 2009;2:8251.
4. Mohta A, Jagdish S. Spontaneous anal extrusion of ventriculoperitoneal shunt. *Afr J Paediatr Surg* 2009;6(1):71-2.

Spontaneous transanal protrusion

5. Martinez Hernández-Magro P, Barrera Román C, Villanueva Sáenz E, Zavala MJ. Colonic perforation as a complication of ventriculoperitoneal shunt: a case report. *Tech Coloproctol* 2006;10(4):353-5.
6. Ferreira PR, Bizzi JJ, Amantea SL. Protrusion of ventriculoperitoneal shunt catheter through the anal orifice. A rare abdominal complication. *J Pediatr Surg* 2005;40(9):1509-10.
7. Nakahara K, Shimizu S, Oka H, Utsuki S, Iida H, Fujii K. Migration of the distal end of a ventriculoperitoneal shunt in to the Neurol Med Chir (Tokyo) 2009;49(10):490-2.
8. Ruggiero C, Spennato P, De Paulis D, Aliberti F, Cinalli G. Intracardiac migration of the distal catheter of ventriculoperitoneal shunt: a case report. *Childs Nerv Syst* 2010;26(7):957-62.
9. Sridhar K, karmarkar V. Peroral extrusion of ventriculoperitoneal shunt: case report and review of literature. *Neurol India* 2009;57(3):334-6.
10. Zhou f, Chen G, Zhang G. Bowel perforation secondary to ventriculoperitoneal shunt: case report and clinical analysis. *J Int Med Res* 2007;35(6):926-9.
11. Ghritlaharey RK, Budhwani KS, Shrivastava DK, Gupta G, Kushwaha AS, Chanchlani R, Nanda M. Trans-anal protrusion of ventriculo-peritoneal shunt catheter with silent bowel perforation: report of ten cases in children. *Pediatr Surg Int* 2007;23(6):575-80.
12. Popa F, Grigorean VT, Onose G, Popescu M, Strambu V, Sandu AM. Laparoscopic treatment of abdominal complications following ventriculoperitoneal shunt. *J Med Life* 2009;2(4):426-36.