

## Indeterminate Cell Histiocytosis: Report of a Case

Alireza Ghanadan<sup>1</sup>, Kambiz Kamyab<sup>1</sup>, Mazaher Ramezani<sup>2</sup>, Azadeh Goodarzi<sup>3</sup>, Maryam Daneshpazhooh<sup>3</sup>,  
Kamran Balighi<sup>3</sup>, Mahsa Ansari<sup>3</sup>, Seyed Farzad Mirfallah Nassiri<sup>3</sup>, and Soroush Daklan<sup>3</sup>

<sup>1</sup> Department of Pathology, Razi Hospital, Tehran University of Medical Sciences, Tehran, Iran

<sup>2</sup> Department of Pathology, Kermanshah University of Medical Sciences, Kermanshah, Iran

<sup>3</sup> Department of Dermatology, Razi Hospital, Tehran University of Medical Sciences, Tehran, Iran

Received: 11 Jul. 2013; Accepted: 24 Dec. 2013

**Abstract-** Indeterminate cell histiocytosis is a very rare disorder of histiocytes proliferation. It has both Langerhans and non-Langerhans cell histiocytosis immunophenotypic features. We described a 45-year-old man with a 2 years history of multiple yellow-brown papules and a few red nodules on his trunk and extremities. No internal involvement was detected first and after 8 months. As his lesions were asymptomatic and sparse, he didn't receive any treatment. He will be followed at regular intervals.

© 2014 Tehran University of Medical Sciences. All rights reserved.

*Acta Medica Iranica*, 2014;52(10):788-790.

**Keywords:** Indeterminate cell histiocytosis; Non-Langerhans cell histiocytosis; Immunohistochemistry

### Introduction

Indeterminate cell histiocytosis (ICH) is a very rare histiocytic proliferative disorder with both Langerhans cell and non-Langerhans cell immunophenotypic features. It presents as solitary or generalized lesions (1).

In most of the patients, multiple asymptomatic pink to brownish papulonodules develop without epidermal changes (2).

The disease usually has a benign clinical course, but a lympho- or myeloproliferative disorder can be associated (3).

### Case Report

A 45-year-old previously healthy man presented with a 2-year history of multiple yellow-brown papules and a few red nodules on his trunk and extremities (Figure 1). The lesions increased in number during this period and were asymptomatic. The patient's history, physical examination, and routine laboratory tests didn't show any internal involvement.

Skin biopsy was taken with regard to clinical differential diagnoses including eruptive xanthoma, eruptive syringoma, histiocytosis and sarcoidosis.

Histopathologic examination revealed diffuse infiltration of lymphohistiocytes filled upper dermis, and Touton multinucleated giant cell among infiltration (Figure 2).

Immunohistochemical examination showed positive histiocyte cell immunoreactions for S-100 protein, CD1a and CD68 (Figure 3).

We assumed a diagnosis of indeterminate cell histiocytosis based on clinicopathologic and immunohistochemical findings. Ultrastructural studies were not performed as electron microscopy wasn't in our access.

### Discussion

Wood *et al.*, first reported ICH as a neoplastic dermal indeterminate cell disease (4). To date less than 50 cases of ICH has been reported (1). The disease is a proliferative disorder of dendritic cells that has both Langerhans cells (CD1a and S-100-positive) and macrophages (CD68-positive) immunophenotypic features. Birbeck granules that are characteristic of Langerhans cells, can't be detected by electron microscopy in ICH histiocytes (3,5). Nowadays, it has been proposed that ICH could be a non-Langerhans' cell histiocytosis variant (2).

ICH pathogenesis remained unknown till now. Although most lesions occur spontaneously; some triggering factors as scabies and pityriasis rosea, have been reported (4). Our patient didn't mention any triggering factor.

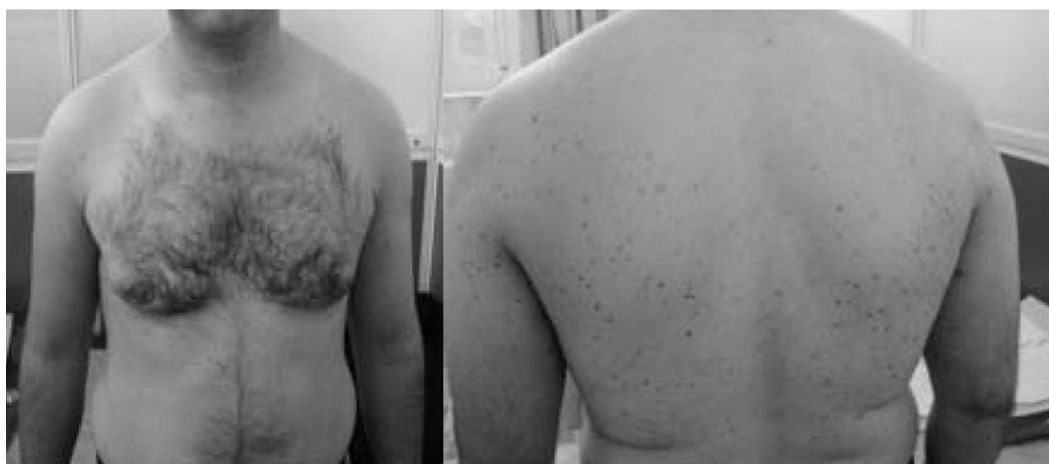The disease presents as solitary or multiple skin lesions, and can be seen in both adults and children. The

**Corresponding Author:** M. Ansari

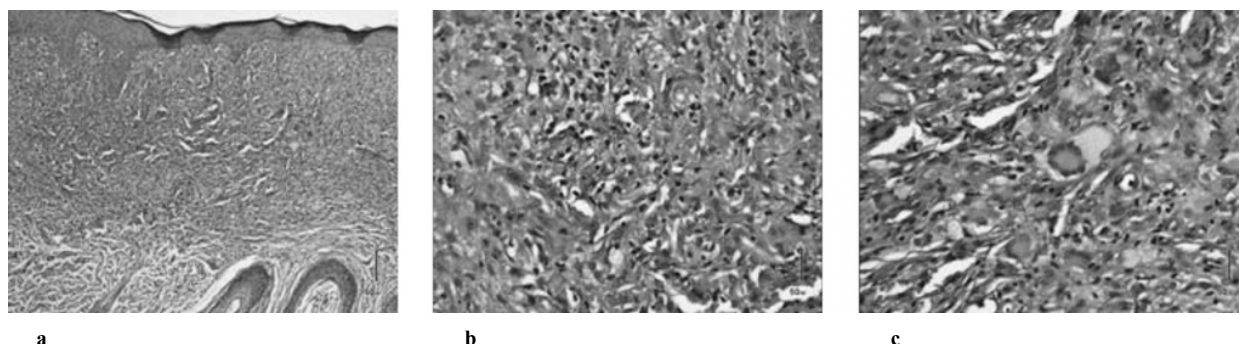
Department of Dermatology, Razi Hospital, Tehran University of Medical Sciences, Tehran, Iran  
Tel: +98 913 3409349, Fax: +98 21 55699977, E-mail address: ansarima66@gmail.com

extracutaneous involvement is very rare (6). There are four reports of ICH association with malignancies: one case of mast cell leukemia, another patient with myelomonocytic leukemia, and two cases with low-grade B-cell lymphomas (1,2,8,9-10). As ICH has a benign clinical course, conservative management is the best approach. ICH is a very rare disease, so no standard

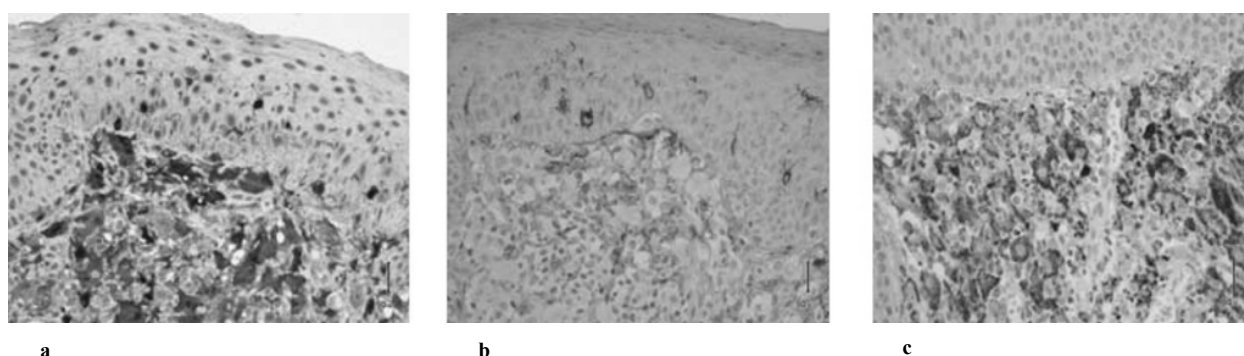
treatment has been found effective (4). In some cases, skin lesions were resolved spontaneously (7). Some treatments that have been used for ICH till now include systemic chemotherapy, PUVA, Narrowband Ultraviolet B, thalidomide, pravastatin and low dose methotrexate (1,3,11-13).



**Figure 1.** Multiple yellow-brown papules and a few red nodules on the patient's trunk and extremities



**Figure 2.** a) Diffuse infiltration of lymphohistiocytes filled upper dermis, b) Intermingled with some lymphocytes and eosinophils, c) A Touton multinucleated giant cell among infiltration



**Figure 3.** a) Strong immunoreaction for S-100, b) Weak immunoreaction for CD1a, c) Strong immunoreaction for CD68

## Indeterminate cell histiocytosis

Chemotherapy must be used for aggressive cutaneous ICH, which involves over 50% of the body surface area and lasts at least 6 months with no spontaneous resolution and new appearing lesions (2).

As mentioned above we assumed the diagnosis of ICH for our patient based on clinicopathologic and immunohistochemical studies. We didn't perform extensive clinical investigation for internal malignancies as it was reported in only few cases till now. Of course, our patient's clinical history, physical examination and routine laboratory tests didn't show any internal involvement. The patient refused to receive any treatment because of the benign course of the disease and his sparse and asymptomatic lesions. We followed the patient's clinical course for 8 months. His lesions didn't progress or regress in this period. He was also evaluated for the probability of visceral involvement again by taking history, precise physical examination, and routine laboratory tests in this follow-up period and no evidence of these complications was detected. Long-term follow-up will be done for the patient.

## References

1. Goodman WT, Barrett TL, Histiocytosis V, et al, editors. *Dermatology*. Philadelphia, PA: Elsevier Saunders; 2012: p. 1529-46.
2. Ventura F, Pereira T, da Luz Duarte M, et al. Indeterminate Cell Histiocytosis in Association with Acute Myeloid Leukemia. *Dermatol Res Pract* 2010;2010: 569345-9.
3. Bard S, Torchia D, Connelly EA, et al. S100-Negative Indeterminate Cell Histiocytosis in an African American Child Responsive to Narrowband Ultraviolet B. *Pediatr Dermatol* 2011;28(5):524-7.
4. Yin R, Zheng WJ, Yang XC, et al. Recurrent generalized indeterminate cell histiocytosis: a case report. *J Am Acad Dermatol* 2010;63(1):e3-5.
5. Rezk SA, Spagnolo DV, Brynes RK, et al. Indeterminate cell tumor: a rare dendritic neoplasm. *Am J Surg Pathol* 2008;32(12):1868-76.
6. Ferran M, Toll A, Gilaberte M, et al. Acquired mucosal indeterminate cell histiocytoma. *Pediatr Dermatol* 2007;24(3):253-6.
7. Ishibashi M, Ouchi T, Tanikawa A, et al. Indeterminate cell histiocytosis successfully treated with ultraviolet B phototherapy. *Clin Exp Dermatol* 2008;33(3):301-4.
8. Ratzinger G, Burgdorf WHC, Metze D, et al. Indeterminate cell histiocytosis: fact or fiction? *J Cutan Pathol* 2005;32(8):552-60.
9. Kolde G, Brocker EB. Multiple skin tumors of indeterminate cells in an adult. *J Am Acad Dermatol* 1986;15(4 Pt 1):591-7.
10. Vener C, Soligo D, Berti E, et al. Indeterminate cell histiocytosis in association with later occurrence of acute myeloblastic leukaemia. *Br J Dermatol* 2007;156(6):1357-61.
11. Tóth B, Katona M, Hársing J, et al. Indeterminate cell histiocytosis in a pediatric patient: successful treatment with thalidomide. *Pathol Oncol Res* 2012;18(2):535-8.
12. Burns MV, Ahmed A, Callahan GB, et al. Treatment of indeterminate cell histiocytosis with pravastatin. *J Am Acad Dermatol* 2011;64(5):e85-6.
13. Fournier J, Ingraffea A, Pedvis-Leftick A. Successful treatment of indeterminate cell histiocytosis with low-dose methotrexate. *J Dermatol* 2011;38(9):937-9.