

Epidermal Nevus Syndrome and Dysplastic Kidney Disease

Azar Nickavar¹, Najmessadat Atefi², and Kambiz Kamyab Hesari³

¹ Department of Pediatric Nephrology, Aliasghar Children's Hospital, Iran University of Medical Sciences, Tehran, Iran

² Department of Dermatology, Aliasghar Children's Hospital, Iran University of Medical Sciences, Tehran, Iran

³ Department of Pathology, Razi Dermatology Hospital, Tehran University of Medical Sciences, Tehran, Iran

Received: 19 Jan. 2013; Accepted: 27 Jul. 2013

Abstract- Epidermal nevus syndrome is a rare congenital disorder, characterized by epidermal nevi and multiple organ involvement. Multicystic kidney disease has been very rarely reported in this syndrome. Here is the report of a boy presented with multiple epidermal nevi, cardiac anomaly, seizure attack, hemi hypertrophy, and multicystic dysplastic kidney complicated with Wilms' tumor. According to this association, it is suggested to search for dysplastic kidney disease in patients with neurocutaneous disorders.

© 2014 Tehran University of Medical Sciences. All rights reserved.

Acta Medica Iranica, 2014;52(8):647-649.

Keywords: Epidermal nevus syndrome; Multicystic dysplastic kidney; Wilms' tumor; Neurocutaneous disease; Seizure

Introduction

Epidermal nevus syndrome (ENS) is a rare sporadic neuroectodermal disease characterized by a combination of hamartomatous hyperkeratotic epidermal nevi, associated with developmental anomalies of central nervous system (50%), skeletal (67%), ocular (35-70%), cardiovascular, and urogenital system in 10% of children. Different types of tumors have been reported in ENS (1-3).

Wilms' tumor has been rarely reported in ENS, usually present as a primary tumor. Multicystic dysplastic kidney (MCDK) has been very rarely reported in ENS (4). This is the presentation of a boy with ENS and MCDK, complicated with Wilms' tumor.

Case Report

A 2-year-old boy was admitted for a huge abdominal mass since a few months ago. He had an episode of seizure at 1 year old. Family history was negative for any sporadic or genetic disorder. All laboratory exams were normal. Physical examination revealed failure to thrive; multiple large and diffuse brown nevi scattered on chest, trunk and limbs, with a large non tender abdominal mass, and left leg hypertrophy.

Radiologic exams showed mild rickets, brain atrophic changes, soft tissue hypertrophy of the left leg, and dilated left iliac and femoral vessels. He had a history of Patent ductus arteriosus, aortic coarctation,

atrial septal defect, pulmonary hypertension and poor left ventricular function which have been repaired at 2 months of age.

MRI and MRA of the left leg revealed soft tissue hypertrophy, dilatation and tortuosity of left iliac and femoral vessels and early filling of dilated great saphenous vein. Bony structures were normal.

Abdominal ultrasound at one year before admission showed enlarged hyperechoic left kidney, with multiple cortical and medullary echogenic lesions of 7-8 mm diameter; suggestive of MCDK. DMSA renal scan showed normal right kidney and non-functioning left kidney. But, renal ultrasound and abdominal CT scan at admission revealed normal right kidney, and abnormal left kidney, replaced by a massive and heterogeneous solid (mainly cystic) mass, extending to the pelvic area, suggestive of Wilms' tumor.

Skin biopsy showed papillomatous epidermis with hyperkeratosis, acanthosis, and basal layer pigmentation in favour of epidermal nevus (Figure 1).

Renal biopsy revealed neoplastic tissue with triphasic pattern, a mixture of blastemal, stromal and epithelial components with capsular invasion (stage II/IV). Blastemal area consists of cells with small and round hyperchromatic nuclei and scant cytoplasm. Epithelial element showed primitive lobules with papillary structures. Remnant of the non neoplastic renal parenchyma showed multicystic renal tissue with cystic dilated tubules, fibrosis and chronic interstitial inflammation, suggestive of Wilms' tumor in a

Corresponding Author: A. Nickavar

Department of Pediatric Nephrology, Aliasghar children's hospital, Iran university of Medical Sciences, Tehran, Iran
Tel: +98 21 22226127, Fax: +98 21 22220063, E-mail address: anickavar@yahoo.com

multilocular cystic kidney disease (Figure 2).

Nephrectomy along with chemotherapy was performed for eradication of Wilms' tumor. The patient is now at remission with no recurrence of Wilms' tumor.

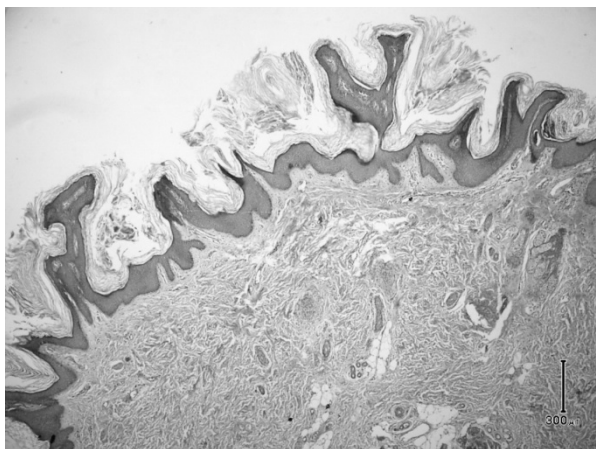


Figure 1. Papillomatous, hyperkeratosis, acanthosis and basal layer pigmentation of epidermis (hematoxylin-eosin, original magnification x 40)

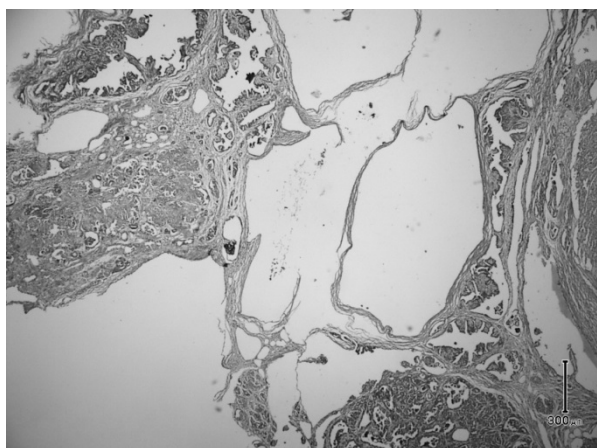


Figure 2. Multicystic area accompanied by papillary and tubular structures of Wilms' tumor (hematoxylin-eosin, original magnification x 40)

Discussion

Epidermal nevus syndrome (ENS) is a rare neurocutaneous disorder, first described by Solomon et al in 1968 (1). It is a sporadic, congenital disorder of unknown etiology, affects both genders, and reflects a genetic mosaicism of a lethal autosomal dominant mutation (2).

As a rare association, different manifestations of renal and urologic disorders have been reported in ENS. Hypertension with high plasma renin activity secondary

to renal artery stenosis and narrowing of the abdominal aorta might occur in ENS. Therefore, it has been suggested to search for renovascular hypertension in neuroectodermal disorders with increased systemic blood pressure (1,5).

Hypophosphatemic vitamin D resistant rickets with phosphaturia has been rarely reported in ENS, as the most frequently skeletal disorder (6,7). It is characterized by low serum 1,25 (OH)₂ cholecalciferol, hypophosphatemia and increased alkaline phosphatase level (8). Decreased renal tubular phosphate reabsorption occurs secondary to a circulating factor; phosphatonin, which is secreted from skin lesions. It has been encountered the pathogenic mechanism of renal rickets, resolves by removal of skin lesions (7,9). A patient with ENS and vitamin D responsive hypophosphatemic rickets has been also reported (9).

Other associations such as polycystic kidney disease (10), and hypoplastic kidney with lymphangiectasia have been reported in ENS (2).

Primary Wilms' tumor is the other complication of ENS. It is considered as the most common childhood renal tumor, occurs as a primary renal tumor in 1/8000-10000 general population or by transformation of a MCKD in less than 1/2000. Unilateral MCKD is the most common cystic kidney disease in children, occur nearly 1/4000 live birth, dominantly in the left kidney (11). Pathogenesis of MCKD includes genetic disturbances, teratogens, intrauterine infections, and urinary outflow obstruction (12).

MCKD has been rarely reported in ENS. We could find the report of a 4 months old boy with epidermal nevus, left lower extremity lymphedema, alopecia, atrial septal defect, infantile spasm and MCKD (4). Our patient had Wilms' tumor secondary to a primary MCKD, which is as a very rare event in ENS. Therefore, it is suggested to search for renal dysplasia in patients with neurocutaneous disorders and to consider neurocutaneous disorders in patients with MCKD disease.

References

1. Alsohim F, Abou-Jaoude P, Ninet J, et al. Bilateral renal artery stenosis and epidermal nevus syndrome in a child. *Pediatr Nephrol* 2011;26(11):2081-4.
2. Kaur T, Kumar B, Chawwla YK. Epidermal nevi associated with extrahepatic portal venous obstruction, hypoplastic kidney and lymphangiectasia: a new syndromic variant? *BR J Dermatol* 2004;150(3):618-9.
3. Kishida ES, Muniz Silva MA, da Costa Pereira F, et al.

- Epidermal nevus syndrome associated with adnexal tumors, spitz nevus, and hypophosphatemic vitamin D-resistant rickets. *Pediatr Dermatol* 2005;22(1):48-54.
4. Kim HS, Shin YK, Lee KH, et al. A Case of Epidermal Nevus Syndrome with Infantile Spasm. *J Korean Child Neurol Soc* 1998;5:346-50.
 5. Aizawa K, Nakamura T, Ohyama Y, et al. Renal artery stenosis associated with epidermal nevus syndrome. *Nephron* 2000;84(1):67-70.
 6. Oranje AP, Przyrembel H, Meradji M, et al. Solomon's epidermal nevus syndrome (type: linear nevus sebaceus) and hypophosphatemic vitamin D-resistant rickets. *Arch Dermatol* 1994;130(9):1167-71.
 7. Herman TE, Siegel MJ. McCune Albright Syndrome: Epidermal Nevus Syndrome. *Clin Pediatr* 2010;49(12):1164-6.
 8. Stosiek N, Hornstein OP, Hiller D, et al. Extensive linear epidermal nevus associated with hemangiomas of bones and vitamin-D-resistant rickets. *Dermatology* 1994;189(3):278-82.
 9. Moreira AI, Ferreira G, Santos M, et al. Epidermal nevus syndrome associated with hypophosphatemic rickets. *Dermatol Online J* 2010;16(9):14.
 10. Bourdeaut F, Hérault A, Gentien D, et al. Mosaicism for oncogenic G12D KRAS mutation associated with epidermal nevus, polycystic kidneys and rhabdomyosarcoma. *J Med Genet* 2010;47(12):859-62.
 11. Cambio AJ, Evans CP, Kurzrock EA. Non-surgical management of multicystic dysplastic kidney. *BJU Int* 2008;101(7):804-8.
 12. Hains DS, Bates CM, Ingraham S, et al. Management and etiology of the unilateral multicystic dysplastic kidney: a review. *Pediatr Nephrol* 2009;24(2):233-41.