

Atrial Dissociation in a Middle Aged Patient: a Case Report

Shokoufeh Hajsadeghi¹, Saeed Oraii², Hassan Riahi¹, Sayeyed Hashem Sezavar¹, Amir Hossein Ghanooi¹,
Scott Reza Jafarian Kerman³, and Roghayeh Ahmahi⁴

¹ Department of Cardiology, Rasoul-Akram Hospital, Iran University of Medical Sciences, Tehran, Iran

² Department of Cardiology, Tehran Arrhythmia Center, Tehran, Iran

³ Department of Cardiology, Student Scientific Research Center, Tehran University of Medical Sciences, Tehran, Iran

⁴ Department of Medicine, Faculty of Medicine, Iran University of Medical Sciences, Tehran, Iran

Received: 4 Apr. 2013; Accepted: 17 Nov. 2013

Abstract- Atrial dissociation is characterized by different types of P waves captured in an electrocardiogram, usually seen in critically ill or post-cardiac transplantation patients. Our case demonstrates a 55-year-old man, presenting with chestpain (unstable angina) in the emergency department with transient double-P waves; representing the phenomenon. Our case did not have any of the suggested causes or any known cardiac problems; therefore, with ruling out other differential diagnosis, researches must be done to find another explanation, if repeated.

© 2014 Tehran University of Medical Sciences. All rights reserved.

Acta Medica Iranica, 2014;52(8):641-651.

Keywords: Atrial Dissociation; Electrocardiographic study; Case report

Introduction

Atrial dissociation (AD) is a complete inter-atrial block, characterized by two sets of independent atrial complexes and two different-shaped P waves in ECG; indicating that the two whole or selected parts of the atria are activated by it, which can be independently normal or abnormal. This phenomenon can be produced artificially or found in terminal patients. It has been suggested that each atrium beats separately and independently, as a result, of blockage or interruption of Bachmann's - an intra-atrial - bundle. AD is very rare and was demonstrated in a few case reports that were all in an extremely ill state (1-2). We have described a 55-year-old patient with a transient atrial dissociation following a chest pain.

Case Report

The patient was a 55-year-old man who was admitted to the emergency department of our center after an onset of chest pain, which radiated to inferior mandible with one-hour duration. He was a known case of hypertension and had a history of CABG 6 years before admission. He had no history of diabetes, cardiac

failure, arrhythmia, or structural cardiac disease. He has been taking 80 mg aspirin tablets daily; 75 mg clopidogrel daily, 20 mg atorvastatin daily, 25 mg metoprolol twice a day and 25 mg losartan twice a day for the past 6 years. His brother expired at age of 52 because of myocardial infarction. Physical examination revealed a middle-age man who seemed not ill or toxic with pulse rate of 50 beat per minute and regular beats. The blood pressure was 130/80 mmHg; respiratory rate was 14 per minute with no respiratory distress. Pulmonary, abdominal and extremities' examinations were unremarkable. A diagnosis of acute coronary syndrome was made, and he was treated with anti-platelets, heparin, nitrate, and beta-blocker and statin, urgently.

The 12-lead electrocardiogram recorded on admission showed sinus rhythm (rate 60/min). The PR interval measured 0.13 s in lead II. The P waves measured 0.10 s in lead II and were notched in leads II, aVR, aVF, and V2 to V6. The PQ segments were isoelectric in all leads. The T waves were inverted in leads I, aVL, and V6 and flattened in leads V4 and V5.

In TTE, LVEF was 60% with normal cardiac valves and no regional wall motion abnormalities. LA and RA dimensions and pulmonary artery pressure (SPAP:

Corresponding Author: S.R. Jafarian Kerman

Department of Cardiology, Student Scientific Research Center, Tehran University of Medical Sciences, Tehran, Iran
Tel: +98 912 1474563-, Fax: +98 21 22742123, E-mail address: r-jafarian@student.tums.ac.ir

Atrial dissociation in a middle aged patient

30mmHg) were normal. His angiogram, which was done a year ago, showed patent left internal mammary artery (LIMA) and saphenous vein (SV) grafts but poor runoff on native arteries.

Three days after admission, he had no sign or symptom. A routine electrocardiogram was performed again. The ventricular rate was 49/min, which appeared to have supernumerary P waves (P') with the rate of 60/min. (Figure 1). The electrodes were not loose, and no one was in direct contact with the patient or the electrodes; the patient was not hiccupping and his respiratory rate was 14/min at the time of the examination. Atrial dissociation was suspected.

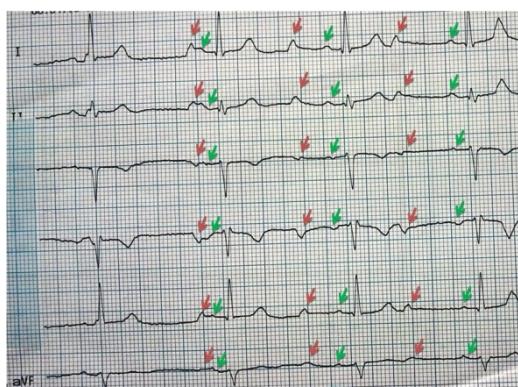


Figure 1. Atrial Dissociation, the Green arrows, indicate normal P wave, Red arrows indicate p' waves

The original P waves were unchanged and still captured the ventricles consistently with an unchanged PR interval. The P' waves were taller with a duration of 80 msec. During the next ECGs, this p' wave was not found. The patient was monitored electrocardiographically for two days by means of chest electrodes, but atrial dissociation did not recur (Figure 2).

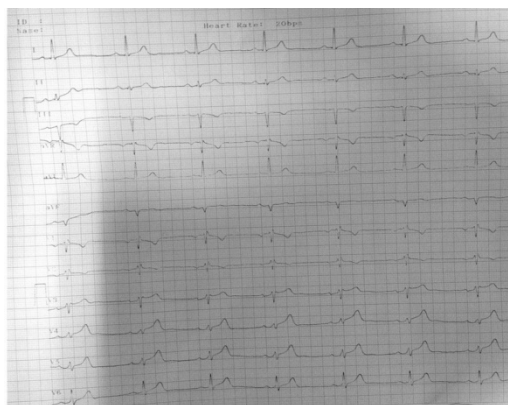
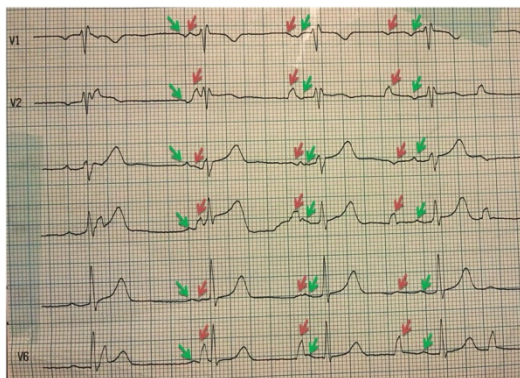


Figure 2. Normal rhythm after the previous ECG, without the atrial dissociation (no p' wave)

Discussion

Atrial dissociation is a rare occurrence. Wenckebach in 1906 was first to report it in a man without any interpretation (3). But Schrupf in 1920 have demonstrated a 37-year-old man as the first electrocardiogram showing a double set of P waves in mitral stenosis and aortic insufficiency (4). However, there are reports that are believed to be ECG artifacts. Even some researchers believe that there is no such thing as an atrial dissociation, and all comes from mis"lead"ing (5-6).

They have demonstrated that loose right or left foot (green or black) lead or any interruption near these leads can results in miss-capture of an additional P wave, but as in our case -as far as our knowledge- we are sure about the connections and, therefore, we are reporting a true case.

There are a few studies demonstrating the same condition. Khan has reported a 78-year-old terminally ill patient with a history of MI and CHF (7). Scherf and Cohen have also demonstrated a set of cases with atrial dissociation (8). The only similarity between these cases was Digoxin consumption, and they concluded that digitalis toxicity along with other probable causes such as rheumatic heart disease, uremia, hypertension, and some type of infections can be the reason of AD.

The mechanism is still not clearly known; however, interruption of inter-atrial pathway (Bachmann's bundle) or atrial myocardium separation with ectopic impulse formation has been suggested and are mostly seen in the post-cardiac transplantation and critically ill patients. But there have always been a debate regarding its diagnoses. This phenomenon should be closely differentiated from atrial parasystole, non-conducted

atrial premature contractions and, mostly, artifacts; as Clark and Douglas have demonstrated a double-case report of misdiagnoses. Furthermore, some studies have suggested that huge cardiomegaly may develop this presentation (1-2, 7-8).

Having not a cardiac, musculoskeletal, neurologic and any other problem, which can lead us to misdiagnose, indicates that there should be another explanation for its etiology. Furthermore, it has been demonstrated that atrial dissociation is almost always found in patients with congestive heart failure; however, the importance of our case is based on 2 categories: 1- it was transient; 2-the patient was not critically ill with normal LVEF and normal size left atrium.

Atrial dissociation is an uncommon presentation, which can be misdiagnosed with many situations. Any patient with this phenomenon should be evaluated for existing suggested causes such as cardiomegaly, digitalis toxicity and cardiac transplantation; not forgetting that it can be an artifact.

References

1. Schamroth L. Intra-atrial block and the atrial dissociation. In: Schamroth L, editor. The disorders of cardiac rhythm. 2nd ed. Oxford: Blackwell Scientific Publication; 1971: p. 231.
2. Hayes WL, Kerby GR. Atrial Dissociation. *Am Heart J* 1964;68:252-3.
3. Wenckebach KF. Beitrage zur Kenntnis der menschlichen Herztaetigkeit. *Arch Physiol* 1906;297:354.
4. Schruppf P. De l'interference de deuzrythmes sinus aux; preuve due dualisme du nodule de Keith. *Arch Mal Coeur* 1920;13:168-173.
5. Sklyar E, Hollander G. Is this atrial parasystole, atrial dissociation, or an artifact? *J Electrocardiol* 2007;40(2):133-4.
6. Moore PR, Rowlands DJ. Re: Is this atrial parasystole, atrial dissociation, or an artifact? *J Electrocardiol* 2007;40(6):478.
7. Khan AH. Atrial dissociation. *Br Heart J* 1972;34(12):1308-10.
8. Cohen J, Scherf D. Complete Interatrial and Intra-atrial Block (Atrial Dissociation). *Am Heart J* 1965;70(1):23-34.