

## Atypical Respiratory Distress in a Newborn: a Diagnostic Dilemma

Pranab Kumar Dey<sup>1</sup>, Biswajit Mondal<sup>2</sup>, and Nilay Ranjan Bagchi<sup>2</sup>

<sup>1</sup>Department of Pediatrics, Midnapur Medical College, West Bengal, India

<sup>2</sup>Department of Pediatrics, Medical College, Kolkata, West Bengal, India

Received: 17 Mar. 2013; Received in revised form: 15 Jun. 2013; Accepted: 22 Jun. 2013

**Abstract-** Neonatal respiratory distress is a very common problem in our practice. The causes may be respiratory, cardiovascular, central, metabolic, haematological and surgical. The cause of distress due to transient myocardial depression is not very common in mild asphyxia. We present a case having transient myocardial depression with severe respiratory distress and features of shock in a mild asphyxiated baby.

© 2014 Tehran University of Medical Sciences. All rights reserved.

*Acta Medica Iranica*, 2014;52(7):575-577.

**Keywords:** Respiratory Distress; Shock; Myocardial depression; Metabolic acidosis

### Introduction

Respiratory distress is a very commonly encountered problem in newborn (1). The causes may be respiratory, cardiovascular, central, metabolic, haematological and surgical (2). In asphyxiated mature newborn infants a syndrome of cyanosis, congestive failure, and acute left ventricular failure can occur which mimicking severe congenital heart disease (3). It is postulated that the disorder is one of impaired coronary perfusion to portions of the right and left ventricular myocardium through increased work demands created by unusually brisk pulmonary vasoconstriction from hypoxia (3, 4).

This report describes a term male baby with severe respiratory distress, presenting at 14 hours of age with cyanosis, grunting respiration, shock and metabolic acidosis without any respiratory acidosis. This infant improved with conservative management.

### Case Report

A term male baby of birth weight of 2.5 kg, born out of vaginal delivery of a mother aged 20 years was received at the age of 7 hours, and examination findings revealed only tachypnea (respiratory distress score 1) without grunting and subcostal retraction at that time. Routine supportive care was given to the baby.

The antenatal history is uneventful except mild pallor and bilateral pedal edema. The mother's height was 4 feet 7 inches and weight was 44 kg. According to the mother's previous issue died at the age of 3 days due to respiratory difficulty and heart cause. Regarding perinatal period

there was no significant history or finding except the baby cried few minutes late after birth.

At the age of 14 hours, the baby suddenly developed severe respiratory distress along with cyanosis, grunting, chest indrawing and capillary refill time of 6 secs. He had depressed cry and activity with weak sucking reflex and hyperactive stretch reflexes. Liver was palpable 4 cm below right costal margin. He was treated with moist oxygen, bolus of normal saline along with dopamine and intravenous antibiotics. There was metabolic acidosis with Ph 7.2, Hco316, and PCo240 and anion gap 16. Capillary blood glucose and serum electrolytes were within normal limit. Serum ammonia level 90 microgram/dl, lactate 1.5 mmol/L and no reducing sugar and ketones in the urine.

At 48 hours X-Ray (Figure 1) chest showed mild hyperinflation of lung field. Routine blood test including blood culture was normal except increased BUN (28mg/dl) and creatinine (1.2 mg/dl).

Electrocardiography (Figure 2) showed ST depression on cardiac monitoring.

At 96 hours, total CPK was 410 IU/l. Cardiac troponin (cTnT) level was 0.18mcg/L.

Echocardiography was done after stabilization of the patient who shows patent foramen ovale and mild tricuspid regurgitation. Cranial USG was normal. Conservative managements continued, but the baby's condition remained the same until 106 hours. Then the baby started improving.

Meanwhile, metabolic screens showed no abnormality and BUN, creatinine levels returned to the normal range. On day 6, the baby became asymptomatic

**Corresponding Author:** P. Kumar Dey

Department of Pediatrics, Midnapur Medical College, West Bengal, India

Tel: +91 890 2365478, Fax: +91 332 2123780, E-mail address: drpranabdey@gmail.com

## Atypical respiratory distress in a newborn

and hemodynamically stable.

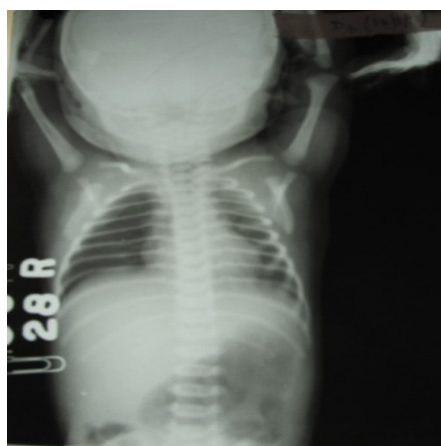


Figure 1. CXR (PA) View-showing hyperinflation of lung (At 48 hrs)

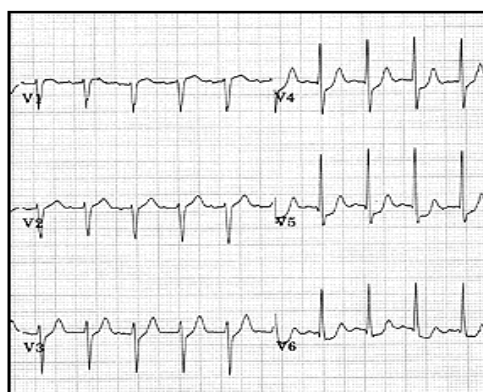


Figure 2. Electrocardiography showed ST segment depression (At 72 hrs)

## Discussion

Regarding the approach of respiratory distress in term baby's etiology could differ depending on the time of onset of distress. If the baby has tachypnea beginning at birth, the causes could be Transient tachypnea in newborn or secondary to polycythemia. If the distress begins early but is more severe it may be due to meconium aspiration syndrome, pneumonia, asphyxia or malformations. If the distress occurs at the end of the first week or later the cause would be most probable pneumonia. However, if a baby is having hepatomegaly or is in shock one needs to think of a cardiac cause. On the other hand if the baby is dehydrated and in shock, a possibility of metabolic acidosis needs to be considered.

Keeping the above background in mind what might be the possibilities here?

Most of the findings are consistent with birth asphyxia with transient myocardial ischemia except

there was no history of seizure or apnea, and there was a rapid recovery of the case.

Transient tachypnea of newborn (TTN) especially malignant type may be a possibility though the presentation was late here (at 14 hours), x-ray not typical, and there was metabolic acidosis which is not usually present in TTN (5,6).

Pneumonia excluded as chest X-Ray not suggestive; sepsis screen was normal, and blood culture showed no growth (7,8).

Congenital Cyanotic Heart disease excluded as echocardiography shows only patent foramen ovale and mild tricuspid regurgitation and pre and post ductal oxygen saturation having no difference (8).

Meconium Aspiration Syndrome - There was no history, and no clinical finding of meconium-stained amniotic fluid (2,5).

Respiratory distress syndrome in term was a rare possibility in this case (5).

Metabolic screening was normal and excludes any metabolic disease.

Though malignant TTN was a strong possibility but after all these discussion this case seemed to be most probably a case of asphyxia induced myocardial depression which leads to hepatomegaly, shock, metabolic acidosis along with cyanosis and respiratory distress in this term baby (9). Cardiac troponin level and CPK-MB enzymatic study of myocardial ischemia confirmed this diagnosis (10).

## Acknowledgment

BM and PKD were involved in diagnosis, management and initial preparation of the manuscript. NRB and PKD were reviewed literatures. PKD involved in the revision of the manuscript and will act as the guarantor of the paper.

## References

1. Neonatal morbidity and mortality. Report of the National Neonatal Perinatal database. *Indian Pediatr* 1997;34(11):1039-42.
2. Barbara J. Stoll, Ira Adams-Chapman. Delivery Room Emergency. In: Klieman RM, Behrman RE, Jenson HB, et al, editors. *Nelson Textbook of Pediatrics*. 18th ed. Philadelphia: Saunders; 2007: p. 723-6.
3. Rowe RD, Hoffman T. Transient myocardial ischemia of the newborn infant: A form of severe cardiorespiratory distress in full-term infants. *J Pediatr* 1972;81(2): 243-50.

4. Ranjit MS. Cardiac abnormalities in birth asphyxia. *Indian J Pediatr* 2000;67(3 Suppl):S26-9.
5. Bhakta KY. Respiratory Distress Syndrome. In: Cloherty JP, Stark AR, et al, editors. *Manual of Neonatal Care*. 18th ed. Philadelphia: Lipincott Williams; 2008: p. 323-30.
6. Kumar P, Kumar R, Narang A. Spectrum of neonatal respiratory distress at PGI. *Bull NNF* 1999;13(4):8-11.
7. Singhi S, Singhi PD. Clinical signs in neonatal pneumonia. *Lancet* 1990;336(8722):1072-3.
8. Christian L. Hermansen, Kevin N. Lorah, Respiratory Distress in the Newborn. *Am Fam Physician* 2007;76(7):987-94.
9. Respiratory distress in a newborn baby. WHO Collaborating Center for Training and Research in Newborn Care. (Accessed in Feb 14, 2014, at [www.newbornwhocc.org/pdf/teaching-aids/respiratorydistress.pdf](http://www.newbornwhocc.org/pdf/teaching-aids/respiratorydistress.pdf)).
10. Barberi I, Calabro MP, Cordaro S, et al. Myocardial ischaemia in neonates with perinatal asphyxia. Electrocardiographic, echocardiographic and enzymatic correlations. *Eur J Pediatr* 1999; 158(9): 742-7.