

Successful Airway Management in a Patient with Tracheal Stenosis and Tracheoesophageal Fistula: a Case Report

Hamid Reza Davari and Sahar Latifi

Department of Thoracic Surgery, Imam Khomeini Hospital, Tehran University of Medical Sciences, Tehran, Iran

Received: 20 Nov. 2012; Accepted: 21 Sep. 2013

Abstract- A twenty-year-old girl was referred with tracheal stenosis (TS) which was a consequence of prolonged intubation after head injury because of previous car accident. The patient was aphasic and had normal respiration. Fiberoptic bronchoscopy showed complete tracheal obstruction at second tracheal ring level. Distal trachea was normal through tracheostomy tube. Removal of the tracheostomy tube and blind reinsertion with a new one was complicated with hypoxia and respiratory distress. Fibrotic bronchoscopy revealed large tracheoesophageal fistula (TEF) below tracheal obstruction. Reinsertion of the tracheostomy tube by fiber optic bronchoscope was successful. Multidetector CT scan was performed on the same day with confirmation of TS combined with TEF. Surgery was performed on the next day. No clinical evidence of TEF was found in back history. Inadequate evaluation of the whole length of the trachea during the first bronchoscopy was the reasons for missing TEF. TEF should be considered in patients with TS in spite of no typical symptom such as food aspiration or pulmonary infections.

© 2014 Tehran University of Medical Sciences. All rights reserved.

Acta Medica Iranica, 2014;52(7):565-568.

Keywords: Tracheoesophageal fistula; Tracheal stenosis; Tracheostomy; Airway management

Introduction

Although acquired tracheoesophageal Fistula Tracheoesophageal Fistula (TEF) is a rare complication, many variable causes are shown to play a part in such a complication. Intubation with cuff-related tracheal injury is the most common etiology of non-malignant TEF. The coincidence of TEF with Tracheal Stenosis (TS) is not frequent (1).

This article describes a patient with tracheal stenosis and simultaneous TEF with no typical symptoms such as food aspiration and pulmonary infection. Acquired TEFs also can be diagnosed during direct visualization by flexible bronchoscopy or esophagoscopy.

Both of methods can be useful, depending on the individual expertise and experience. It usually can be confirmed by radiologic contrast study, direct endoscopic visualization or installation of methylene blue in esophagus and bronchoscopy. Gastric air analysis is suggested to diagnose TEF in some situations such as ICU patient (4,5). These techniques are also helpful to differentiate TEF in patient on mechanical ventilation from paralytic ileus (5).

Case Report

A 20-year-old girl was referred with tracheal stenosis to Imam Khomeini Hospital. Previous history showed that the patient was intubated about three weeks because of car accident and followed diffuse compact head injury. Tracheotomy was set after extubation for eight months. Tracheotomy tube was only changed once about four months before administration in our hospital. The patient was aphasic without any other problem including dysphasia, difficulty in swallowing or respiratory symptoms. She was visited in a Day clinic; fiberoptic bronchoscopy showed normal function of vocal cords, normal subglottic area and a complete tracheal obstruction distal to second tracheal ring. Through the tracheotomy tube distal part of the trachea was normal with no evidence of abnormal secretion. Full evaluation was postponed. We only changed tracheotomy tube with a new one since it was left in place for more than four months. Within few minutes, the patient developed respiratory distress and hypoxia. It was removed immediately, and she had normal breathing through tracheal stoma. Re-bronchoscopy through cervical stoma showed tracheoesophageal

Corresponding Author: S. Latifi

Thoracic ward, Valiasr Hospital, Imam Khomeini Hospital Complex, Keshavarz BLV, Tehran University of medical Sciences, Tehran, Iran
Tel: +98 912 5353259, Fax: +98 21 66581543, E-mail address: saharlatifi_med@yahoo.com

Tracheal stenosis and tracheoepophageal fistula

fistula with length about three cm just distal to the stoma. Removing the old tube caused TEF to be exposed and further blind efforts to insert new tube led to inappropriate esophageal intubation. Blind insertion of tracheotomy was failed. Therefore reinsertion of the tracheostomy tube was guided by fiber optic

bronchoscope. It was the only way to restore airway patency. Multidetector (MDCT) CT scan (figure 1 and 2) and virtual bronchoscopy were requested. Tracheal stenosis was reported which was 25.7 mm distal to vocal cord with amorphous calcification. The length of stenosis to the cervical tracheal stoma was 17.4 mm.

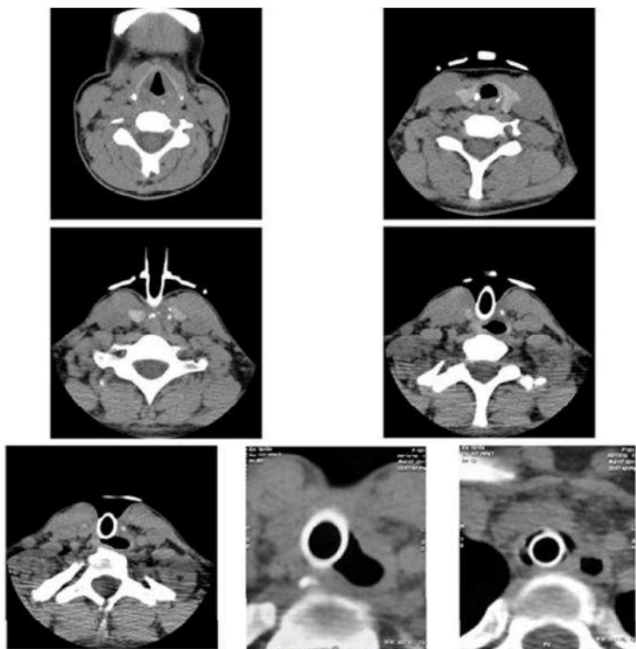


Figure 1. MDT Scan (axial images)

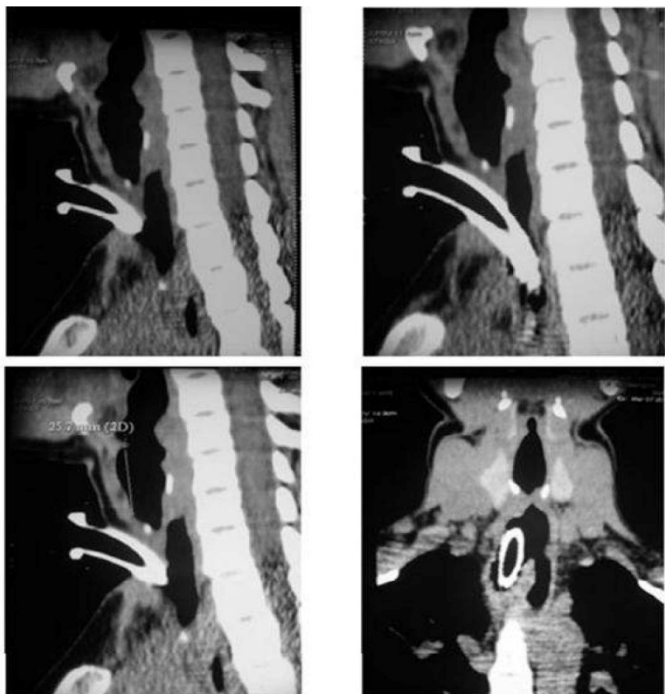


Figure 2. MDCT Scan (coronal and sagittal images)

Hyperinflation of esophagus and defect of tracheoesophageal septum were found in MDCT scan. Next day, she underwent an operation through cervicodiaphragmatic approach. Four centimeters of tracheal (= 8 rings) were resected with end to end tracheotracheal anastomosis. Esophageal defect was repaired in two layers and supported by sternohyoid muscle flap. Most of fibrotic segment of trachea was left on esophageal side during dissection in order to avoid esophageal stricture. Four days after operation nasogastric tube was discontinued. Oral feeding was started on day seven after contrast study revealed no evidence of leakage. She discharged 10 days after admission.

Discussion

The coincidence of TEF with TS is not frequent. Fiala and et al. reported five cases in a series of 51 patients with tracheal stenosis (1). According to this review study, some authors have not mentioned any cases of TEF in their reports during TS repairing. On the other hand, a simultaneous incidence of TEF and TS is reported in Grillo study as he described 20 cases in 521 patients with TS (2). Tracheoesophageal fistula may be suspected in different circumstances, but the most common scenario occurs in patients who require prolonged mechanical ventilation while a nasogastric tube is placed (3). Common manifestation is a sudden, massive, bloated abdomen because of gas insertion from the trachea into the lower gastrointestinal tract. Frequent aspiration of food or gastrointestinal secretions leads to repeated and unexplained pulmonary infections which dominantly involve lower lobes. Sometimes inadequate arterial oxygen saturation cannot be obtained in spite of aggressive ventilation. This patient had no typical symptoms such as aspirations or pulmonary infections. It could be because of complete obstruction of the trachea below vocal cord and sealed off TEF by tracheostomy tube. In fact TEF was exposed and diagnosed after removing the old tracheostomy and trying to insert a new one. Fiberoptic bronchoscopy was performed without removal of the tracheotomy tube, and some length of the trachea was skipped from direct visualization. Therefore, diagnosis of TEF was missed in the first bronchoscopy. It is highly recommended to remove the tracheotomy tube and evaluate the whole length of the trachea. Some small TEF mostly in lateral parts of cartilage junction to the membranous portion of the trachea may also be missed. In our patient TEF

diagnosis was missed because of sealing effect of previous tracheal tube but, on the other hand, moderate hyper aeration of esophagus and wall defects between trachea and esophagus were clearly seen on MDCT Scan.

We usually have problems in intubation and ventilation management in patients with TEF. Insertion of the tracheotomy tube and inflation of tracheal cuff distal to fistula tract or sometimes insertion of temporary Montgomery laryngeal T tube with gastrostomy and jejunostomy may be considered (6). In complicated cases, tracheal intubation can be performed under the guidance of fiber optic bronchoscope. Ventilation maintenance through esophagus by intubation of the distal trachea when proximal trachea is destructed is possible which is described by Maseda *et al.*, (7). In this case, blind reinsertion of the tracheostomy tube was failed; therefore, tracheostomy tube was inserted under the guidance of fiber optic bronchoscopy. During the surgery, it was replaced with armored tracheal tube (tube number 7.5). Airway protection and ventilation maintenance are mandatory, but the time of definitive surgery is controversial due to differently surgical approaches for TEF with or without combined TS (8).

Acknowledgment

We like to thank the thoracic surgery team of Valiasr hospital in Imam Khomeini complex for their efforts in patient management.

References

1. Fiala P, Cernohorsky S, Cermák J, et al. Tracheal stenosis complicated with tracheoesophageal fistula. *Eur J Cardiothorac Surg* 2004;25(1):127-30.
2. Grillo HC, Donahue DM, Mathisen DJ, et al. Postintubation tracheal stenosis. Treatment and results. *J Thorac Cardiovas Surg* 1995;109(3):486-93.
3. Dartevelle P, Macchiarini P. Management of acquired tracheoesophageal fistula. *Chest Surg Clin N Am* 1996;6(4):819-36.
4. Rampaul RS, Naraynsingh V, Dean VS. Tracheoesophageal Fistula Following Blunt Chest Trauma: Diagnosis in the ICU--the "Breathing Bag" Sign. *Chest* 1999;116(1):267.
5. Kovitz KL, Siebens R, Brower RG. Diagnosis of tracheoesophageal fistula by analysis of Fgastric air. *Chest* 1993;104(2):641-2.
6. Maceda E, Diaz Agero P, Sumz L, et al. Tracheal

Tracheal stenosis and tracheoepophageal fistula

intubation through trachea-esophageal fistula. *Anesth Analg* 1995;80:422-3.

7. Krajc T, Janik M, Benej R, et al. Urgent segmental resection as the primary strategy in management of benign tracheal stenosis. A single center experience in 164 consecutive cases. *Interact Cardiovasc Thorac Surg* 2009;9(6):983-9.
8. Yeh CM, Chou CM. Early Repair of Acquired Tracheoesophageal Fistula. *Asian Cardiovasc Thorac Ann* 2008;16(4):318-20.