

An Unusual Presentation of Ossified Intramuscular Hemangioma: a Case Report

Khodamorad Jamshidi¹, Dawood Jafari¹, Mehdi Ramezan Shirazi²,
Alireza Pahlevansabagh^{1*}, and Tina Shoushtaryzadeh²

¹ Department of Orthopaedic Surgery, Faculty of Medicine, Iran University of Medical Sciences, Tehran, Iran

² Department of Pathology, Faculty of Medicine, Iran University of Medical Sciences, Tehran, Iran

Received: 18 Jan. 2013; Accepted: 19 May 2013

Abstract—Intramuscular cavernous hemangiomas represent less than 1% of all hemangiomas. Typical presentation is a soft-tissue mass and/or pain without cutaneous changes. Whereas calcification of hemangiomas is common; ossification of these lesions is very rare. We describe a case of ossified intramuscular hemangioma of quadriceps presented with painless knee extension contracture and thigh mass.

© 2014 Tehran University of Medical Sciences. All rights reserved.

Acta Medica Iranica, 2014;52(4):319-322.

Keywords: Hemangioma; Skeletal muscle; Ossification; Extension contracture; Quadriceps muscle

Introduction

Hemangioma is a common soft-tissue tumor but intramuscular hemangioma is rare, accounting for 0.8% of these (1). The first description of a case of intramuscular hemangioma is attributed to Liston in 1843, which called this “erectile tumor” (2). Most patients present with a mass and/or pain, which often aggravate with activity (1, 3). It usually occurs before the age of 30 (3-5). Most authors report equal sex distribution (6, 7). The aetiology of intramuscular hemangiomas remains unknown. Several cases have been attributed to previous trauma (8), whereas others have predominately ascribed them to congenital theories (7).

Calcification within hemangioma is a common finding; but ossifications within the intramuscular hemangioma of the extremities are rarely reported (9-13). Surgical excision is the treatment of choice for symptomatic lesions, but there are certain cases in which excision is not possible. In difficult cases, other treatment alternatives such as sclerotherapy have been used (8).

We describe a unique case of an ossified hemangioma in the right quadriceps presented with extension knee contracture and thigh mass. The radiologic, magnetic resonance (MR), scintigraphic, angiographic and histologic features are discussed.

Case Report

Written consent for this case report was obtained from the patient.

A 26-years-old man presented to our institute with progressive and painless right knee extension contracture. He was a non-smoker manual labourer who came from Afghanistan. The patient noticed a soft tissue mass in the anterior aspect of his right thigh 8 years ago. No history of trauma or infection prior to the appearance of the mass was reported. He denied family history of soft-tissue masses. Incisional biopsy was performed six years ago in other center and pathological diagnosis of intramuscular hemangioma was made. He denied any surgical treatment since that time. Afterwards, he noted gradual development of extension contracture in his right knee.

On physical examination, a large, well-defined non tender firm mass was palpable in the lateral, anterior and medial aspect of the right thigh measuring about 25 cm × 9 cm. The right knee was fixed in full extension. Motion of the hip and ankle joints was normal. No inflammatory signs, skin changes or adenopathies were observed. No bruits were heard on auscultation. Neurovascular examination and laboratory findings were within normal limits.

Radiographic examination revealed large soft tissue mass with linear and streak-like ossification around the

Corresponding Author: A. Pahlevansabagh

Department of Orthopaedic Surgery, Faculty of Medicine, Iran University of Medical Sciences, Tehran, Iran
Tel: +98 21 33542022, Fax: +98 21 33542022, E-mail address: pahlevan.ar@iums.ac.ir

right femur (Figures 1a, 1b).

Non-enhancement MRI showed a large mass of quadriceps muscle with almost completely infiltration. T1-weighted MR images revealed isointense areas compared to skeletal muscle, surrounded by

inhomogeneous hyperintense areas (Figure 2a). T2-weighted images demonstrated a high signal intensity mass with low signal intensity lace-like structures within that (Figure 2b). The femur marrow showed normal signal intensity.

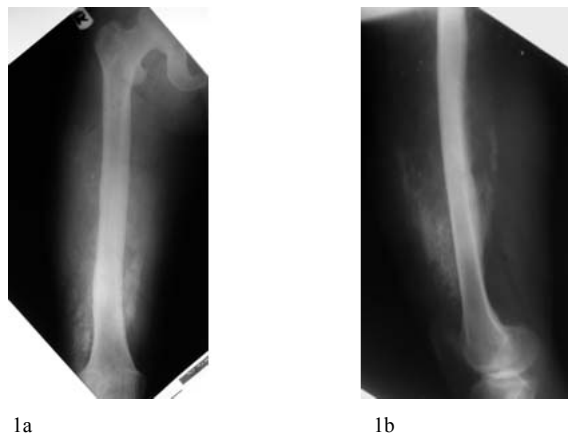


Figure 1. AP (1a) and lateral (1b) radiographs show an osseous soft tissue mass in the anterior aspect of the right femur with linear and streak-like ossification.

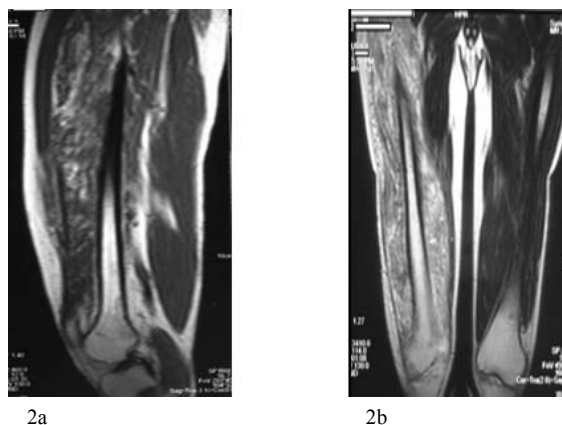


Figure 2. MR findings of the lesion. (2a) a coronal T1-weighted MR image shows an isointense area compared to skeletal muscle surrounded by inhomogeneous hyperintense areas. (2b) a sagittal T2-weighted MR image demonstrated a high signal intensity mass with low signal intensity lace-like structures within that

A Tc 99 pyrophosphate bone scan showed increased activity in the right thigh corresponding to the site of the lesion. Angiography was performed that demonstrated vascular malformations with normal arterial findings (Figures 3a, 3b).

Because of patient symptoms and previous histopathologic diagnosis of intramuscular hemangioma, the patient underwent wide resection of the tumor. Through a 40 cm longitudinal incision across the anterolateral border of the thigh, the quadriceps muscle was exposed. After incision of rectus femoris, the lesion was found corresponding to the MRI findings. The mass was completely infiltrated vastus intermedius and vastus lateralis and partially vastus medialis and not attached to

the bone or periosteum. The lesion was completely removed with wide surgical margins. The knee gained 110 degree flexion intraoperatively. Gross examination after longitudinal section of the specimen demonstrated a segment of skeletal muscle, containing ill-defined red-brown vascular lesions with irregularly shaped bone trabeculae (Figure 4).

Histopathologically, the biopsy displayed infiltration of skeletal muscle by thin-walled large caliber blood vessels lined by benign endothelial cells associated by large amount of mature adipose tissue and thick, mature lamellar bones (Figure 5a, 5b).

A histologic diagnosis of intramuscular hemangioma with ossification was made. At the time of recent follow

up after one year from the operation, no local recurrence of the tumor was demonstrated clinically and radiographically. Range of motion of the involved knee

was 0 to 80 degree and quadriceps force was III/V. The patient had given way sensation after short distance walking.

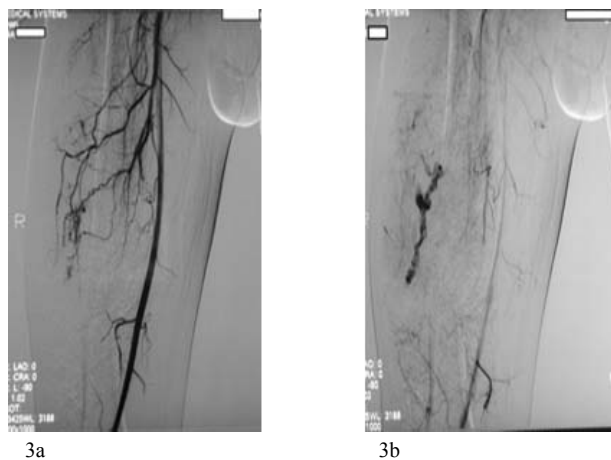


Figure 3. 3a and 3b Angiography shows vascular malformations with normal arterial findings in the right thigh

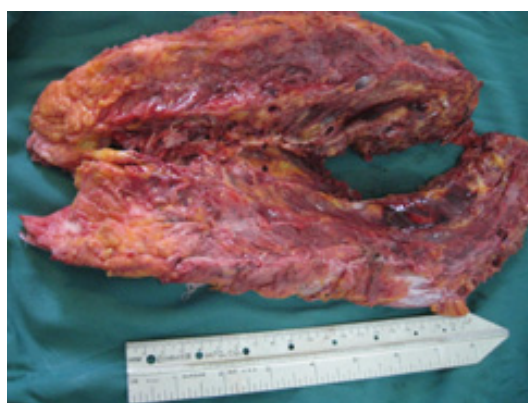

Figure 4. Gross appearance of the specimen after longitudinal section

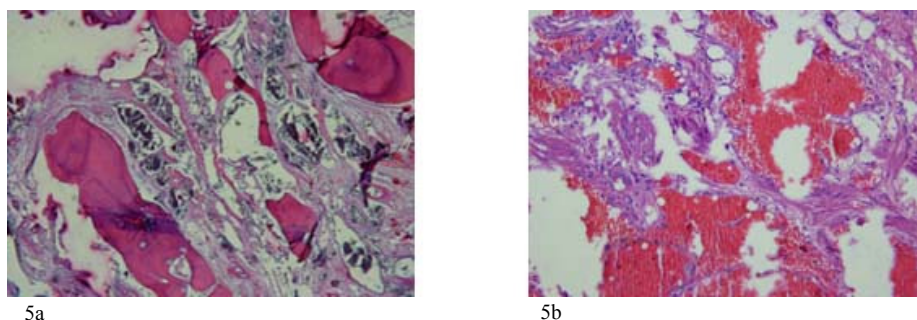


Figure 5. Histologic findings of the lesion. (5a) The lesion consists of thick, mature bones and (5b) numerous dilated vascular channels lined by benign endothelial cells infiltrated of skeletal muscle (hematoxylin and eosin).

Discussion

Watson and McCarthy (14) reviewed 1308 hemangiomas and found intramuscular type in 0.8% of these tumors. The majority of tumors are located in the lower extremities. They usually present as slowly

enlarging soft tissue masses with few symptoms (13). Calcification in hemangiomas is commonly detected and can be of several types. Radiographically, amorphous or curvilinear calcification is observed. In addition, various-sized, rounded phleboliths are frequent and characteristic of soft tissue hemangiomas (15). They are

more commonly observed in a cavernous type of hemangioma and are the result of dystrophic calcification within organizing thrombi (15). Ossification in the skeletal muscle hemangiomas is a rare phenomenon and infrequently described (9-13). The first case of an ossified intramuscular hemangioma was reported as an orange-sized swelling in the right posterior lower leg of a 19 year old patient by Bishop in 1963 (9). Intramuscular hemangiomas can be either asymptomatic or symptomatic including pain, increased girth of the extremity or swelling and increased temperature or discoloration of the overlying skin. A palpable mass is seen in the vast majority of the cases. Larger hemangiomas may be associated with a bruit or thrill. Superficial dilated veins may also be seen with cutaneous extension. These symptoms were commonly present for many years prior to diagnosis. To the best of our knowledge, ossified intramuscular hemangioma resulting in painless extension contracture of the knee has not been previously reported in the literature.

The radiologic differential diagnoses of ossified intramuscular hemangioma include myositis ossificans, ossifying fibromyxoid tumor, fibrodysplasia ossificans, and extra skeletal osteosarcoma (13). X-Rays of ossified intramuscular hemangiomas showed irregularly ossified lesions in the soft tissues, the so-called "Swiss cheese" appearance described by Engelstad et al (11). This appearance reflects the architecture of the mature bone interspersed with large cavernous vascular channels. In contrast to the appearance described by Engelstad et al, Swiss-cheese-like appearance was not detected radiographically in our case and Linear and streak-like calcification was seen radiographically in this case.

Observation remains an option for asymptomatic intramuscular hemangiomas. Common further indications for surgery include persistent pain, progressive increase in size of the mass, functional impairment and patient anxiety (16).

In summary, we reported a case of ossified intramuscular hemangioma with its peculiar clinical and radiologic features which shows a rare variant of a relatively common tumor.

References

1. Wild AT, Raab P, Krauspe R. Hemangioma of skeletal

- muscle. *Arch Orthop Trauma Surg* 2000;120(3-4):139-43.
2. Ferri E, Pavon I, Armato E. Intramuscular cavernous hemangioma of the sternocleidomastoid muscle: an unusual neck mass. *Otolaryngol Head Neck Surg* 2007;137(4):682-3.
3. Allen PW, Enzinger FM. Hemangioma of skeletal muscle: an analysis of 89 cases. *Cancer* 1972;29(1):8-22.
4. Horowitz SM, Epstein RE, Dalinka MK, et al. Knee pain in a 20-year-old woman. *Clin Orthop Relat Res* 1996;329:337-8,41-2.
5. Nack J, Gustafson L. Intramuscular hemangioma: case report and literature review. *J Am Podiatr Med Assoc* 1990;80(8):441-3.
6. Brown RA, Crichton K, Malouf GM. Intramuscular haemangioma of the thigh in a basketball player. *Br J Sports Med* 2004;38(3):346-8.
7. Scott JE. Haemangiomas in skeletal muscle. *Br J Surg* 1957;44(187):496-501.
8. Chaudhary N, Jain A, Gudwani S, et al. Intramuscular haemangioma of head and neck region. *J Laryngol Otol* 1998;112(12):1199-1201.
9. Bishop BWF. Hemangioma of voluntary muscle. *Br J Surg* 1936;24(93):190-1.
10. Jiang TT, Cisa J, Desai P, et al. Intramuscular ossified hemangioma. *Skeletal Radiol* 1995;24(7):538-40.
11. Engelstad BL, Gilula LA, Kyriakos M. Ossified skeletal muscle hemangioma: radiologic and pathologic features. *Skeletal Radiol* 1980;5(1):35-40.
12. Hoag GN, Murphy MM, Major PA. Ossified skeletal muscle angioma: report of two cases. *J Surg Oncol* 1984;25(1):34-7.
13. Nagira K, Yamamoto T, Marui T, et al. Ossified intramuscular hemangioma: Multimodality imaging findings. *Clin Imag* 2001;25(5):368-72.
14. Watson WL, McCarthy WD. Blood and lymph vessel tumors. *Surg Gynecol Obstet* 1940;71:569-88.
15. Enzinger FM, Weiss SW. Benign tumors and tumorlike lesions of blood vessels. In: Enzinger FM and Weiss SW, editors. *Soft tissue tumors*. 3rd ed. St Louis: Mosby; 1995: p. 579-626.
16. Griffin N, Khan N, Thomas JM, et al. The radiological manifestations of intramuscular haemangiomas in adults: magnetic resonance imaging, computed tomography and ultrasound appearances. *Skeletal Radiol* 2007;36(11):1051-9.