

Internal Jugular Catheter Malposition in a Patient with End Stage Renal Disease: a Case Report

Farzaneh Ebrahimifard¹, Amir Shirvani², Shahab Abtahi², and Ali Setayesh³

¹ Department of General Surgery, Faculty of Medicine, Shahid Beheshti University of Medical Sciences, Tehran, Iran

² Department of General Physician, Faculty of Medicine, Tehran University of Medical Sciences, Tehran, Iran

³ Department of General Surgery, Faculty of Medicine, Tehran University of Medical Sciences, Tehran, Iran

Received: 21 Mar. 2013; Accepted: 3 Dec. 2013

Abstract- A 30-year-old female with end-stage renal disease was a candidate for dual lumen catheter placement. After catheter insertion, O₂ saturation measurement of the aspirated blood from the catheter was similar to that of arterial blood. They referred the patient to our hospital after 48 hours. Diagnostic procedures revealed that the tip of the catheter had entered the pleural cavity. Catheter removal in the CPR room resulted in hemorrhagic shock. The patient was resuscitated and stabilized and sent to the operating room. A laceration found at the junction of right jugular and right subclavian veins and was surgically repaired. The patient was discharged after ten days without any complication.

© 2014 Tehran University of Medical Sciences. All rights reserved.

Acta Medica Iranica, 2012;52(9):721-724.

Keywords: Dual-lumen catheter; Malposition; Complications; Internal jugular vein

Introduction

Central venous catheterization is a common method of vascular access for temporal or long-term hemodialysis. Lethal complications including arterial puncture, injury of great vessels, cardiac tamponade, and pneumothorax or hemothorax have been reported to occur in 6.2–10.7% of patients (1). All these complications need immediate interventions.

Case Report

A nephrology fellow placed a dual lumen catheter in a 30-year-old woman at the site of right internal jugular vein. She had end-stage renal disease (ESRD), and hemodialysis was mandatory due to her uremic state. Method utilized to place the catheter is uncertain as the patient was catheterized in another hospital. According to their reports, O₂ saturation measurements of the aspirated blood from the catheter was similar to that of arterial blood. They concluded that the catheter has entered an artery decided to refer the patient to another hospital due to the lack of an expert in vascular surgery. But the referral process took them about 48 hours.

When the patient entered the emergency department (ED) of our hospital, she was complaining from pain at the

site of catheter placement. No bulging or hematoma was present at the site of catheter insertion. The patient had no dyspnea, and her vital signs were stable with no signs of internal bleeding. Aspiration of the catheter revealed neither blood nor gas. According to previously obtained chest X-ray (CXR), the path of the catheter was not over the anatomical position of any great artery (Figure 1).

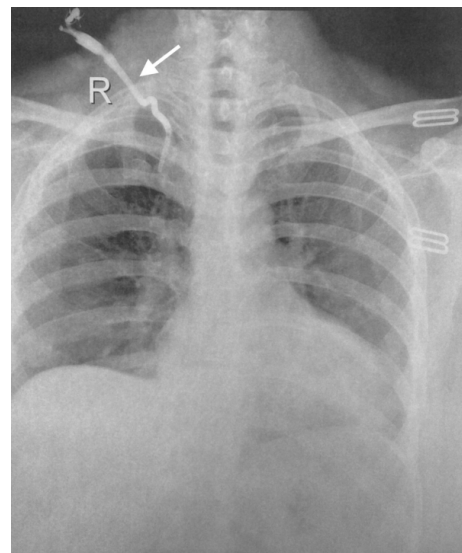


Figure 1. Chest X-ray demonstrating the path of the catheter (arrow)

Corresponding Author: A. Setayesh

Department of General Surgery, Faculty of Medicine, Tehran University of Medical Sciences, Tehran, Iran
Tel: +98 912 1902149, Fax: +98 21 22074101, E-mail address: dralissetayesh@yahoo.com

Internal jugular catheter malposition

Dye (10cc of Omnipaque®) was injected through each end the catheter and a portable chest X-ray (CXR) was obtained afterwards which demonstrated dye extravasation to the pleural cavity (chest radiography is considered the gold standard for detection of pneumothorax, hemothorax, or cardiac tamponade with injection of contrast media through the central venous catheter (2)). It was concluded that the tip of the catheter had entered the pleural cavity (Figure 2).

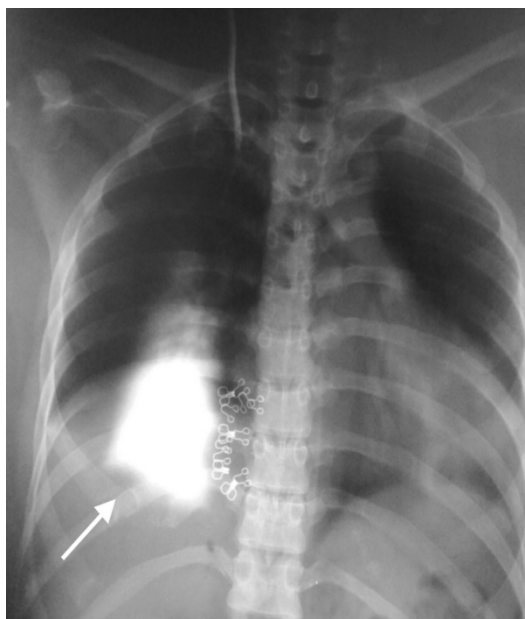

Figure 2. Chest X-ray obtained after dye injection shows dye distribution to the pleural cavity (arrow)

Decision was made to pull out the catheter under close monitoring in the CPR room of the ED. The catheter was pulled out, and local pressure was applied. After few minutes, the patient became pale accompanied by progressive dyspnea and low breath sound at the right side of the chest. The patient was intubated immediately, and a chest-tube was placed at the right side of the chest wall which directly drained off 2000ml of fresh blood. Blood pressure dropped down to the point in which no distal pulses were detectable, and the patient suddenly developed cardiac arrest. Cardio-pulmonary resuscitation (CPR) started immediately. With the impression of laceration of the great vessels at the base of the neck, anteromedial thoracotomy was performed by an incision at the right fourth intercostal space to reach the source of bleeding, and it was packed with sterile gauze. Hemostasis was successful, and the patient's heart began beating after five minutes of CPR and she started to breath actively. A femoral catheter was placed for fluid resuscitation as no other peripheral

vein was accessible. The patient transferred to the operation room (OR) after her systolic blood pressure reached 100mmHg.

At the OR, a medial sternotomy approach was used to reach the bleeding site. The incision was continued to the medial border of right sternocleidomastoid muscle. Right brachiocephalic, right carotid and right subclavian arteries were explored in their entire length, and there was no site of bleeding. But at the junction of right jugular and right subclavian veins a laceration with the length of 1cm was found and surgically repaired. The patient stabled hemodynamically and sent to the intensive care unit (ICU). She was discharged without any complication after ten days.

Discussion

Central venous catheterization is an inseparable component of hemodialysis. Percutaneous Seldinger technique based on anatomic landmarks is a method of choice at the absence of real-time ultrasound guidance (3). Perforation of the vessels is a rare but serious complication. Arterial injury (10.7%), hemothorax (0.5–1%), pneumothorax (1%), hemomediastinum (0.6%), arrhythmia (0.2%) and pericardial tamponade (0.8%) accounts for accidental puncture of the central vein (4). Perforation of a great vessel occurs most often when the right subclavian vein approach is used, largely in consequence of forced insertion of the vessel dilator which is inadvertently pushed too far (5). The most common complication associated with internal jugular vein catheterization is carotid artery puncture (6). Other sites of injury, where known, are the superior vena cava, subclavian vein, and left innominate vein (7) but our patient was suffered from a perforation in the junction of right subclavian and right internal jugular veins. As the catheter was left at its place for two days, It is likely that a tract was formed that could lead the blood to the pleura. On the other hand, negative pressure in the pleural cavity with simultaneous pressure over the insertion location led to passage of blood to the pleural cavity and its consequences.

Absence of dark blood in aspiration could be an early indicator of complications. External kinking, internal kinking or compression by the muscles, or a false lumen should be of concern in these situations as well as catheter malposition in which the general status of the patient could be altered. A CXR could be beneficial in this condition. Although immediate CXR cannot detect early signs of hemothorax, malposition of the catheter would be detected (8). When the tip of the

catheter is in the pleural cavity, and there is a chance of through and through perforation of the great vessels, we suggest a more accurate imaging technique like CT-angiography before catheter removal. No malpositioned catheter should be removed in places other than the OR with the availability of CPR settings. Remove the catheter while aspirating simultaneously and halt when blood is coming out of the catheter. At the presence of venous blood, the catheter position could be corrected with the aid of the guide wire under fluoroscopy.

Iatrogenic perforation of great vessels is a serious complication of dual lumen catheter insertion that could be fatal. Physicians should learn the techniques properly

and be aware of the complications while performing the procedure. A CXR after cannulation should be obtained to confirm the correct position of the catheter. Special attention must be paid to never miss a pneumothorax, hemothorax or extrapleural hematoma. We suggest the use of real-time ultrasound guidance when possible to minimise the risk of complications as well as recommended by other studies (9,10). At the presence of vessel perforation, immediate management and catheter removal should be performed in the OR by an expert surgeon. We recommend the following guideline when you face a malpositioned catheter (Figure 3).

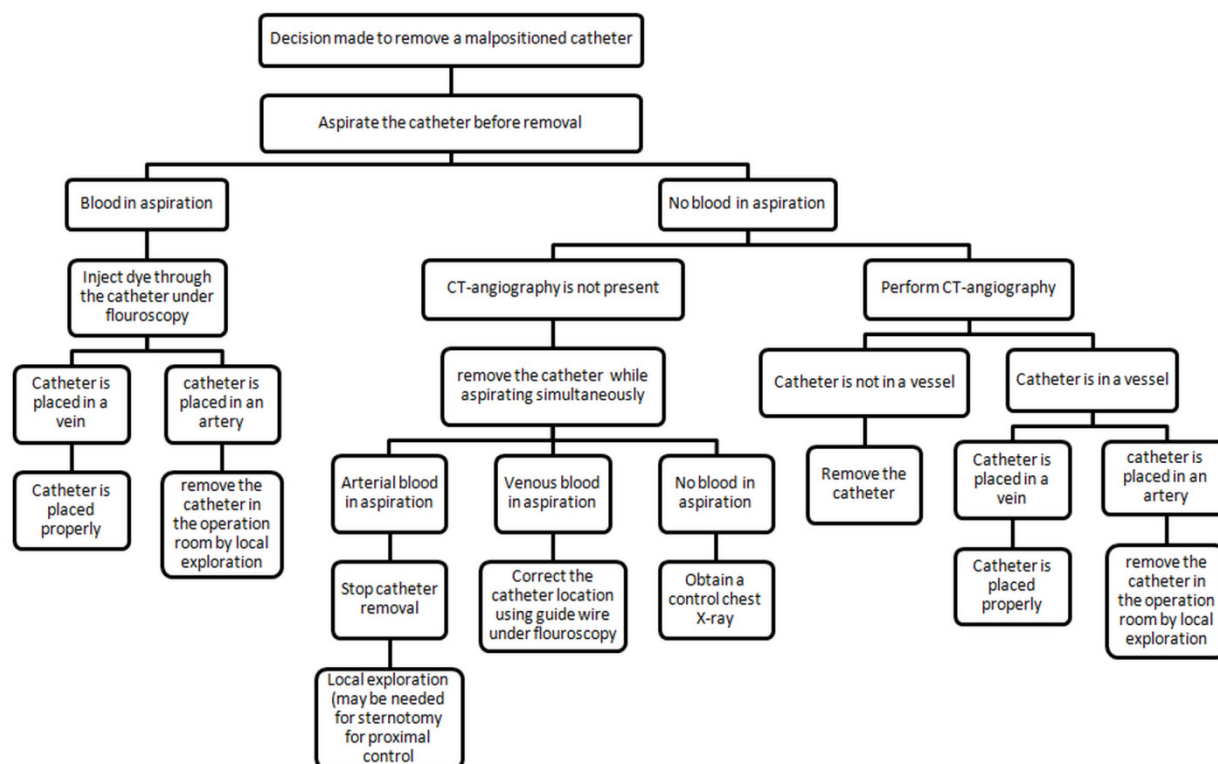


Figure 3. The following guideline is suggested to remove a malpositioned catheter

References

1. McGee DC, Gould MK. Preventing complications of central venous catheterization. *N Engl J Med* 2003;348(12):1123-33.
2. Krauss D, Schmidt GA. Cardiac tamponade and contralateral hemothorax after subclavian vein catheterization. *Chest* 1991;99(2):517-8.
3. Queiros J, Cabrita A, Maximino J, et al. Central catheters for hemodialysis: a six month experience of 103 catheters. *Nephrologie* 1994;15(2):113-5.
4. Kamran T, Zaheer K, Khan AA, et al. Applications and complications of subclavian vein catheterization for hemodialysis. *J Coll Physicians Surg Pak* 2003;13(1):40-3.
5. Oropello JM, Leibowitz AB, Manasia A, et al. Dilator-associated complications of central vein catheter insertion: possible mechanisms of injury and suggestions for prevention. *J Cardiothorac Vasc Anesth* 1996;10(5):634-7.
6. Kulvatunyou N, Heard SO, Bankey PE. A subclavian artery injury, secondary to internal jugular vein cannulation, is a predictable right-sided phenomenon. *Anesth Analg* 2002;95(3):564-6.
7. Domino KB, Bowdle TA, Posner KL, et al. Injuries and

Internal jugular catheter malposition

- liability related to central vascular catheters. A closed claims analysis. *Anesthesiology* 2004;100(6):1411-8.
8. Innami Y, Oyaizu T, Ouchi T, et al. Life-threatening hemothorax resulting from right brachiocephalic vein perforation during right internal jugular vein catheterization. *J Anesth* 2009;23(1):135-8.
 9. Skolnick ML. The role of sonography in the placement and management of jugular and subclavian central venous catheters. *AJR Am J Roentgenol* 1994;163(2):291-5.
 10. Randolph AG, Cook DJ, Gonzales CA, et al. Ultrasound guidance for placement of central venous catheters: a metaanalysis of the literature. *Crit Care Med* 1996;24(12):2053-8.