

# Acceleration of Skin Wound Healing with Tragacanth (*Astragalus*) Preparation: An Experimental Pilot Study in Rats

Ehsan Fayazzadeh<sup>1,2</sup>, Sina Rahimpour<sup>2</sup>, Seyed Mohsen Ahmadi<sup>1</sup>, Shahrokh Farzampour<sup>2</sup>,  
Maryam Sotoudeh Anvari<sup>1</sup>, Mohammad Ali Boroumand<sup>1</sup>, and Seyed Hossein Ahmadi<sup>1</sup>

<sup>1</sup> Tehran Heart Center, Tehran University of Medical Sciences, Tehran, Iran

<sup>2</sup> Animal Research Laboratory, Faculty of Medicine, Artesh University of Medical Sciences, Tehran, Iran

Received: 23 Aug. 2012 ; Received in revised form: ; Accepted: 1 Mar. 2013

**Abstract-** Gum tragacanth is a natural complex mixture of polysaccharides and alkaline minerals extracted from species of *Astragalus* plant, which is found widely in arid regions of the Middle East. In a pilot experimental study we examined the effects of its topical application on wound healing in ten albino adult male rats. Two similar parasagittal elliptical full-thickness wounds (control vs. test samples) were created on the dorsum of each animal. Test group samples were fully covered by a thin layer of gum tragacanth daily. The extent of wound healing was evaluated by planimetric analysis on multiple occasions during the 10-day study period. On the 7<sup>th</sup> day of the study, the percent of wound closure was significantly higher in gum tragacanth-treated specimens compared to the control samples (87%±2% vs. 70%±4%,  $P<0.001$ ). The majority of wounds in the test group were completely closed by the 10<sup>th</sup> day of the study. The difference in wound healing index measured by histological examination on day 10 of the study was also statistically meaningful between the two groups (0.624±0.097 vs. 0.255±0.063,  $P<0.05$ ). The results of this study clearly showed the useful effects of topical application of gum tragacanth in acceleration of skin wound contraction and healing. More studies are encouraged to identify the implicating agents and precisely understand the mechanism by which they exert their wound healing effects.

© 2014 Tehran University of Medical Sciences. All rights reserved.

*Acta Medica Iranica*, 2014; 52(1): 3-8.

**Keywords:** Astragalus; Tragacanth; Skin; Wound healing

## Introduction

Wound healing has historically been the focus of interest for many scientists. Since the pioneering research by Winter (1), the concept of wound dressings has been evolving from the traditional so-called passive products having a minimal role in the healing process to the functional more active materials which, through the interaction with the wounds they cover, establish and maintain an optimal environment for wound repair. An ideal wound dressing should protect the wound from bacterial infection, provide a moist and healing environment, and be safe and biocompatible (2).

Various polysaccharide biopolymers such as chitosan (3,4), alginate (5) and glycosaminoglycans (6), having hydrogel-forming properties, have been shown to be effective in their application as wound dressing materials. In the present study, we aimed to assess the applicability of a different arabinogalactan-based natural

material, namely tragacanth, as a dressing for wound occlusion and accelerator of the healing process. Gum tragacanth, an exudate of branches and roots used in the manufacturing of food pharmaceutical and industrial products because of its valuable hydrophilic and colloidal properties, is obtained from several tragacanth species of *Astragalus* occurring principally in the mountain regions of the Middle East (7). Tragacanth is a complex mixture of polysaccharides, which yields upon hydrolysis D-galacturonic acid, D-galactopyranose, L-fucose (6-deoxy-L-galactose), D-xylopyranose, L-arabinofuranose, and a very small amount of L-rhamnose. The acidic components are largely present as calcium, magnesium, and potassium salts. The gum also contains trace amounts of amino acids and their derivatives. It has a molecular weight of about 840,000 Dalton and an elongated shape of 4500Å by 19Å for a flake type of non-degraded gum. Tragacanth is considered to contain two primary constituents,

**Corresponding Author:** Ehsan Fayazzadeh

No. 89, block B1, Shahrak Ekbatan, Tehran, Iran, postal code: 13949-13356

Tel/Fax: +98 21 4464 1894, E-mail: efayazzadeh@razi.tums.ac.ir

## Gum tragacanth in skin wound repair in rats

tragacanthin and bassorin, which are both insoluble in alcohol and have high molecular weights. The minor component, tragacanthin, is a highly branched arabinogalactan and is soluble in water to give a colloidal hydrosol solution. It has a ring containing three molecules of galacturonic acid and one molecule of arabinose, with a side chain of two molecules of arabinose. The major component, bassorin, though insoluble in water, has the capacity to swell and form a gel. It is believed to contain polymethoxylated acids that yield tragacanthin upon demethoxylation. Gum tragacanth swells in cold water to give extremely viscous colloidal solutions (8-10). The wound-healing property of tragacanth has been evaluated in the current study using a rat model with full-thickness excisional skin wounds and histological examinations.

## Materials and Methods

Tragacanth gel 5% (w/v) was prepared by dissolving powdered tragacanth gum extracted from *Astragalus gummifer* (Iranian commercial market) in deionized water. Sterilization was performed by tendalization.

## Experimental design and procedure

The animal experiment was performed in accordance with "the Guide for the Care and Use of Laboratory Animals" published by the US National Institute of Health (NIH Publication No. 85-23, revised 1996). Ten albino rats weighing 250±50g (Wistar, male, 6-month-old, Inst. Pasteur Iran) were used in this study. After induction of anesthesia by intraperitoneal (ip) injection of ketamine (75 mg/kg) and xylazine (5 mg/kg), dorsal hair was clipped and the area was wiped with 70% (v/v) ethanol. The procedures were carried out on a warming blanket. Using a scalpel, two similar (15 mm) parasagittal full-thickness elliptical skin wounds, 3 cm away from each other, were created on the dorsum of each rat, thus each animal was its own control. Extreme caution was taken to avoid injuring the perforating vessels. About 250 µl of tragacanth gel was applied daily onto the right-side wound of each animal (test samples) for 10 days. The left-side control wounds received similar amounts of sterile deionized water. During the experiment, the rats were housed in separate metabolic cages with dust-free beddings. They were maintained at 22±2°C temperature, under 12h: 12h dark/light cycles and with free access to chew pellets and clean water. After 10 days, the animals were euthanized by lethal doses of sodium thiopental (250 mg/kg, ip injection).

## Clinical assessment

The wound sites were digitally photographed on days 0, 3, 7, and 10 after the initial procedure. The length and area of each wound was measured. As well, the percent of wound closure was calculated according to the following equation: % wound closure=  $[(S_0 - S_x) / S_0] \times 100$ , in which  $S_0$  and  $S_x$  are wound areas on the day of wound creation and the day of evaluation respectively. Planimetric calculations were made using Image J software (version 1.40 for Windows, NIH, Bethesda, USA).

## Histological examination

After the animals were sacrificed, 3×5 cm dorsal skin patches including the wounds were excised and fixed overnight in 10% (v/v) phosphate-buffered formaldehyde solution. The tissues were washed with PBS, embedded in paraffin, and sectioned in 10 µm increments. The sections were made perpendicular to the surface of the wounds. The sections were then positioned on a slide, and stained with hematoxylin and eosin (H&E) reagent. To analyze the degree of wound healing, central portions of the wounds were viewed under 40× magnification. The area of granulation tissue (consisting of fibroblasts and matrix deposits, inflammatory cells and blood vessels) was quantitatively evaluated by a color image analyzing software (E200, Nikon, Tokyo, Japan). Moreover, the area of new epithelium over the wound bed was measured in a similar way and the index of wound healing was calculated according to the following formula: wound healing index= epidermis area/ (granulation tissue area + epidermis area).

## Statistical analysis

All data are expressed as mean±standard error (SE) of mean. Differences between groups were determined by paired Student's t-test. *P*-values less than 0.05 were considered statistically significant. Computations were performed using the SPSS statistical software (version 15.0 for Windows, SPSS Inc., Chicago, USA).

## Results

### Macroscopic observations

Results of macroscopic evaluations including wound lengths, wound areas and the percentage of wound closure are presented in table 1. As also seen in figure 1, in contrast with the control wounds, tragacanth-treated wounds healed far more rapidly.

**Table 1.** The wound length (mm), the wound areas (mm<sup>2</sup>), and the percents of wound closure in control and tragacanth-treated groups 3, 7, and 10 days after creating the wounds.

Variable	Day	Control	tragacanth	P-value
Wound length (mm)	3	13.4±0.2	12.8±0.1	>0.05
	7	10.0±0.8	7.4±0.6	<0.001
	10	5.6±1.2	1.4±0.6	<0.01
Wound area (mm <sup>2</sup> )	3	26.0±2.1	21.4±1.5	<0.001
	7	11.4±1.8	5.4±0.9	<0.001
	10	7.2±2.3	0.6±0.3	<0.05
Wound closure (%)	3	32±5	45±4	< 0.001
	7	70±4	87±2	<0.001
	10	83±5	99±1	< 0.05

Statistically significant differences in wound contraction and closure between the two groups were observed upon day 3 of the study ( $P<0.001$ ). Signs of wound infection were noted in neither of the groups. Moreover, there were no evident signs of an inflammatory reaction to tragacanth in treated wounds.

#### Microscopic observations

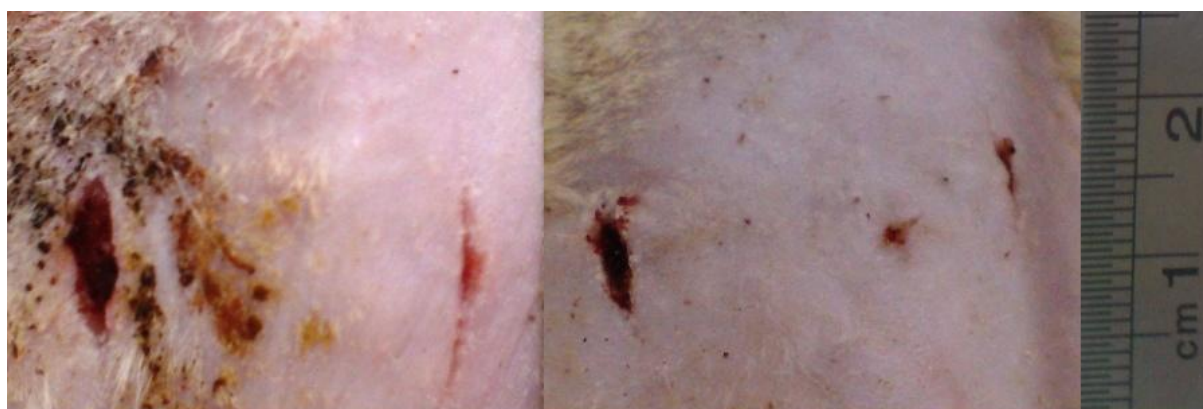On histologic examination of the specimens on day 10, improved epithelialization, extracellular matrix

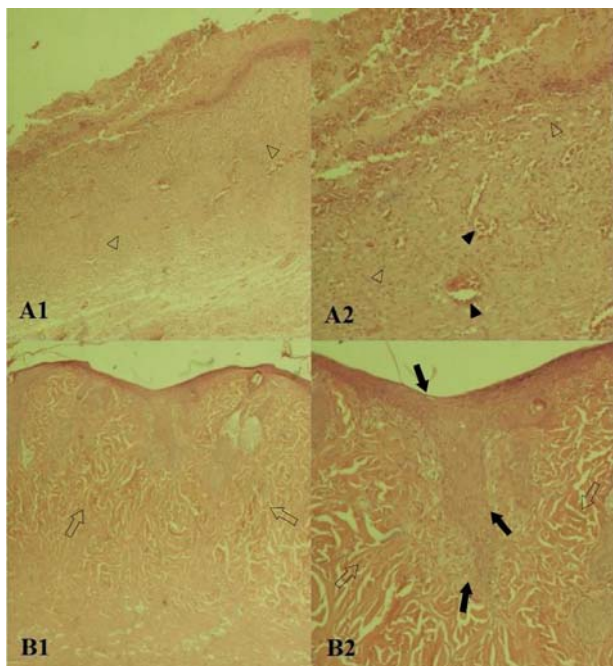
deposition and tissue remodeling were evident in tragacanth-treated wounds in contrast to the extensive inflammation and granulation tissue formation noted in control group samples (Figure 2). No significant infiltration of inflammatory cells to the wound areas was observed in the tragacanth-treated wounds.

The differences in epithelialized tissue area and wound healing index between the two groups were statistically significant with p values less than 0.01 and 0.05 respectively (Table 2).

**Table 2.** The area of repaired epithelium (μm<sup>2</sup>), granulation tissue (μm<sup>2</sup>), and the wound healing index in control and tragacanth-treated groups 10 days after creating the wounds.

Variable	Control	tragacanth	P-value
Repaired epithelium	27262±3427	61362±10587	<0.01
Granulation tissue	131667±3504	99029±39422	0.551
Wound healing index	0.255±0.063	0.624±0.097	<0.05

**Figure 1.** Acceleration of wound closure and healing using tragacanth (right-side wounds) compared to control samples (left-side wounds) in two animals on day 10 after the initial wounding.



**Figure 2.** Photomicrograph of control (A1, 4X; A2, 10X) and tragacanth-treated wounds (B1, 4X; B2, 10X) on day 10. Note the near complete tissue epithelialization (black arrows) and mature scar formation (transparent arrows) in tragacanth-treated wounds compared to the vast tissue granulation (transparent arrowheads) and vessel dilation (black arrowheads) in the control group.

## Discussion

The plant *Astragalus* is employed in folk medicine as a mild laxative. According to traditional beliefs of some peoples in the Middle East and North Africa, it is implied that the leaves contain useful elements in preparation of wound healing lotions. Tragacanth, the dried viscid exudation from the trunk and branches of *Astragalus*, is the source of a pharmaceutical suspending agent, so-called gum tragacanth (9). Tragacanth gum is a highly branched, heterogeneous hydrophilic carbohydrate polymer containing galacturonic acid, galactose, arabinose, xylose, etc. It is a complex slightly acidic polysaccharide bounded with small proportions of protein and trace amounts of starch and cellulosic material present. It also contains a few mineral elements including calcium, magnesium, and potassium (10,11).

Gum tragacanth is a widely used natural emulsifier and thickener employed in food, drug and allied health industries (12-14). It has been shown to decrease plasma LDL and cholesterol in hyperlipidemic patients (15). Consumption of tragacanth is considered to be safe as no toxic effects have been reported, even with large dietary intakes of it in human experiments (16). Moreover, no

evidence of carcinogenicity has been found in animal studies involving tragacanth gum (17,18). Strobel *et al.* investigated the immunogenicity of various types of polysaccharide gums including tragacanth and concluded that proper processing of these substances can significantly reduce the immune response, although a complete systemic immune reaction could not be utterly averted (19). Based on a quality control assessment performed by Moghbel *et al.*, the tragacanth gum available in the traditional Iranian market, which was also used in our study, meets the regulatory requirements of USP23 with acceptable very low amounts of arsenic, lead and heavy metals (20).

In the present study, about 90% wound closure in the tragacanth-treated group occurred within 7 days, and all of the tragacanth-treated wounds were completely or almost completely closed by the 10<sup>th</sup> day of the study. Moreover, the wound healing index, incorporating two factors of granulation tissue formation and epithelial regeneration, was also notably higher in this group (Tables 1 and 2). It could be therefore inferred that tragacanth components accelerate the transition from the inflammation and tissue granulation phases of the wound healing process and enhance mature scar formation and extracellular matrix remodeling which boosts the eventual wound contracture and closure. The findings of our study are consistent with similar wound healing experiments employing various materials including tragacanth (20) and chitosan (3,4,21,22). Moghbel *et al.* studied the effect of topical tragacanth application on excisional wounds in rabbits and concluded that this treatment could significantly shorten the period of wound healing and closure compared to eucerin (control) and phenytoin-treated groups; however, they did not establish any implicating mechanisms (20). Based on a series of studies by Ishihara *et al.* on chitosan, another arabinogalactan containing polysaccharide biopolymer, about 90% wound closure was achieved within 8 days in chitosan hydrogel-treated wounds, whereas similar amount of wound closure was seen only after 10 days in control specimens (3,4).

Several mechanisms encompassing all major phases of the wound healing process (including acute inflammation, granulation tissue formation, and tissue remodeling) have been proposed for the wound healing effects of chitosan and other arabinogalactan-based substances in different studies, which may be also involved in the effect observed in the present experiment. Chitosan has been shown to increase infiltration of inflammatory cells including

polymorphonuclears (PMNs) (22,23). It also exerts chemotaxis of PMNs and macrophages via complement C5a activation (24). Another study has shown that it mediates stimulation of macrophage function (25). Chitosan also potentiates basic fibroblast growth factor (FGF-2) activity by protecting it from inactivation by the interaction between FGF-2 and chitosan polysaccharide constituents (26). Ishihara *et al.* proposed that physical forces initiated by adsorption of various protein molecules from the wound surface into the chitosan preparation may cause wound contraction. Chitosan also stimulates migration and proliferation of dermal fibroblasts. The positively charged chitosan molecules adsorb some substances involved in cell proliferation and migration, such as growth factors and cytokines, from blood plasma or wound exudate. The adsorbed substances subsequently could induce angiogenesis, fibrosis, and epithelialization (4). Arabinogalactans possess a potent dose-dependent complement fixation activity and lead to T cell-independent induction of B cell proliferation (27,28). Arabinogalactan polysaccharides also stimulate the proliferation and enhance the viability of skin fibroblasts (29). The mineral constituents of gum tragacanth including calcium, magnesium, and potassium may also play a substantial role in the wound healing process. Sequential events in wound repair require a conducive environment within the wound bed and a balanced pool of metal ions among which these elements are important. It has been demonstrated by Lansdown *et al.* that as wounds heal, local concentrations of calcium and magnesium change according to the phase in the wound healing cascade and associated biochemical events (30). Calcium has an established role in the normal homeostasis of mammalian skin and serves as a modulator in keratinocyte proliferation and maturation. Furthermore, it may be required in epidermal cell migration and regeneration (31). Magnesium might also be contributory to increased motility of fibroblasts and keratinocytes (32).

The results of our study explicitly reveal the efficacy of gum tragacanth as an effective, facile to prepare, and yet safe, biocompatible, cheap and readily available agent for wound dressing. Hence, tragacanth-containing formulations could be considered as efficacious preparations in chronic and slow-healing wounds such as diabetic foot ulcers, bed sores, and ischemic wounds; however, further studies are required to investigate its exact mechanisms of action in the healing process and verify its efficiency in clinical settings.

## Acknowledgments

The authors would like to thank Mohammad Chehri (Artesh U. Med. Sci.) for preparing the microscopic sections, Ali Afzali (Artesh U. Med. Sci.) for his assistance in performing the animal experiments, and Prof. Sabine Werner (Institute of Cell Biology- ETH Zürich) for her invaluable comments on the study. They also appreciate the kind assistance of Roya D. Collins for literally reviewing and editing the manuscript.

## References

1. Winter GD. Formation of the scab and the rate of epithelialization of superficial wounds in the skin of the young domestic pig. *Nature* 1962;193(4812):293-4.
2. Purna SK, Babu M. Collagen based dressings-a review. *Burns* 2000;26(1):54-62.
3. Ishihara M, Nakanishi K, Ono K, et al. Photocrosslinkable chitosan as a dressing for wound occlusion and accelerator in healing process. *Biomaterials* 2002;23(3):833-40.
4. Ishihara M, Ono K, Sato M, et al. Acceleration of wound contraction and healing with a photocrosslinkable chitosan hydrogel. *Wound Repair Regen* 2001;9(6):513-21.
5. Thomas S. Alginate dressings in surgery and wound management: -- Parts 1. *J Wound Care* 2000;9(2):56-60.
6. Peplow PV. Glycosaminoglycan:a candidate to stimulate the repair of chronic wounds. *Thromb Haemost* 2005;94(1):4-16.
7. Gentry HS. Gum tragacanth in Iran. *Econ Bot* 1957;11(1):40-63.
8. Burdock GA, editor. *Encyclopedia of food and color additives*. 1st ed. Boca Raton: CRC Press; 1996. p. 2818-20.
9. Iwu MM, editor. *Handbook of African medicinal plants*. 1st ed. Boca Raton: CRC Press; 1993. p. 123-4.
10. Weiping W. Tragacanth and karaya. In: Phillips GO, Williams PA, editors. *Handbook of hydrocolloids*. 1st ed. Boca Raton: CRC Press; 2000. p. 231-46.
11. Al-Hazmi MI, Stauffer KR, editors. Gas chromatographic determination of hydrolyzed sugars in commercial gums. *J Food Sci* 1986;51:1091-2.
12. Whistler RL, BeMiller JN, editors. *Industrial gums: polysaccharides and their derivatives*. 1st ed. New York: Academic Press; 1993. p. 289-99.
13. Davidson RL. *Handbook of water soluble gums and resins*. Illustrated ed. New York: McGraw-Hill; 1980. p. 1-11.
14. Elvers B, Hawkins S, Russey W, editors. *Ullmann's encyclopedia of industrial chemistry: Volume A25*. 1st ed. Weinheim: VCH; 1994. p. 1-62.

## Gum tragacanth in skin wound repair in rats

15. Amer S, Kamil R, Siddiqui PQ. The hypolipidaemic effect of gum tragacanth in diet induced hyperlipidaemia in rats. *Pak J Pharm Sci* 1999;12(2):33-9.
16. Eastwood MA, Brydon WG, Anderson DM. The effects of dietary gum tragacanth in man. *Toxicol Lett* 1984;21(1):73-81.
17. Hagiwara A, Tanaka H, Tiwawech D, et al. Oral toxicity study of tragacanth gum in B6C3F1 mice: development of squamous-cell hyperplasia in the forestomach and its reversibility. *J Toxicol Environ Health* 1991;34(2):207-18.
18. Hagiwara A, Boonyaphiphat P, Kawabe M, et al. Lack of carcinogenicity of tragacanth gum in B6C3F1 mice. *Food Chem Toxicol* 1992;30(8):673-9.
19. Strobel S, Ferguson A, Anderson DM. Immunogenicity, immunological cross reactivity and non-specific irritant properties of the exudate gums, arabic, karaya and tragacanth. *Food Addit Contam* 1986;3(1):47-56.
20. Moghbel A, Hemmati AA, Agheli H, et al. The effect of tragacanth mucilage on the healing of full-thickness wound in rabbit. *Arch Iranian Med* 2005;8(4):257-62.
21. Kanani AG, Bahrami SH, Ahmadi Tafti SH, et al. Effect of chitosan-polyvinyl alcohol blend nanofibrous web on the healing of excision and incision full thickness wounds. *IET Nanobiotechnol* 2010;4(4):109-17.
22. Ueno H, Yamada H, Tanaka I, et al. Accelerating effects of chitosan for healing at early phase of experimental open wound in dogs. *Biomaterials* 1999;20(15):1407-14.
23. VandeVord PJ, Matthew HW, DeSilva SP, et al. Evaluation of the biocompatibility of a chitosan scaffold in mice. *J Biomed Mater Res* 2002;59(3):585-90.
24. Usami Y, Minami S, Okamoto Y, et al. Influence of chain length of N-acetyl-D-glucosamine and D-glucosamine residues on direct and complement-mediated chemotactic activities for canine polymorphonuclear cells. *Carbohydrate Polymers* 1997;32(2):115-22.
25. Peluso G, Petillo O, Ranieri M, et al. Chitosan-mediated stimulation of macrophage function. *Biomaterials* 1994;15(15):1215-20.
26. Masuoka K, Ishihara M, Asazuma T, et al. The interaction of chitosan with fibroblast growth factor-2 and its protection from inactivation. *Biomaterials* 2005;26(16):3277-84.
27. Nergard CS, Matsumoto T, Inngjerdigen M, et al. Structural and immunological studies of a pectin and a pectic arabinogalactan from *Vernonia kotschyana* Sch. Bip. Ex Walp. (Asteraceae). *Carbohydr Res* 2005;340(1):115-30.
28. Yamada H, Kiyohara H. Complement-activating polysaccharides from medicinal herbs. In: Wagner H, editors. *Immunomodulatory agents from plants*. 1st ed. Basel: Birkhauser;1999:p. 161-202.
29. Zippel J, Deters A, Hensel A. Arabinogalactans from *Mimosa tenuiflora* (Willd.) Poir bark as active principles for wound-healing properties: specific enhancement of dermal fibroblast activity and minor influence on HaCaT keratinocytes. *J Ethnopharmacol* 2009;124(3):391-6.
30. Lansdown AB, Sampson B, Rowe A. Sequential changes in trace metal, metallothionein and calmodulin concentrations in healing skin wounds. *J Anat (London)* 1999;195(Pt 3):375-86.
31. Lansdown AB. Calcium: a potential central regulator in wound healing in the skin. *Wound Rep Reg* 2002;10(5):271-85.
32. Grzesiak JJ, Pierschbacher MD. Shifts in the concentrations of magnesium and calcium in early porcine and rabbit wound fluids activate the cell migratory response. *J Clin Invest* 1995;95(1):227-33.