

# Operative Management of Hoffa Fracture of the Femoral Condyle

Ramji Lal Sahu<sup>1</sup> and Pratiksha Gupta<sup>2</sup>

<sup>1</sup> Department of Medical Laboratory Sciences, Faculty of Paramedicine, SMS&R, Sharda University U.P. New Delhi, India

<sup>2</sup> Department of Medical Laboratory Sciences, Faculty of Paramedicine, PGIMS &R ESIC, Basaidarapur, New Delhi, India

Received: 25 Dec. 2012; Accepted: 10 Jun. 2013

**Abstract-** Hoffa fracture is a rare injury consisting of unicondylar tangential posterior fracture of the distal femur and only very few cases have been reported in the literature. These fractures are due to high energy trauma and conservative treatment generally yields poor results, but rigid internal fixation allows early functional rehabilitation and decreases the incidence of complications. The purpose of the study was to prospectively analyse the clinico-radiological and functional outcome following open surgical treatment. From July 2005 to July 2010, 22 patients (14 males and 8 females) were recruited from Emergency and outpatient department having closed and open Hoffa fracture of the femoral condyle. All patients were operated under general or spinal anesthesia. Post-operatively, all the patients were followed for 12 months. Fractures were united in a mean time of 10 weeks (range from 6 - 16 weeks) depending on the type of fracture pattern. Fractures were reduced anatomically in all except in one patient. During follow-up, there were no losses of reduction or fixation. Full weight bearing were started in the mean time of 8.8 weeks. Mean duration of hospital stay were 9.8 days. Complications were stiffness and pain in one patient, collateral laxity in one patient and progression of arthritis in one patient. The results were excellent in 90.90% and good in 9.09% patients. Finally, we conclude that the early anatomical reduction and rigid fixation with screws provide best results and minimal complications.

© 2014 Tehran University of Medical Sciences. All rights reserved.

*Acta Medica Iranica*, 2014;52(6):443-447.

**Keywords:** Hoffa fractures; Distal femur; Unicondylar fractures; Tangential fractures

## Introduction

Hoffa fractures are Intraarticular, unicondylar fractures of the lower end of the femur occurring in the coronal plane are uncommon injuries and most often affect the lateral condyle (1). Nonoperative treatment of Hoffa fractures yields poor results (2-5). Rigid internal fixation allows early functional rehabilitation and decreases the incidence of complications (6). The purpose of this study was to prospectively analyze the clinico-radiological and functional outcome following open surgical treatment.

## Materials and Methods

This prospective study was carried out at Orthopaedics department of M. M. Medical College from July 2005 to July 2010. It was approved by institutional medical ethics committee. A total of 22 patients with Hoffa fracture of the Femoral Condyle admitted to our institute were included in the present study. A written informed consent was obtained from all the patients; they were explained about treatment plan, cost of operation, and hospital stay after surgery, and

complications of anesthesia. They were followed up after surgery, were clinically and radiologically assessed for fracture healing and joint movements. The results were graded as excellent when the fractures united within 10 weeks without any complication, good when union occurred within 16 weeks with treatable complications like superficial infection and knee stiffness and poor when union occurred before or after 16 weeks with one or more permanent complications like infection (osteomyelitis), non-union, limb shortening and permanent knee stiffness. Delayed union were recorded when the fracture united between two to four months while nonunion were noted when union had not occurred after four to six months of treatment. The patients were followed for 12 months. Patients with Hoffa fracture with age more than 16 years and presented within a week of the injury and did not have any previous surgical treatment for the fractures were included in the study (Table 1).

Malnourished patients and pathological fractures and fracture nonunion were excluded from the study. Examination of patients was done thoroughly at the time of admission to exclude other injuries. In the majority of the patients open, anatomical reduction and rigid

**Corresponding Author:** R. Lal Sahu

Department of Medical Laboratory Sciences, Faculty of Paramedicine, SMS&R, Sharda University U.P. New Delhi, India  
Tel: +91 11 71120703, Fax: +91 11 23629125, E-mail address: drrlsahu@gmail.com

## Hoffa fracture of the femoral condyle

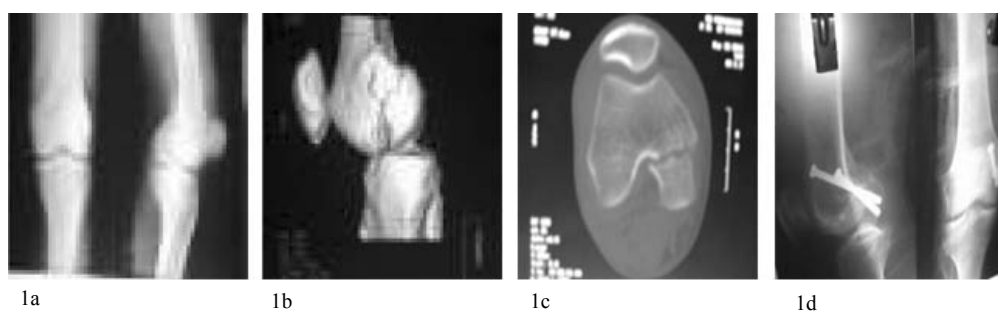
internal fixation of the Hoffa fracture of the Femoral Condyle of the distal femur was performed immediately on the emergency basis after the injury. In patients who were not fit for surgery due to associated injuries to vital organs, were hemodynamically unstable or due to active

infection at injury site, or were pyrexia delayed operation was performed when their over-all condition improved. Routine anteroposterior, lateral and oblique radiograph were taken of all the patients (Figure1a) (Figure2a).

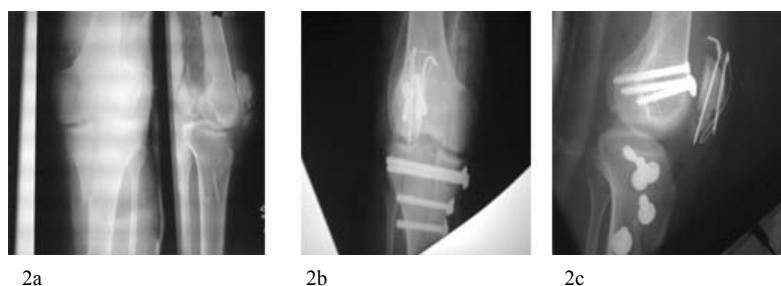
**Table 1. Age and sex variations in study group (n=22)**

Age (years)	Male	R	L	Female	R	L	Total
Less than 20	4	1	3	1	0	1	5
20-40	6	2	4	4	2	2	10
More than 40	4	2	2	3	1	2	7
<b>Total</b>	<b>14</b>	<b>5</b>	<b>9</b>	<b>8</b>	<b>3</b>	<b>5</b>	<b>22</b>

N: Number, R: Right, L: Left



**Figure 1.** (a) Anteroposterior and lateral view showing the Hoffa fracture of medial condyle of femur. (b, and c) Hoffa fracture in C T Scan and (d) postoperative anteroposterior and lateral view showing fracture fixation with partially threaded cannulated cancellous screws



**Figure 2.** (a) Anteroposterior and lateral view showing the Hoffa fracture of lateral condyle of femur. (b and c) postoperative anteroposterior and lateral view showing the fracture fixation with partially threaded cannulated cancellous screws

Valgus stress radiograph made with the patients under general anesthesia, demonstrating distraction at the fracture site through the condyle of the distal femur with the lateral tibial condyle rotated on its femoral articulation. The radiograph is compatible with the diagnosis of Hoffa fracture. Computed tomography scan (C.T.Scan) is essential for the confirmation of the diagnosis (Figure1b, c). Magnetic resonance imaging of the knee joint was also done of the entire patient for the confirmation of the ligamentous injury. The surgical technique consisted of a small medial or lateral incision. The condyle was anatomically reduced and temporarily fixed with K-wires; stable fixation was

Then achieved with screws. In undisplaced fractures, Fixation was applied with one or two partially threaded

cannulated cancellous screw. Screw is driven across fracture line. (Figure1d) (Figure2bc) In displaced fractures, the patient underwent open anatomical reduction and internal fixation operation in emergency conditions. Wound was closed with suction drain in the standard manner, and antiseptic dressing was done. Drain was removed on 2nd post-operative day. Touchdown weight bearing were started on 2nd post-operative day and sutures were removed on 14th post-operative day. At final follow-up, patients were assessed clinically and radiologically for union timing at twelve months following surgery. Patients were assessed for delayed union (more than 4-6 weeks postoperative) and non union (nine months following surgery). Statistical analysis was limited to calculation of percentage of

patients who had unions, malunions, delayed unions, or nonunions and Excellent, Good, and poor outcomes (Tables 2, 3).

**Table 2. Percentage of cases who had unions, malunions, delayed unions, or nonunions (n=22)**

	Total Cases	Percentage of cases
<b>Union</b>	20	90.90%
<b>Delayed union</b>	1	4.54%
<b>Non union</b>	0	0%
<b>Malunion</b>	1	4.54%

n: Number

## Results

There were twenty two patients in this study, fourteen patients were male and eight patients were females. The patients were divided into three groups according to their age for simplicity. Lower age group included those patients whose age was less than twenty years. In this group, there were one female and four males. Middle age group included patients, who were between the ages of 20-40 years. This group included three females and six males. Old age group included patients older than 40 years. This group consisted of eight females and four males. The clinical results of our study were rated on the basis of the criteria of union, nonunion, delayed union or malunion. The patients were followed according to their clinical status. Union was achieved in all patients in a mean time of 10 weeks (range from 6 - 16 weeks) depending on the type of fracture pattern. Rehabilitation -We allowed our patients to start touchdown walking with crutches on the 2nd day of operation as they feel comfortable. All patients, except two, started partial weight bearing on the 6th week and full weight bearing on the 12th week. These two patients had non weight bearing ambulation till the callus became visible on radiographs. All of our patients had full range of motion of their knees and hips. In my study one patient (4.54%) had slight delayed union, in which union occurred in 16-20 weeks. One patient (4.54%) had no significant malunion, in which clinically there was no pain or deformity and no gait changes in walking. One patient (4.54%) had slight knee stiffness that had recovered in two weeks with physiotherapy. One patient (4.54%) had minor medial and lateral collateral ligament laxity and one patient (4.54%) had started developing osteoarthritis changes but on functional assessment, both these patient had no problem (Table 4). Union was achieved in 100 % of patients. The results were excellent in 90.90% and good in 9.09% patients.

**Table 3. Outcome of results of Hoffa fracture of femoral condyle (n=22)**

Out comes	No	Percentage
<b>Excellent</b>	20	90.90%
<b>Good</b>	2	9.09%
<b>Poor</b>	0	0%

n: Number

**Table 4. Complications of Hoffa fracture of femoral condyle (n=22)**

Complications	No
<b>Delayed union</b>	1
<b>Malunion</b>	1
<b>Knee stiffness</b>	1
<b>Collateral ligament laxity</b>	1
<b>Arthritis</b>	1

n: Number

## Discussion

Hoffa fractures of the femoral condyle are rare injuries, and lateral fractures are more common than medial fractures. These fractures occur as an isolated injury to the involved femur, but bilateral Hoffa fractures (6) and unilateral bicondylar Hoffa fractures (7) have been reported. Hoffa fractures associated with supracondylar intercondylar femur fractures have been observed, (8) and the reporting authors highlight the need for preoperative detection of the Hoffa fracture to select the appropriate fixation method for the supracondylar fracture. The mechanism of injury that produces the Hoffa fracture is unknown, but a shearing force on the posterior femoral condyle is postulated (9). Lewis SL, *et al.*, (3) argued that axial load to the lateral femoral condyle with the knee in 90° or more of flexion produces posterior tangential fracture patterns. Four of seven patients in their series were riding motorcycles at the time of injury, placing the knee in 90° of flexion and positioning the lateral femoral condyle to receive an impact. The Hoffa fracture separates the Patellofemoral joint from the tibiofemoral joint; knee movement and particularly weight bearing cause high shear forces along the fracture line, making nonoperative management unpredictable and adequate stabilization challenging. Examination invariably identifies effusion, but varus and valgus instability may be subtle. The neurovascular status should be assessed as in all high-energy knee injuries. Anteroposterior and lateral radiographs may be unimpressive because Hoffa fractures, especially when nondisplaced, are sometimes difficult to detect (10).

On the anteroposterior view, the foreshortened fractured condyle may lead to the appearance of varus or

## Hoffa fracture of the femoral condyle

valgus mal alignment. On a true lateral view, the femoral condyles are not superimposed, and this may be misinterpreted as a poor radiographic view of a normal knee. Oblique radiographs may be helpful, but if the standard radiographic views do not confirm and define the fracture, a CT scan is necessary. In an attempt to predict which coronal plane fractures of the femoral condyle would progress to avascular necrosis. Letenneur *et al.*, (2) (proposed dividing Hoffa fractures into three types, based on the distance of the fracture line from the posterior cortex of the femoral shaft.

A subsequent report from Lewis *et al.*, (3) failed to validate this classification. The AO Classification of long bone fractures and the OTA Fracture Compendium identify the unicondylar coronal fracture as 33.b3.2, but provide little information about prognosis or treatment. (11,12) It is generally accepted that surgical stabilization is necessary to achieve satisfactory function following a Hoffa fracture. There is specific information on the preferred management of this fracture in several popular orthopaedic fracture management texts (13-15). We found 18 articles concerning the management of Hoffa fractures; 5 of these reports simply included Hoffa fractures as a part of a series of unicondylar distal femur fractures.

The report of Lewis *et al.*, on seven coronal fractures of the lateral femoral condyle represents the largest single group of patients studied, but only five fractures were treated operatively. They used either a medial parapatellar arthrotomy or a direct lateral approach between the iliotibial band and the biceps tendon to expose the fracture and two nonparallel screws to fix it. Postoperatively, patients were placed in cylinder casts for 2 to 6 weeks depending on the stability achieved intraoperatively. All five fractures treated surgically healed, and at final follow-up (average 13 months), knee range of motion averaged 110° (range 95° to 130°). Two reports of arthroscopically assisted reduction and internal fixation of femoral condyle fractures have appeared (16).

Wallenbock and Ledinski (9) reported a series of 24 intra articular knee fractures that they treated with arthroscopically assisted reduction and internal fixation, which included two Hoffa fractures. Although noting that the technique of arthroscopically assisted reduction is demanding, they reported good early results. They did not describe specifically the technique or outcome of the patients with coronal fractures. McCarthy and Parker described a patient with a sagittal plane lateral femoral condyle fracture. But their fixation did not achieve rigid compression, (17).

They reported reduced soft tissue dissection, blood loss, and operative time and faster recovery time after arthroscopic management as advantages over formal open reduction. It was difficult to conclude from these two reports that arthroscopically assisted reduction and internal fixation had any clear advantage over the open technique. Ostermann *et al.*, (18) reported that the fracture compression and rigid internal fixation to allow immediate postoperative knee motion in their report on the long-term (average 68 months) results of 29 unicondylar femur fractures, of which there were six Hoffa fractures. They did not report their surgical approach or the outcomes of the patients with Hoffa fractures, but they noted that 23 of 27 patients had an excellent result. Manfredini *et al.*, (5) operated 19 patients with unicondylar femur fractures, six of which were Hoffa fractures, using a variety of open reduction and internal fixation techniques. Four patients with unicondylar femur fractures were treated with casts. 16 operated patients were available for follow-up at a mean of 60 months; 11 had good or excellent results, and 5 had fair or poor results. The four patients were treated none operatively had an unfavorable outcome, with three fair and one poor result. Liebergall *et al.*, (19) mentioned a lateral approach to the knee, using an osteotomy of Gerdy's tubercle, in the treatment of a lateral coronal condylar fracture, but did not offer any outcome data on this single case. The authors described that the osteotomy permits improved visualization for open reduction and internal fixation. A cadaver study compared the stiffness and load to failure of 3.5-mm cortical lag screws, 4.5-mm cortical lag screws, and 6.5-mm cancellous screws used to fix experimentally created Hoffa fractures (20).

There were no difference in stiffness between any of the groups, but the load to failure were significantly higher for 6.5-mm screws compared with 3.5-mm screws. The authors questioned whether that results were clinically significant and noted that smaller screws, such as 3.5-mm cortical screws, may be much easier to fit around a rigid implant if such fixation was necessary, as in the case of a supracondylar femur fracture with an associated Hoffa fracture. Orthopedic textbooks offer a paucity of information regarding the preferred surgical management of Hoffa fractures. One text book does not even mention this fracture pattern.

Muller and Allgower's Manual of Internal Fixation (14) includes a diagram of a Hoffa fracture fixed with two anteroposterior screws, but does not offer a text description. Schatzker and Tile (15) reported the Hoffa fracture pattern and noted that nonoperative treatment

of Hoffa fractures leads to poor function but otherwise did not offer a management approach. In my study, 22 operatively treated isolated Hoffa fractures were unique in that, in contrast to the reports of Lewis *et al.*, (3) and Manfredini *et al.*, (4), we described a standardized surgical approach to the fracture and achieved rigid fixation with optimally positioned lag screws placed perpendicularly to the fracture plane. We believe that an ipsilateral parapatellar approach provides the visualization of the fracture and articular surface necessary for achieving a perfect anatomic reduction and the exposure to compress and rigidly fix the fracture with multiple lag screws. The excellent fracture stability provides immediate range of motion of the joint, minimizing the risk of postoperative joint ankylosis. As majority of fractures are managed with limited open and percutaneous techniques, the Hoffa fracture pattern stands out as one that still is managed best by a "low-tech" formal open reduction and classic lag screw fixation. In my hands, this method has led to uniformly good results without complications. Gavaskar AS *et al.*, (21) had operated of 18 cases of Hoffa fractures by open anatomical reduction and rigid fixation followed by early mobilization and achieved satisfactory functional results when coupled with aggressive rehabilitation. Iwai *et al.*, (22) described that intra-articular corrective osteotomy for malunited Hoffa fracture offers a good outcome and should be considered as salvage treatment. Viskontas *et al.*, (23) suggested an extensible medial subvastus approach can be used to obtain adequate visualization, accurate reduction, and fixation. In our study, we treated all the cases on emergency bases and all the fractures were reduced anatomically and fixed properly as soon as possible. The results were excellent in 90.90% and good in 9.09% of patients.

Hoffa fractures of the femoral condyle are unusual high velocity injuries. These injuries may be missed on routine radiography in the undisplaced fracture. Open anatomical reduction, fixed internal fixation and early mobilization are essential for good long-term results.

## References

- Hoffa A, editor. Lehrbuch der Frakturen und Luxationen für Ärzte. 4th ed. Stuttgart: Verlag von Ferdinand Enke; 1904: p. 451.
- Letenneur J, Labour PE, Rogez IM, et al. Fractures de Hoffa: a propos de 20 observations. *Ann Chir* 1978;32(3-4):213-9.
- Lewis SL, Pozo JL, Muirhead-Allwood WFG. Coronal fractures of the lateral femoral condyle. *J Bone Joint Surg Br* 1989;71(B):118-20.
- Manfredini M, Gildone A, Ferrante R, et al. Unicondylar femoral fractures: therapeutic strategy and long-term results. *Acta Orthop Belg* 2001;67(2):132-8.
- McDonough PW, Bernstein RM. Nonunion of a Hoffa fracture in a child. *J Orthop Trauma* 2000;14(7):519-21.
- Heuschen UA, Gohring U, Meeder PJ. Die beidseitige Hoffa-Fraktureine Rarität. *Aktuelle Traumatol* 1994;24(3):83-6.
- Zeebregts CJ, Zimmerman KW, ten Duis HJ. Operative treatment of a unilateral bicondylar fracture of the femur. *Acta Chir Belg* 2000;100:1104-6.
- Baker BJ, Escobedo EM, Nork SE, et al. Hoffa fracture: a common association with high-energy supracondylar fractures of the distal femur. *AJR Am J Roentgenol* 2002;178(4):994.
- Wallenbock E, Ledinski C. Indications and limits of arthroscopic management of intraarticular fractures of the Knee joint. *Aktuelle Traumatol* 1993;23(2):97-101.
- Allmann KH, Althoefer C, Wildanger G, et al. Hoffa fracture—a radiologic diagnostic approach. *J Belg Radiol* 1996;79(5):201-2.
- Muller ME, Nazarian S, Koch P, et al, editors. *The Comprehensive Classification of Fractures of Long Bones*. 1st ed. Berlin: Springer-Verlag; 1994: p. 144-5.
- Orthopaedic Trauma Association Committee for Coding and Classification. *Fracture and Dislocation Compendium: distal femur fractures*. *J Orthop Trauma* 1996;10(Suppl 1):45.
- Browner BD, Jupiter JB, Levine AM, et al. *Skeletal Trauma*. 2nd ed. Philadelphia, PA: WB Saunders; 1998: p. 1639-40.
- Muller ME, Allgower M, Schneider R, et al. *Manual of Internal Fixation*. 3rd ed. New York, NY: Springer-Verlag; 1995: p. 549.
- Schatzker J, Tile M. *The Rationale of Operative Fracture Care*. 2nd ed. Berlin: Springer-Verlag; 1996: p. 390-1.
- McCarthy JJ, Parker RD. Arthroscopic reduction and internal fixation of a displaced intraarticular lateral femoral condyle fracture of the knee. *Arthroscopy* 1996;12(2):224-7.
- Stern RE. Comment. *Arthroscopy* 1996;12(6):760-1.
- Ostermann PA, Hahn MP, Ekkernkamp A, et al. Monocondylare Frakturen des Femur. *Oururg* 1997;68(1):72-6.
- Liebergall M, Wilber JH, Mosheiff R, et al. Gerdy's tubercle osteotomy for the treatment of coronal fractures of the lateral femoral condyle. *J Orthop Trauma* 2000;14(3):214-5.
- Becker PL, Staford PR, Goulet R, et al. Comparative analysis for the fixation of coronal distal intraarticular femur fractures. *Proceedings of the 67th annual meeting of the American Academy of Orthopaedic Surgeons*. Orlando: FL. 15-19. Feb 2000.
- Gavaskar AS, Tummala NC, Krishnamurthy M. Operative management of Hoffa fractures—a prospective review of 18 patients. *Injury* 2011;42(12):1495-8.
- Iwai, Hamada M, Miyama T, et al. Intra-articular corrective osteotomy for malunited Hoffa fracture: A case report. *Sports Med Arthrosc Rehabil Ther Technol* 2012;4(1):28.
- Viskontas DG, Nork SE, Barei DP, et al. Technique of Reduction and Fixation of Unicondylar Medial Hoffa Fracture. *Am J Orthop* 2010;39(9):424-8.