

## Gluteal Hydatid Cyst: Report of a Case

Sezgin Zeren<sup>1</sup>, Ugur Kesici<sup>2</sup>, and Sevgi Kesici<sup>3</sup>

<sup>1</sup> Department of General Surgery, School of Medicine, University of Dumlupınar, Kutahya, Turkey

<sup>2</sup> Department of General Surgery, School of Medicine, University of Giresun, Giresun, Turkey

<sup>3</sup> Department of Anesthesiology and Reanimation, School of Medicine, University of Giresun, Giresun, Turkey

Received: 26 Oct. 2013; Accepted: 27 May 2014

**Abstract-** Hydatid cyst locates in the liver (70%), lungs (25%) and rarely in other body tissues. Cases with gluteal muscle localized hydatid cyst are rarely seen in literature. In this case report, a woman with hydatid cyst that was located in gluteal muscle was discussed. After the patient had been diagnosed, complete surgical excision was performed with the patient. Albendazole treatment was applied in preoperative and postoperative period to decrease local recurrence risk.

© 2015 Tehran University of Medical Sciences. All rights reserved.

*Acta Med Iran* 2015;53(6):389-391.

**Keywords:** Gluteal muscle; Hydatid cyst; Rare localization

### Introduction

Hydatid cyst, whose hosts are primarily dogs, sheep and cattle, and sometimes human beings as the secondary host, is a parasitosis formed by larvae of *Echinococcus granulosus* (1). Hydatid cyst disease is endemically seen in Africa, the Mediterranean coast of Europe, the Middle East, South America, Australia and Russia (2, 3). It frequently locates in the liver (70%), lungs (25%) and rarely in other body tissues (3-5). Liver hydatid cyst is a disease frequently seen in females (3). Hydatid cyst encountered in soft tissues constitutes nearly 2.4 to 5.3% of all hydatid cyst cases (1).

In this case report, 34 years old female patient with intramuscular localized hydatid cyst was discussed.

### Case Report

In this case report, 34-year-old female patient who applied to the polyclinic with complaints of pain and swelling in left hip approximately for 2 years, was discussed. In the history of the patient there was a lung hydatid cyst surgery performed 3 years ago and 2 normal vaginal delivery. Approximately 3-4 cm in size, painful palpable mass was determined in the physical examination of the patient in lateral of left gluteal region. 3×4 and 2×2 cm cystic lesion were reported in superficial tissue ultrasonography (USG). In the pelvic magnetic resonance imaging (MRI), it was detected that the specified lesions were intramuscularly located. IHA

test of the patient was positive. An operation decision was taken because the patient was thought to have a hydatid cyst. No feature was detected in the full abdomen USG taken to eliminate the presence of another cyst. Preoperative routine blood tests and PAAC of the patient was normal. Two doses of albendazole (Andazol 400 mg. 60 Film Tablet. Biofarma. Istanbul. Turkey) per day (totally 15 mg/kg/day) were started for pre-operative 7 days. The cysts were reached under spinal anesthesia by means of an incision made on the mass in the left gluteal region. Ten minutes after hypertonic serum sale was injected into the cysts, both cystic lesions were totally removed. The peroperative image of the mass is shown in Figure 1.

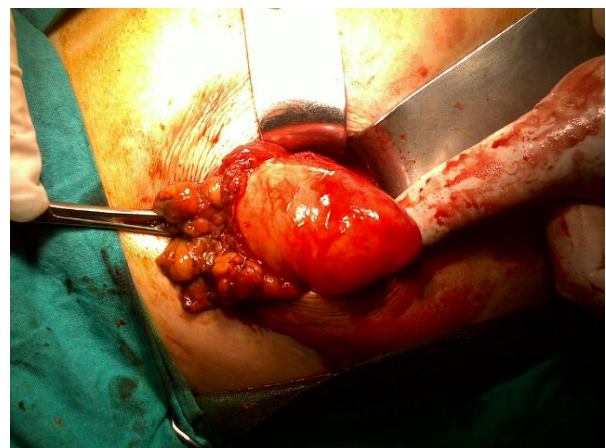


Figure 1. Peroperative image of the mass

### Corresponding Author: S. Kesici

Department of Anesthesiology and Reanimation, School of Medicine, University of Giresun, Giresun, Turkey  
Tel: +90 454 3101655, Fax: +90 454 3101696, E-mail address: md.kesici@mynet.com

## Gluteal Cyst Hydatid

The patient with no complication developed was discharged on the postoperative 2nd day. In the histopathological examination of the removed specimens, two hydatid cyst compatible materials with a membranous structure that was infiltrated with exudate were determined. In the postoperative period, totally 15 mg/kg/day albendazole was administered to the patient in two equal doses for 2 months.

## Discussion

Hydatid cyst is a disease with endemic features in some countries and regions of the world (2,3). Echinococcosis is a parasitic disease that develops cysts in both humans and animals caused by *Echinococcus* type cestodes and it continues to be a significant health problem in our country (3,4). The disease is more frequently seen in areas where animal breeding conditions are poor and where there are stray dogs. Humans are infected with the parasite egg by contact with dogs or from contaminated food. The larvae of this parasite egg appear in the small intestine and penetrate the intestinal wall and thus enter the circulatory system (2,3). Although the liver and lung are the most common organs involved by the disease, there are studies demonstrating that rarely it migrates in other tissues (3, 4). Localization in soft tissues is extremely rare accounting for only 2.3% in the largest published series (5).

Anamnesis, immunological tests, USG and CT (Computer Tomography) are used in the diagnosis of hydatid cyst (3, 6). History of animal contact (especially dogs) and living in a sheep-raising or cattle-raising rural area is generally present (7). However, such a history was not determined for this patient. The serological tests including Casoni intradermal skin test, Weinberg complement fixation (CF) test, indirect hemagglutination (IHA) test, ELISA, and western blot (WB) are the frequently used laboratory tests for diagnosis of hydatid disease, with the reported sensitivity of 96.7%, 87.1% and 100%, for IHA, ELISA, and WB, respectively (7, 8). IHA test was used as serological test for this patient, and it was determined to be positive. Gharbi classification (3,9) and the classification produced by WHO (World Health Organization) in 2003 are used in USG (3,10). CT gives more detailed information about the localization and size of the cyst, and its sensitivity is 100% (3,11). Even though ultrasonographic evaluation is known to be of value in the diagnosis of hydatid cyst in muscles, it is

emphasized that the findings of magnetic resonance imaging (MRI) have recently become more valuable (1,12). For this patient, pelvic MRI was used to determine the depth of the lesion due to the localization of mass in the gluteal muscle.

Medical, surgical treatment and PAIR (Puncture Aspiration Introduction of proscocidal agent Respiration) are administered in accordance with the treatment stage and localization (3,6). The best treatment option in subcutaneous hydatid cysts is complete surgical excision (13). Surgical treatment was performed for this patient. In the patients who will undergo a surgical treatment, it is stated that preoperative anthelmintic therapy and peroperative scolocidal agent use decreases local recurrence rate (3). Therefore, preoperative anthelmintic therapy and the peroperative scolocidal agent was used because peroperative hydatid cyst was considered for this patient. The muscular localization of the hydatid cyst incidence is approximately 0.5 to 5.4% (14). Although cases of gluteal muscle localized cyst hydatid are reported in the literature (1,7), the incidence of gluteal muscle localized cyst hydatid is not known clearly.

Although cyst hydatid cases are frequently localized in liver and lungs, it may rarely be seen in the other regions of the body. Therefore, in the differential diagnosis of cystic lesions that grows in time in any region of the body, especially in endemic regions, cyst hydatid must be certainly considered.

## References

1. Eryilmaz MA, Eroglu C, Karabagli P, et al. Gluteal hydatid cyst: Case report. *Turkiye Klinikleri J Med Sci* 2010;30(4):1380-3.
2. Acar A, Rodop O, Yenilmez E, et al. Case report: primary localization of a hydatid cyst in the adductor brevis muscle. *Turkiye Parazitol Derg* 2009;33(2):174-6.
3. Kesici U, Kesici S, Turkmen A, et al. Primary Cyst Hydatid in the Neck; Report of One Case. *Turkiye Parazitol Derg* 2011;35(4):217-9.
4. Ozekinci S, Bakir S, Mizrak B. Evaluation of Cystic Echinococcosis Cases Given a Histopathologic Diagnosis from 2002 to 2007 in Diyarbakir. *Turkiye Parazitol Derg* 2009;33(3):232-5.
5. Chakrabarti I, Goswami BK. Primary hydatid cyst of the neck diagnosed by aspiration cytology. *Trop Parasitol* 2012;2(2):127-8.
6. Sayek I, Onat D. Diagnosis and treatment of uncomplicated hydatid cyst of the liver. *World J Surg* 2001;25(1):21-7.

7. Guraya SY, Alzobydi AH, Guraya SS. Primary extrahepatic hydatid cyst of the soft tissue: a case report. *J Med Case Rep* 2012;6:404.
8. Akisu C, Bayram Delibas S, Yuncu G, et al. Evaluation of IHA, ELISA and western blot tests in diagnosis of pulmonary cystic hidatidosis. *Tuberk Toraks* 2005;53(2):156-60.
9. Gharbi HA, Hassine W, Brauner MW, et al. Ultrasound examination of hydatid liver. *Radiology* 1981;139(2):459-63.
10. WHO Informal Working Group. International classification of ultrasound images in cystic echinococcosis for application in clinical and field epidemiological settings. *Acta Trop* 2003;85(2):253-61.
11. Pedrosa I, Saíz A, Arrazola J, et al. Hydatid disease: radiologic and pathologic features and complications. *Radiographics* 2000;20(3):795-817.
12. Martin J, Marco V, Zidan A, et al. Hydatid disease of the soft tissues of the lower limb: findings in three cases. *Skeletal Radiol* 1993;22(7):511-4.
13. Kayaalp C, Dirican A, Aydin C. Primary subcutaneous hydatid cysts: a review of 22 cases. *Int J Surg* 2011;9(2):117-21.
14. Baraket O, Zribi R, Berriche A, et al. A primary hydatid cyst of the gluteal muscle. *Tunis Med* 2011;89(8-9):730-1.