

A Proximal Femur Aneurysmal Bone Cyst Resulting in Amputation: a Rare Case Report

Khodamorad Jamshidi, Farid Najd Mazhar, and Reza Shafipour

Department of Orthopedic Surgery, Shafa Yahyaian Rehabilitation Center,
Iran University of Medical Sciences, Tehran, Iran

Received: 6 Sep. 2013; Accepted: 10 Jun. 2014

Abstract- Aneurysmal bone cyst (ABC) is blood filled expansile cystic lesion that most commonly occurs in patients during the second decade of their lives. Traditionally it has been described as a benign lesion but can be locally aggressive and result in the destruction of the involved bone. Treatment methods include surgical excision and curettage with or without bone grafting. We report a proximal femur aneurysmal bone cyst, which resulted in the amputation of the lower extremity, even though all available classic methods of treatment were applied for it.

© 2015 Tehran University of Medical Sciences. All rights reserved.

Acta Medica Iranica, 2015;53(2):139-142.

Keywords: Aneurysmal bone cyst; Amputation; Femur; Case report

Introduction

Aneurysmal bone cyst (ABC) is blood filled expansile cystic lesion that most commonly occurs in patients during the second decade of their lives. Traditionally it has been described as a benign lesion but can be locally aggressive and result in the destruction of the involved bone (1). Any bone may be affected, but the most common locations include the proximal humerus, distal femur, proximal tibia, and spine (2). Treatment methods include surgical excision and curettage with or without bone grafting. Unfortunately, a recurrence rate of 30–40% has been reported with these methods (2). We report a proximal femur aneurysmal bone cyst, which resulted in the amputation of the lower extremity. Its clinicopathologic features, therapeutic approach, complications, and follow-up are discussed in this article.

Case Report

An 18-year-old woman presented with a six-month history of the proximal thigh swelling and a painless limp. Physical examination was normal except for a mild swelling around the proximal part of the left thigh. A plain radiograph revealed an expansile, eccentric lytic lesion in the proximal femur with extension to soft tissue (Figure 1). A complete tumor work up was done. Laboratory tests were normal. The chest radiograph was

normal as well. Bone scan showed increased uptake in proximal of left femur. MRI revealed multi-lobulated expansile cystic lesion with fluid and fluid level was suggesting of an ABC of the proximal femur (Figure 2).

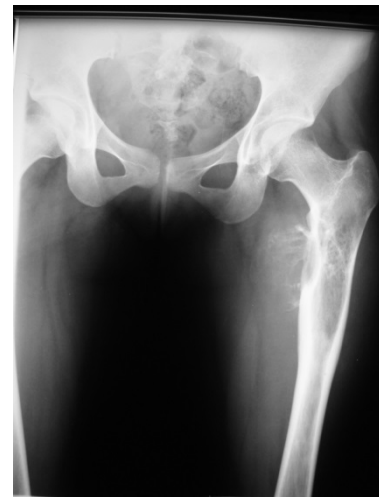

Figure 1. Antero posterior radiograph showed expansile, eccentric lytic lesion in the proximal femur with extension to soft tissue

Incisional biopsy was done through lateral approach. Intraoperatively a cystic hemorrhagic lesion was observed. Pieces of the lesion were sent to pathology, and a diagnosis of aneurysmal bone cyst was made. Two days later the patient was returned to the operating room because of massive hematoma and bloody discharge from

Corresponding Author: F. Najd Mazhar

Department of Orthopaedic Surgery, Shafa Yahyaian Rehabilitation Center, Iran University of Medical Sciences, Tehran, Iran
Tel: +98 21 33542022, Fax: +98 21 33542020, E-mail address: fnajdmazhar@yahoo.com

Femur aneurysmal bone cyst

the sutured biopsy incision. Hematoma evacuation and homeostasis were done. As an approach to ABC management, cyst curettage and fixation with intramedullary nailing was done. Six months later patient returned to the clinic because of increasing pain, recurrent swelling of the proximal of her left thigh and limping. Radiography of the left hip and proximal femur revealed a lytic lesion of the proximal femur and soft tissue swelling (Figure 3). She underwent the curettage and cementing without exchanging the device. Three months after the second procedure, patient had intense pain in her thigh and radiography of left hip showed progression of the lesion (Figure 4). At this time patient, had serosanguineous discharge from the previous incisional scar. To control swelling and suppression of the lytic lesion, intra-arterial embolization was done which failed to control the progression of the diseases. Six months later she received 15 courses of fractionated radiotherapy (total dose 3000 rad), which did not help her.

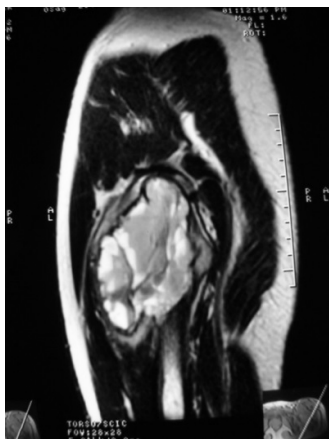

Figure 2. Sagittal T2 weighted MRI of the proximal femur showed multiloculated expansile cystic lesion with fluid and fluid level

The patient was followed up every 3 months and her disease progressed. Radiography showed local recurrence; the cement had been extruded, and the fixation had failed. One year after completion of radiation therapy, the proximal femur had been resorbed completely. A massive hematoma remained in place (Figure 5). The patient was suffering from a large mass, chronic wound bleeding and pain (Figure 6). A hemipelvectomy was the only remaining option and was carried out after consultation (Figure 7). After the hemipelvectomy, histological examination showed a hemorrhagic tissue with cavernous spaces separated by a cellular stroma again with a definite diagnosis of ABC (Figure 8). Two years after the hemipelvectomy there has been neither local recurrence nor distant metastasis. A written consent was obtained from the patient to report this case).

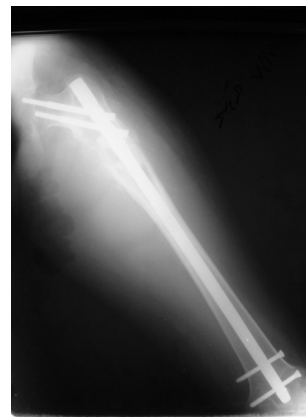

Figure 3. Anteroposterior radiograph of the entire femur 6 months after curettage and cephalo- medullary nail fixation showed a lytic lesion and soft tissue swelling in the sub trochanteric area

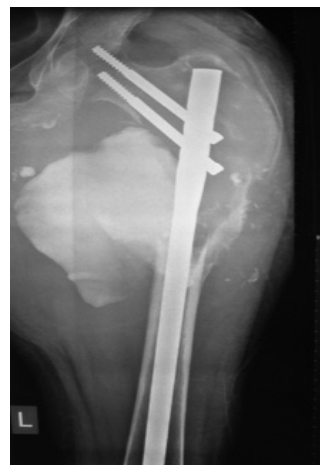

Figure 4. Antero posterior radiograph of the proximal femur revealed progression of the lytic lesion in bone

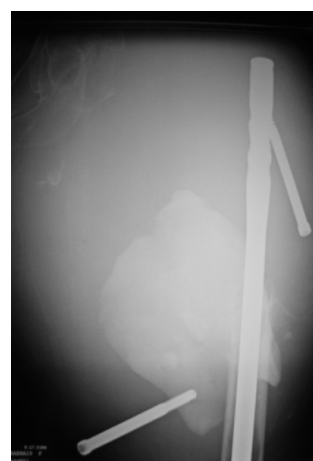


Figure 5. Antero posterior radiograph of the proximal femur one year after completion of radiation therapy revealed resorbed proximal femur and failed device

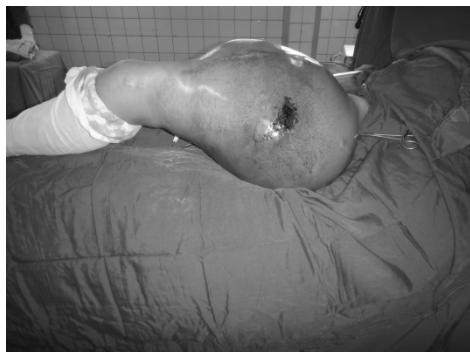

Figure 6. The appearance of the limb just before amputation

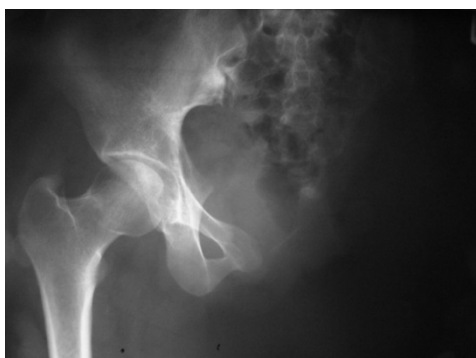

Figure 7. Antero posterior of the pelvis after hemipelvectomy

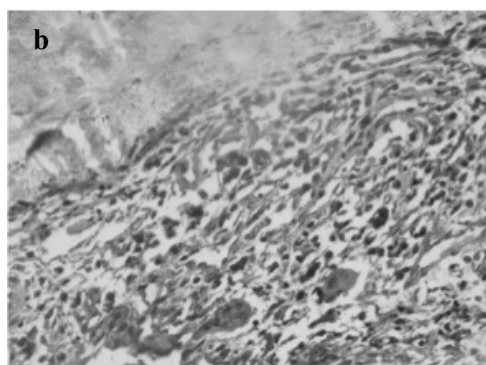


Figure 8. Histological features are showing a hemorrhagic tissue with cavernous spaces separated by a cellular stroma. (a) The lining of the cavitory spaces consists of compressed fibroblasts, histiocytes, chronic inflammatory cell and multinucleated giant cells (H&E)

Discussion

Jaffe and Lichtenstein first described ABC in 1942 and subsequently its pathogenesis, treatment, recurrence, and outcomes were reported and discussed by authors in the literature (6). Although this lesion is benign, it is locally destructive, expansile and impinges on the surrounding tissue. The etiology was originally thought to be reactive and reparative arising from vascular disturbance. Panoutsakoupoulos *et al.*, in 1999, described a translocation of TRE17 in ABC cases and suggested a neoplastic origin for ABC (4). This translocation causes TRE17 (an ubiquitin-specific protease) to be highly expressed, whereas TRE17 is absent or expressed at very low levels in most adult human tissues except for testes (5).

Accepted treatment for this lesion is curettage and bone grafting or filling the cavity with bone cement, but recurrence after this kind of treatment is not uncommon (2,6,7). Less common treatment options are the embolization, simple curettage, curettage augmented with phenol and en bloc excision and structural graft reconstruction (6).

Mankin *et al.* in their analysis of 150 cases of ABC treatment and their outcomes reported that no one of their patients died due to the tumor and they did not have any amputations in the treatment course of therapy. The main complication of the treatment process was local recurrence in 20% of the patients. (6)

Biesecker *et al.*, reported the clinicopathological aspects and treatment options for the lesion in their study of 66 cases (1). They treated the tumors by curettage, curettage and bone grafting or cryosurgery. In cases with recurrence, they used radiation in several cases. They stated that the cryosurgery was their treatment of choice because of low recurrence rate (1). Cryosurgery was done in 13 cases of their series but in one case, cryosurgery was followed by amputation due to extensive osseous destruction by the ABC even though they did not mention the location of the tumor that resulted in the amputation (1).

There are numerous reports in the literature to indicate that treatment of ABC can result in good or excellent functional outcomes despite frequent recurrence, especially when cryosurgery was being used as an integrated part of treatment (1,6,8). In review of forty patients with ABC, Gibbs *et al.*, conducted a retrospective study to evaluate the factors which influenced local recurrence of ABC after treatment and concluded that high-speed burring during curettage was important in prevention of recurrence (9).

Femur aneurysmal bone cyst

Varshney et al. reported the results of repetitive sclerotherapy in lieu of intralesional excision and bone grafting and concluded the same results (10).

We believe that the case presented in this article remarks the aggressive nature of ABC, which can end in catastrophic results and outcome. It can be life threatening and result in hemipelvectomy in a young patient even though all accepted treatment modalities were done to take it under control. The clinical course of ABC in this case is unique with regards to rapid progression and recurrence. Review of literature reveals that this kind of complication is very rare. We did not use high-speed burring in the first operation as recommended by Gibbs. Instead we used adjuvant (polymethylmethacrylate) therapy in combination with curettage.

The course of this case indicated once again that, there is not a uniform and effective treatment for ABC, and it can result in amputation.

References

1. Biesecker JL, Marcove RC, Huvos AG, et al. Aneurysmal bone cysts. A clinicopathologic study of 66 cases. *Cancer* 1970;26(3):615-25.
2. Campanacci M, Capanna R, Picci P. Unicameral and aneurysmal bone cysts. *Clin Orthop Relate Res* 1986;(204):25-36.
3. Marcove RC, Sheth DS, Takemoto S, et al. The treatment of aneurysmal bone cyst. *Clin Orthop Relate Res* 1995;(311):157-63.
4. Panoutsakopoulos G, Pandis N, Kyriazoglou I, et al. Recurrent t(16;17)(q22;p13) in aneurysmal bone cysts. *Genes Chromosomes Cancer* 1999;26(3):265-6.
5. Paulding CA, Ruvolo M, Haber DA. The Tre2 (USP6) oncogene is a hominoid-specific gene. *Proc Natl Acad Sci U S A* 2003;100(5):2507-11.
6. Mankin HJ, Horicek FJ, Ortiz-Cruz E, et al. Aneurysmal Bone Cyst: A Review of 150 Patients. *J Clin Oncol* 2005;23(27):6756-62.
7. Jafari D, Jamshidi K, Najdmazhar F, et al. Expansile aneurysmal bone cyst in the tubular bones of the hand treated with en bloc excision and autograft reconstruction: a report of 12 cases. *J Hand Surg* 2011;36(8):648-55.
8. Van Loon CJM, Veth RPH, Pruszczynski M, et al. Aneurysmal bone cyst long term results and functional evaluation. *Acta Orthopaedica Belgica* 1995;61(3):199-204.
9. Gibbs CP Jr, Hefele MC, Peabody TD, et al. Aneurysmal bone cyst of the extremities. Factors related to local recurrence after curettage with a high-speed burr. *J Bone Joint Surg Am* 1999;81(12):1671-8.
10. Varshney MK, Rastogi S, Khan SA, et al. Is sclerotherapy better than intralesional excision for treating aneurysmal bone cysts? *Clin Orthop Relat Res* 2010;468(6):1649-59.