

Idiopathic Lumbar Epidural Lipomatosis Mimicking Disc Herniation: A Case Report

EFE Duran¹, Kemal Ilik², Turker Acar¹, and Melda Yıldız¹

¹ Department of Radiology, School of Medicine, Mevlana University, Konya, Turkey

² Department of Neurosurgery, School of Medicine, Mevlana University, Konya, Turkey

Received: 23 Apr. 2014; Accepted: 23 Dec. 2014

Abstract- Spinal epidural lipomatosis is a rare condition which is described as the accumulation of fat in the extradural territory and often causes dural impingement. Spinal epidural lipomatosis has been implicated in causing a variety of neurologic impairments ranging from back pain, radiculopathy, claudication, myelopathy or even cauda equina syndrome. We report a 46-year-old female with obesity and a history of chronic back pain and radiculopathy who developed idiopathic Spinal epidural lipomatosis diagnosed by magnetic resonance imaging. The purpose of this report is to present a case of spinal epidural lipomatosis presenting with symptomatic cord compression and also remind this rare condition as a the differential diagnosis of epidural lesions in patients with risk factors.

© 2016 Tehran University of Medical Sciences. All rights reserved.

Acta Med Iran, 2016;54(5):337-338.

Keywords: Epidural lipomatosis; Fat; Magnetic resonance imaging; Radiculopathy

Introduction

Spinal epidural lipomatosis (SEL) is a rare condition which is described as the accumulation of fat in the extradural territory and often causes dural impingement. This is usually secondary to an uncommon complication of chronic steroid therapy, local corticosteroid injections, Cushing's syndrome, obesity, carcinoid tumor, and hypothyroidism (1-4). SEL has been implicated in causing a variety of neurologic impairments ranging from back pain, radiculopathy, claudication, myelopathy or even cauda equina syndrome (5,6).

Case Report

A 46-year-old female with a history of hypertension and hyperlipidemia presented with about three-year history of back pain and radicular proximal leg pain. Over the three months prior to presentation, she had an exacerbation of her pain located in his lower lumbar region described as deep, sharp and associated with radicular radiation to the proximal legs. Physical examination revealed an obese patient [she was 163 cm tall and weighed 85 kg, with a body mass index (BMI) of 32 kg/m²] without any evidence of Cushings'

syndrome or endocrinopathies. Lumbosacral spine radiographs did not show any pathology. Due to a definite neurological deficit, (Magnetic Resonance Imaging) MRI was arranged. The MRI revealed abnormal hypertrophy of adipose tissue located at the anterior aspect of spinal canal extending from L5 to S1. Given the absence of referable symptoms, she was followed on an outpatient basis with weight loss regimen as conservative treatment. The patient's symptoms resolved slowly, by weight loss in the follow-up period (Figures 1-3).

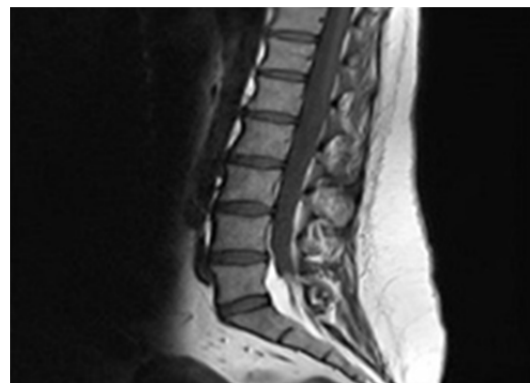


Figure 1. Sagittal T1-weighted MRI (short tau inversion recovery; STIR) shows epidural lipomatosis

Corresponding Author: K. Ilik

Department of Neurosurgery, School of Medicine, Mevlana University, Konya, Turkey
Tel: +90 332 4444243, Fax: +90 332 4444243, E-mail address: mkilik@gmail.com

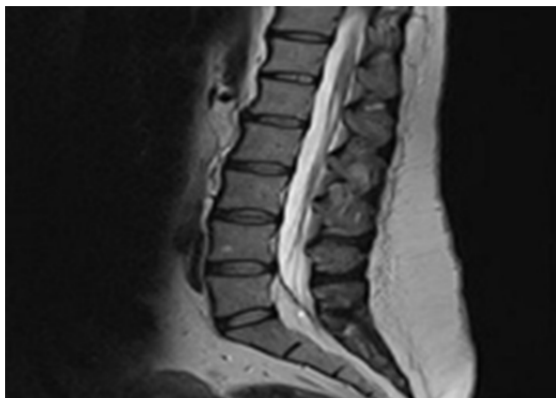


Figure 2. Sagittal T2 weighted MRI shows epidural lipomatosis with compression of the thecal sac in the L5/S1 region

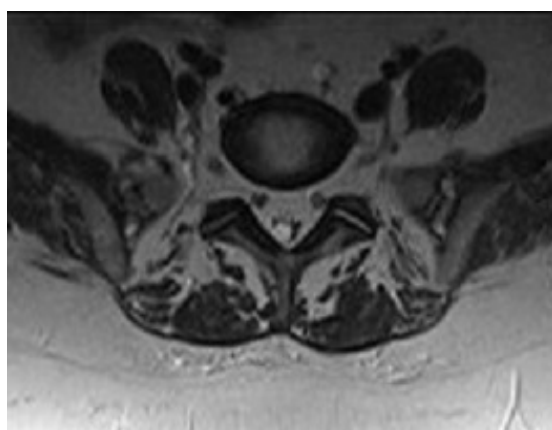


Figure 3. Axial T2-weighted MRI shows compression of the thecal sac and roots because of the lipomatosis.

Discussion

SEL is a rare entity, first described by Lee *et al.*, in 1975 in a patient receiving exogenous glucocorticoids status postrenal transplant (5). Geers *et al.* is observed in approximately 0.8% of patients undergoing lumbar spine MRI in a two-year study (7). Fat shows demonstrative high signal intensity on T1 and T2-weighted MR images. This enables detection of abnormally accumulated extradural fat. MR images usually show a polygonal spiculated Y-shaped, or stellar deformation of the dural sac in association with epidural fat overgrowth (7,8). Classic deformation of the thecal sac into the "Y-sign" wasn't seen in our case, but star formation was detected.

The pathogenesis is unknown, but there is evidence that links glucocorticoids to the development of SEL. Differential diagnosis include epidural abscess or hemorrhage, herniated disc, vertebral body metastases, paraspinal lesions, and epidural metastases (9,10).

Clinical manifestations are related to the compression of the nerve roots and the spinal cord; including back pain, lower extremities weakness, paresthesias, ataxia, and less frequent bowel or urinary incontinence (11).

Weight loss has been reported to be successful in treating obese patients with SEL. Symptoms and neurological findings should determine therapeutic paradigm. If diet therapy is not successful, or if the patient is in acute neurological deterioration decompressive surgery should be considered (12).

References

1. Toshniwal PK, Glick RP. Spinal epidural lipomatosis: report of a case secondary to hypothyroidism and review of literature. *J Neurol* 1987;234(3):172-76.
2. Fassett DR, Schmidt MH. Spinal epidural lipomatosis: a review of its causes and recommendations for treatment. *Neurosurg Focus* 2004;16(4):E11.
3. Sivakumar K, Steinert K, Lidov M, et al. Symptomatic spinal epidural Lipomatosis in a patient with Cushing's disease. *Neurology* 1995;45(12):2281-3.
4. Borre DG, Borre GE, Aude F, et al. Lumbosacral epidural lipomatosis: MRI grading. *Eur Radiol* 2003;13(7):1709-21
5. Lee M, Lekias J, Gubbay SS, et al. Spinal cord compression by extradural fat after renal transplantation. *Med J Aust* 1975;1(7):201-3.
6. Kumar K, Nath RK, Nair CP, et al. Symptomatic epidural lipomatosis secondary to obesity. Case report. *J Neurosurg* 1996;85(2):348-50.
7. Geers C, Lecouvert FE, Behets C, et al. Polygonal Deformation of the Dural Sac in Lumbar Epidural Lipomatosis; Anatomic Explanation by the Presence of Meningovertebral Ligaments. *AJNR Am J Neuroradiol* 2003;24(7):1276-82
8. Butteriss D, Jayakrishnan V. Acute spinal cord compression. *Br J Radiol* 2007;80(956):686-9.
9. Quint D, Boulos R, Sanders W, et al. Epidural lipomatosis. *Radiology* 1988;169(2):485-90.
10. Ishikawa Y, Shimada Y, Miyakoshi N. Decompression of idiopathic lumbar epidural lipomatosis: diagnostic magnetic resonance imaging evaluation and review of the literature. *J Neurosurg Spine* 2006;4(1):24-30.
11. Payer M, Van Schaeybroeck P, Reverdin A, et al. Idiopathic symptomatic epidural lipomatosis of the lumbar spine. *Acta Neurochir (Wien)* 2003;145(4):315-20.
12. Robertson SC, Traynelis VC, Follett KA, et al. Idiopathic spinal epidural lipomatosis. *Neurosurgery* 1997;41(1):68-74.