

Conservative Management of Colonoscopic Perforation: A Case Report

Hossein Parsa¹, Arash Miroliaee², Zafar Doagoo³, and Saeed Sina¹

¹ Department of Surgery, Velayat Hospital, Qazvin University of Medical Sciences, Qazvin, Iran

² Department of Internal Medicine, Velayat Hospital, Qazvin University of Medical Sciences, Qazvin, Iran

³ Department of Internal Medicine, Zakariya-e-Razi Hospital, Qazvin, Iran

Received: 23 Dec. 2015; Received in revised form: 21 Apr. 2016; Accepted: 23 May 2016

Abstract- Colonoscopy is widely used for the diagnosis, treatment and a follow up of colorectal diseases. Perforation of the large bowel during elective colonoscopy is rare but serious life threatening complication. We report a 51-year-old woman who experienced recto sigmoid perforation during diagnostic colonoscopy. During 8 days of total hospitalization, she spent 3 days in ICU with gastrointestinal rest. The patient was hydrated and took intravenous antibiotics. In take-output and temperature were closely monitored. Serial abdominal examinations were performed to rule out peritonitis. After transferring to surgery ward in the day 4, liquid diet started slowly, and she was ambulated. At the day 8, she was discharged with the good clinical condition. Conservative management of the patients with early diagnosis of perforation and no signs and symptoms of peritonitis or sepsis could be the modality of choice.

© 2017 Tehran University of Medical Sciences. All rights reserved.

Acta Med Iran 2017;55(7):477-479.

Keywords: Colonoscopy; Colonoscopic perforation; Conservative management

Introduction

Colonoscopy is widely used for the diagnosis, treatment, and follows up of colorectal diseases (1-3). Perforation of the large bowel during elective colonoscopy is rare but serious life threatening complication (4,5). Increasing age, American Society of Anesthesia Class, female sex, hospital setting, any therapy, and polyps bigger than 10 mm were significantly associated with increased risk of early perforation (6).

Several large retrospective studies have determined perforation incidences of 0.02-0.8% and 0.15-3% for diagnostic and therapeutic colonoscopy, retrospectively (6-11). Perforations associated with diagnostic procedures are usually due to applying pressure to the colonic wall, and they are noticed immediately. However, perforations that occur after therapeutic procedures are often diagnosed late (10).

If a perforation does occur, signs and symptoms that the patient will experience will be related to the size and site of the perforation, adequacy of bowel preparation, amount of peritoneal soilage, underlying colonic pathology, and, finally, the overall clinical condition of the patient (12). Treatment for colonoscopic perforations should be individualized according to the patient's

condition, related devices, and surgical skills of endoscopists or surgeons (13).

Selective patients are likely to improve under conservative management involving hospitalization, intestinal rest, intravenous fluids, and antibiotics to limit peritonitis and allow the perforation to seal. However conservative management requires careful observation with frequent and repeated abdominal exams. Patients successfully treated non-surgical must be clinically stable, and their abdominal symptoms should improve rapidly with no deterioration due to peritoneal signs (14).

Case Report

The case of conservative management of colonic perforation that is presented below is a 51-year-old woman who underwent a colonoscopic resection of Tubulovillous Adenoma Polyp of rectosigmoid with high-grade dysplasia 2 months ago, came for her follow-ups for diagnostic colonoscopy. During the procedure, colonic (rectosigmoid) perforation occurred, and the patient was admitted to Intensive Care Unit for close observation. At the first hours, the apparent generalized abdominal pain was recorded without any signs and symptoms of peritonitis. Bowel sounds were

Corresponding Author: S. Sina

Department of Surgery, Velayat Hospital, Qazvin University of Medical Sciences, Qazvin, Iran
Tel: 98 28 33760620, Fax: +98 28 33790611, E-mail address: dr.saeedsina@yahoo.com

Management of colonoscopic perforation

normoactive, and the vital signs were stable. In the laboratory data mild leucocytosis (WBC:12800, PMN:72%) was detected. Abdominopelvic CT scan (Figure 1) was considered.

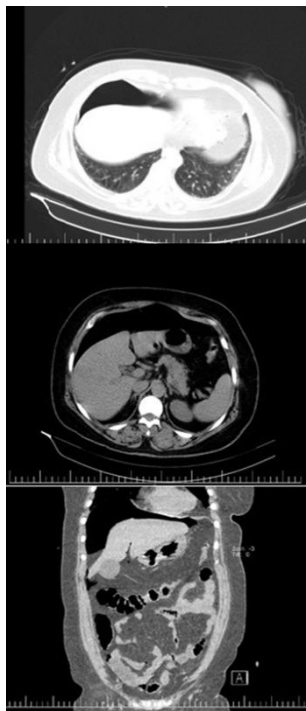


Figure 1. Abdominal CT scan shows sub diaphragmatic air pattern (pneumo peritoneum)

During 8 days of total hospitalization, she spent 3 days in ICU with gastrointestinal rest. She was hydrated, and intravenous Ceftriaxone (1 gr-BD), Clindamycin (600 mg-TDS), and ciprofloxacin (400 mg-BD) were prescribed. Intake-output and temperature were closely monitored. Serial abdominal examinations were performed to rule out peritonitis.

After transferring to surgery ward in the day 4, liquid diet started slowly, and she was ambulated. During the admission, Clexan® (40 mg-daily) and vitamin C (250 mg-BD) was prescribed. No rising in temperature was detected in the patient, and the abdominal pain gradually subsided. At the day 8, she was discharged with oral cefixime, clindamycin, and pantoprazole with the good clinical condition.

Discussion

The prevalence of bowel perforation is increasing with the rapidly growing volume of procedures performed (4). Although some studies confess on the definite role of surgery for the management of colonoscopic perforation (5,14-16), surgery is indicated

in the presence of a large perforation, and in the setting of generalized peritonitis or ongoing sepsis (17). Colonoscopic perforations requiring surgery are catastrophic events with high mortality, morbidity and reoperation rates (18). Conservative treatment is recommended for patients with the following conditions: good general health, silent asymptomatic perforations, localized peritonitis without signs of sepsis, early diagnosis, and a proper colonic preparation (12,16,19). Our patient had no signs and symptoms of generalized peritonitis or sepsis, and improvement of the patient's general condition was seen within 8 days of antibiotic therapy and conservative management.

Early diagnosis of colonic perforation after colonoscopy (within 24 hours) can lead to a good treatment and can produce good prognosis with short hospital days (1,20). The colonoscopic perforation in our patient was diagnosed immediately within colonoscopy.

Although most of the perforations happen after therapeutic colonoscopies (1,17), our case experienced perforation after diagnostic colonoscopy.

Approach to colonoscopic perforations should be individualized according to clinical findings of the patients. Conservative management of the patients with early diagnosis of perforation and no signs and symptoms of peritonitis or sepsis could be the modality of choice.

Acknowledgement

We are thankful for the valuable cordial and dedicated cooperation of Clinical Research Development Unit of Velayat hospital.

References

1. Oh JE, Shim SG. Colonoscopic perforation; A 10-year experience in Single General Hospital. *Korean J Gastroenterol* 2009;54:371-376.
2. Taupin D, Chambers SL, Corbett M, Shadbolt B. Colonoscopic screening for colorectal cancer improves the quality of life measures: a population-based screening study. *Health Qual Life Outcomes* 2006;4:82.
3. Forde KA. Colonoscopic screening for colon cancer. *Surgery Endosc* 2006;20:5471-5474.
4. Bielawska B, Day AG, Liberman DA, Hookey LC. Risk factors for early colonoscopic perforation include non-gastroenterologist endoscopists: a multivariable analysis. *Clin Gastroenterol Hepatol* 2014;12:85-92.
5. Tranowski W, Kaminski P, Krzseniak N, Janaszek L. Management of colonoscopic perforations of large bowel.

- Pol Merkur Le Karski 2011;31:340-4.
6. Kang HY, Kang HW, Kim SG, Kim JS, Park KJ, Jung HC, et al. Incidence and management of colonoscopic perforations in Korea. *Digestion* 2008;78:218-23.
 7. Luning TH, Keemers-Gels ME, Barendregt WB, Tan AC, Rosman C. Colonoscopic perforations: a review of 30366 patients. *Surg Endosc* 2007;21:994-997.
 8. Taku K, Sano Y, Fu KI, Saito Y, Matsuda T, Yoshino T, et al. Iatrogenic perforation associated with therapeutic colonoscopy: a multicenter study in Japan. *J Gastroentrol Hepatol* 2007;22:1409-1414.
 9. Iqbal CW, Chun YS, Farley DR. Colonoscopic perforations: a retrospective review. *J Gastrointest Surg* 2005;9:1229-135.
 10. Cobb WS, Heniford BT, Sigmon LB, Simms C, Kercher KW, Matthews BD. Colonoscopic perforations: incidence, management, and outcomes. *Am Surg* 2004;70:750-7.
 11. Anderson ML, Pasha TM, Leighton JA. Endoscopic perforation of the colon: lessons from 10-year study. *Am J Gastroentrol* 2000;95:3418-3422.
 12. Damore LJ, Rantis PC, Vernava AM, Longo WE. Colonoscopic perforations, Etiology, Diagnosis, and management. *Dis Colon Rectum* 1996;39:1308-140.
 13. Shi X, Shan Y, Yu E, Fu C, Meng R, Zhang W, et al. Lower rate of colonoscopic perforation: 110785 patients of colonoscopy performed by colorectal surgeons in a large teaching hospital in china. *Surgical Endoscopy* 2014;28:2309-16.
 14. Lo Ya, Beaton HL. Selective management of colonoscopic perforations. *J Am Coll Surg* 1994;179:333-7.
 15. Iqbal CW, Askegard-Giesmann JR, Pham TH, Ishitani MB, Moir CR. Pediatric endoscopic injuries: incidence, management, and outcomes. *J Pediatric Surgery* 2008;43:911-5.
 16. Soliman A, Grundman M. Conservative management of colonoscopic perforation can be misleading. *Endoscopy* 1998;30:790-2.
 17. Sagawa T, Kakizaki S, Iizuka H, Onozato Y, Sohara N, Okamura S, et al. Analysis of colonoscopic perforations at a local clinic and a tertiary hospital. *World J Gastroentrol* 2012;18:4898-4904.
 18. Van der Sluis FJ, Loffeld RJ, Engel AF. Outcome of surgery for colonoscopic perforation. *Colorectal Disease* 2012;14:e187-e190.
 19. Castellví J, Pi F, Sueiras A, Vallet J, Bollo J, Tomas A, et al. Colonoscopic perforation: useful parameters for early diagnosis and conservative treatment. *Int J Colorectal Dis* 2011;26:1183-90.
 20. Atharoo M, Gurdeep S, Goldfar B, Michael A. Treatment and outcomes of iatrogenic colon perforations at a community teaching hospital. *Am Surg* 2012;78:975-8.