

Huge Intracanal lumbar Disc Herniation: a Review of Four Cases

Farzad Omid Kashani and Mohammad Faraji Rad

Orthopedic Research Center, Imam Reza Hospital, Mashhad University of Medical Sciences, Mashhad, Iran

Received: 11 Feb. 2014; Accepted: 22 Oct. 2014

Abstract- Lumbar disc herniation (LDH) is the most common cause of sciatica and only in about 10% of the affected patients, surgical intervention is necessary. The side of the patient (the side of most prominent clinical complaints) is usually consistent with the side of imaging (the side with most prominent disc herniation on imaging scans). In this case series, we presented our experience in four cases with huge intracanal LDH that a mismatch between the patient's side and the imaging's side was present. In these cases, for deciding to do the operation, the physicians need to rely more on clinical findings, but for deciding the side of discectomy, imaging characteristic (imaging side) may be a more important criterion.

© 2015 Tehran University of Medical Sciences. All rights reserved.

Acta Med Iran 2016;54(1):79-82.

Keywords: Lumbar disc herniation; Surgery; Discectomy; Sciatica

Introduction

Lumbar disc herniation (LDH) is the most common cause of sciatica and only in about 10% of the affected patients, surgical intervention is necessary (1). As in 30% of normal individual persons lumbosacral magnetic resonance imaging (MRI) may show some major abnormalities, it's usually learned that imaging scans should not be so important in our decisions, and we'd better mostly rely on our clinical findings (2,3). Therefore, in the patients with LDH, these are history and physical exams that usually lead to decision making for surgical intervention (4,5).

In typical LDH, regardless of the surgical technique applied for discectomy, side of the operation is usually determined by the side of maximum disc herniation observed on imaging scans (3). This side is usually consistent with the side of maximum clinical discomfort. In the patients with huge intracanal LDH, both legs may be affected in the absence of any clinical findings in favor of cauda equina syndrome and in some rare cases, the side of maximum clinical complaints may not be consistent with the side of maximum imaging herniation. In these patients, the side of the operation is determined by the clinical findings (the patient's side with the more prominent complaint) or by the imaging findings (the side with more prominent disc herniation)?

In this case series, we presented our experience in four cases with huge intracanal LDH that a mismatch

between patient's and imaging's side was present.

Case Report

Case 1

A 45-year-old female presented with long-term low back pain (LBP) and severe left leg pain and paresthesia for 2 months. In physical examination, straight leg raising (SLR) was positive on both sides while big toe extension force according to manual muscle testing was poor (2/5) on left and good (4/5) on the right side. The patient mostly complained from left leg. No clinical findings were observed in favor of cauda equina syndrome, and all deep tendon reflexes were intact. She had a history of unsuccessful physical and hydrotherapy. In MRI evaluation (Figure 1), huge intracanal L4-L5 LDH with predominantly right side protuberance was observed.

We decided to operate her from the patient's side (left) and intraoperatively, left conjoined nerve roots under severe compression was observed, and we could not decompress them safely from this side. After changing the side of the operation, a huge intracanal sequestered disc was removed easily and with minimal dissection. After returning to the previous side, both conjoined roots were completely decompressed and moved freely (Figure 2).

Corresponding Author: F. Omid-Kashani

Department of Orthopedic, Mashhad University of Medical Sciences, Mashhad, Iran
Tel: +98 513 854 3031, Fax: +98 513 8595023, E-mail address: omidif@mums.ac.ir

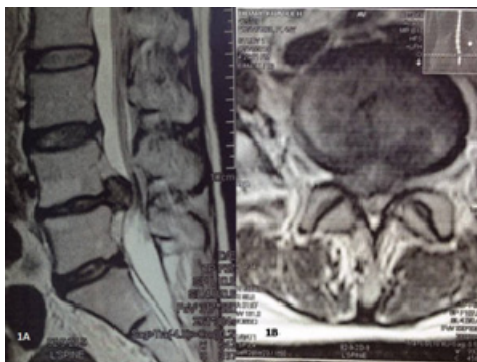


Figure 1. A 45-year-old female (case 1) with huge intracanal L4-L5 LDH (Figure 1A) presented with predominantly left-sided sciatalgia. In MRI scanning (Figure 1B), the predominant side of involvement was the right side (a mismatch between clinics and imaging’s sides).

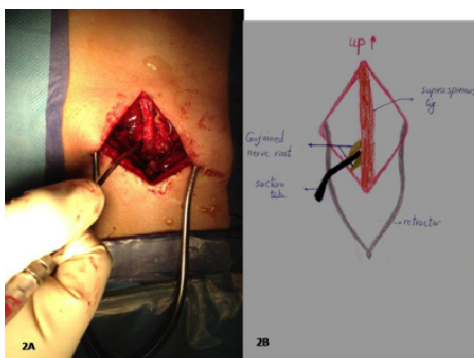


Figure 2. Case 1, after sequestrectomy from the right side, left conjoined nerve roots were completely relaxed and freely moved. The suction tube was placed between two conjoined roots for better visualization (Figure 2A and 2B).

Case 2

A 43-year-old patient presented to our clinic with a chief complaint of increasing left leg pain and paresthesia for 6 weeks. He noted that at the beginning of the disease, the pain was in the right lower extremity, but lately, the major side of involvement was changed to the left. He had no problem with voiding and defecation, and there was no anesthesia in the saddle (groin) area. In physical examination, SLR test was positive on the left side, muscular strength was intact, but Achilles’ deep

tendon reflexes were absent on both sides. MRI showed a huge intracanal L5-S1 LDH with predominantly right side herniation (Figure 3). We relied mainly on the clinics and operated him from the left side. During the operation, S1 nerve root was observed to be tightly under pressure from a huge intracanal disc, but safely sequestrectomy was impossible from this side. We changed the side of the operation, and a massive disc sequestrum was excised easily with trivial dissection and tissue resection.

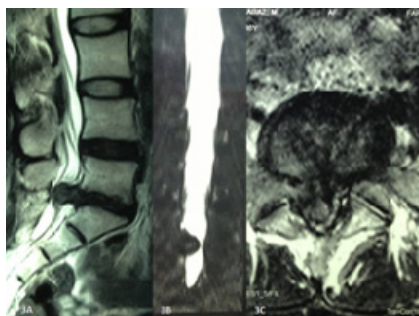


Figure 3. A 43-year-old man (case 2) with huge intracanal L5-S1 LDH (Figure 3A) presented with predominantly left sided sciatica. In myelogram and axial images, the predominant side of herniation was right (Figure 3B and 3C). There was a mismatch between clinical and imaging’s sides.

Case 3

A 26-year-old female presented with a history of chronic LBP and both legs for about three years. Her pain and disability were deteriorated during recent three weeks. At presentation, she mainly complained of left lower extremity pain and paresthesia. She mentioned paresthesia only on the dorsum surface of the left foot. Deep tendon reflexes were intact, and there were no clinical findings in favor of cauda equina syndrome. SLR tests are positive on both sides (left in 20°-30°, and

right at 35°-40°). Extensor hallucis longus strength was poor (2/5) in left and excellent (5/5) in right. MRI revealed a relatively huge intracanal L4-L5 LDH in which the center of herniation was more inclined to the right (Figure 4). Traditionally, we trusted again on the patient's side and operated her from the left side, and the story was repeated again. We eventually could decompress the neural elements more safely and easily from the right side.

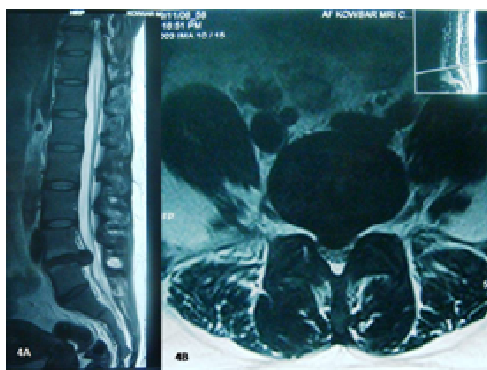


Figure 4. Case 3 who presented with relatively huge intracanal L4-L5 LDH (Figure 4A). The center of herniation was more inclined to the right (Figure 4B) while clinical discomfort was more obvious on the left side (mismatch).

Case 4

A 36-year-old man was referred to our clinic with 6 weeks duration of left leg sciatica. He had no complaints from his back while left leg discomfort was getting worse and unbearable. Paresthesia was present on the plantar surface of both feet. Clinical examination revealed a weakened strength of the plantar flexor (fair or 3/5 on the left side and good or 4/5 on the right) associated with a decreased Achilles' deep tendon reflexes on the only left side. SLR test was positive mainly on the left side. On imaging study, a relatively

big extruded intracanal L5-S1 LDH was discovered while the major herniated mass was placed on the right side (Figure 5). Again we encountered with a mismatch between patient's side and imaging's side but this time, we performed an imaging's side (in this case; right side) discectomy. During the procedure, the extruded disc was excised easily and completely. At the end of the operation, both left, and right nerve roots were checked from this side that were sufficiently relaxed and released.

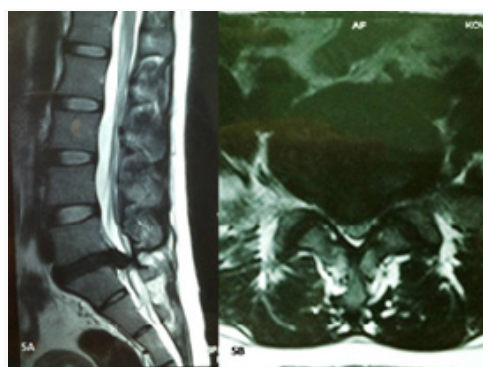


Figure 5. Case 4 with a big intracanal L5-S1 LDH (Figure 5A)

On axial image, most of the herniated disc was placed on the right side while the predominant clinical side was left (mismatch)

Discussion

Fortunately, the majorities of LDH patients spontaneously recover and will not need surgery. Therefore, even in developed countries and well-equipped spine centers, early imaging of these patients has been criticized (3). Inappropriately indicated cases with LDH, imaging scans including MRI usually confirm the clinical level and side of LDH. In this review, we presented four rare cases with clinical and imaging's side mismatch.

Van Rijn *et al.*, in 2006 studied 57 patients with unilateral symptomatic LDH to compare clinical localization with imaging findings (3). They observed that MRI revealed some abnormalities on the asymptomatic side in 33% of the cases and asymptomatic nerve root compression in 23%. They finally reported that in more than two-thirds of the symptomatic LDH patients, there was a mismatch between clinical and MRI findings and noted that these inconsistencies make worse the surgical decision.

As our experience in dealing with this mismatched group of patients increased, we selected the operation side based on imaging's side, not the clinical side. Similar to our approach, Akdeniz *et al.*, performed laminotomy via the side of imaging for surgical discectomy in these especially mismatched patients (6). They operated five cases with contralateral clinical symptoms and imaging signs and reported satisfactory clinical outcomes. Comparable to our study, they proposed side selection according to the imaging's side. In another similar study, Sucu and Gelal also evaluated the efficacy of imaging's side surgical intervention in the LDH patients with contralateral symptoms (7). They reported five surgically treated patients with contralateral clinical and imaging's side of affection. They observed that the morphology of the herniated disc in all of these cases was alike: a broad-based mostly central LDH with the apex deviated away from the side of the symptoms. We also observed these characteristics on imaging scans of our patients. The probable hypothesis they had proposed was a traction rather than

compression force for evolving the contralateral complaints. They recommended that in these surgically treated cases, intervention only from the imaging's side is enough and satisfactory.

In conclusion, in the patients with huge intracanal LDH, a mismatch maybe rarely observed between the patient's side (the side of most prominent clinical complaints) and the imaging's side (the side with most prominent disc herniation on imaging scans). In these cases for deciding to do the operat, the physicians need to rely more on clinical findings, but for deciding the side of discectomy, imaging characteristic may be a more important criterion.

References

1. Frymoyer JW. Back pain and sciatica. *N Engl J Med* 1988;318(5):291-300.
2. Boden SD, Davis DO, Dina TS, et al. Abnormal magnetic-resonance scans of the lumbar spine in asymptomatic subjects. A prospective investigation. *J Bone Joint Surg Am* 1990;72(3):403-8.
3. van Rijn JC, Klemetso N, Reitsma JB, et al. Symptomatic and asymptomatic abnormalities in patients with lumbosacral radicular syndrome: Clinical examination compared with MRI. *Clin Neurol Neurosurg* 2006;108(6):553-7.
4. Danon-Hersch N, Samartzis D, Wietlisbach V, et al. Appropriateness Criteria for Surgery Improve Clinical Outcomes in Patients With Low Back Pain and/or Sciatica. *Spine* 2010;35(6):672-83.
5. Pearson A, Lurie J, Tosteson T, et al. Who should have surgery for an intervertebral disc herniation? Comparative effectiveness evidence from the spine patient outcomes research trial. *Spine* 2012;37(2):140-9.
6. Akdeniz T, Kaner T, Tutkan I, et al. Unilateral surgical approach for lumbar disc herniation with contralateral symptoms. *J Neurosurg Spine* 2012;17(2):124-7.
7. Sucu HK, Gelal F, Lumbar disk herniation with contralateral symptoms. *Eur Spine J* 2006;15(5):570-4.