

Liver Hydatid Cyst and Acute Cholangitis: a Case Report

Behzad Nemati Honar¹, Gholamhossein Hayatollah¹, Mohammadreza Nikshoar¹,
Mojgan Forootan², and Ali Mohammad Feizi³

¹ Department of General Surgery, Imam Hossein Hospital, Shahid Beheshti University of Medical Sciences, Tehran, Iran

² Department of Gastroenterology, Imam Hossein Hospital, Shahid Beheshti University of Medical Sciences, Tehran, Iran

³ Department of Radiology, Imam Hossein Hospital, Shahid Beheshti University of Medical Sciences, Tehran, Iran

Received: 29 Mar. 2014; Accepted: 23 Dec. 2014

Abstract- Amongst the cause of cystic hepatic disease, hydatid cyst is common in the Asia, South America, and Africa. The definitive therapy for hepatic hydatid disease is surgical resection. Rupture of the hydatid cyst into the biliary tree can lead to serious cholangitis. In this report, a 22-year-old man is presented with the signs and symptoms of obstructive jaundice and cholangitis. Ultrasonography reported dilated common bile duct (CBD) with sludge and stones, a hydatid cyst adjacent to the gall bladder and mild thickening of gallbladder wall without a stone. MRCP revealed dilated CBD with a cyst in segment fifth of liver. Due to signs and symptoms of obstructive jaundice in addition to lab data and imaging modalities, the ruptured hydatid cyst into a biliary tree was considered, and surgical intervention was performed to extract daughter vesicles from the CBD. Post intervention, signs and symptoms and cholestasis enzymes were subsided.

© 2016 Tehran University of Medical Sciences. All rights reserved.

Acta Med Iran, 2016;54(4):286-288.

Keywords: Cholangitis; Hydatid cyst; Biliary obstruction

Introduction

Amongst the cause of cystic hepatic disease, hydatid cyst (caused by parasite *E. granulosa*) is common in the Middle East, India and Africa (1). The main complications of hydatid disease are an infection of the cyst and rupture into either the peritoneum, biliary tree or other organs (2). One of the most common complication of hepatic hydatid cyst is rupture of the cyst caused by raised pressure. A rupture of the bile ducts cause jaundice due to biliary obstruction (3). Intra biliary rupture occurs with an incidence between 5% and 25% (4,5). The effective procedure to treatment is T-tube drainage and choledocoduodenostomy that choledocoduodenostomy is most effective (6,7).

Case Report

A 22-year-old man was admitted to emergency department with epigastric pain irradiating to the right upper abdominal quadrant (RUQ), in 2 days preceding admission. In addition, the patient had nausea, vomiting, anorexia, and dark urine. He had neither previous disease such as GI problem, hepatitis nor history of trauma, IV drug use, and transfusion. He did not give

any history of alcohol usage, and his family history was not significant. At admission, he was noted to have a temperature of 38, blood pressure of 130/70 mm/Hg, heart rate of 92/min and respiratory rate of 18/min.

Physical examination showed icterus sclera, tenderness in epigastrium and RUQ without rebound tenderness, murphy sign was negative. The other part of the abdomen was soft, and the remainder of his examination was unremarkable. Lab data revealed normal leukocyte count raised from 10000 to 15000 after admission, direct hyperbilirubinemia elevated from t-bili:6 to 9 d-bili:4.6 to 7 before operation, Alkaline phosphatase was 700, in liver function test ALT:181 AST:70, the other finding including hemoglobin, urea, amylase, electrolytes, coagulation test, and albumin were normal. Ultrasound showed mild thickening of gallbladder wall, cystic lesion with 52*42 mm in diameter adjacent to gall bladder with suspicion of hydatid cyst, dilated CBD (15 mm) with sludge and stones in it in addition to mild splenomegaly (Figure 1). MRCP revealed dilated CBD with a cystic lesion in the fifth segment of liver that communicated with bile duct (Figure 2). Diagnosis of acute cholangitis was made, and it was suspected that biliary obstruction was directly caused by hydatid cyst rupture with debris and daughter

Corresponding Author: Gh. Hyatollah

General Surgeon, Shahid Beheshti University of Medical Sciences, Tehran, Iran

Tel: +98 913 3140415, Fax: +98 21 42910703, E-mail address: dr.hayatollah@yahoo.com

cyst blocking the CBD. About 5 days after initial therapy, surgical intervention was performed. Surgical exploration showed a 5*5 cm hydatid cyst in a fifth and sixth segment of liver and dilated CBD. At first cholecystectomy was performed and hydatid cyst unroofed. There was a communicating fistula between cyst and intrahepatic duct at the base of the cyst that it was closed with suturing (Figure 3). Choledochotomy was performed, and daughter cyst and debris was extracted (Figure 4,5). Intraoperative cholangiography (IOC) revealed stenosis of Oddi then choledochoduodenostomy was performed. After surgical intervention, the patient was free of symptoms with only slightly increased cholestasis enzymes.

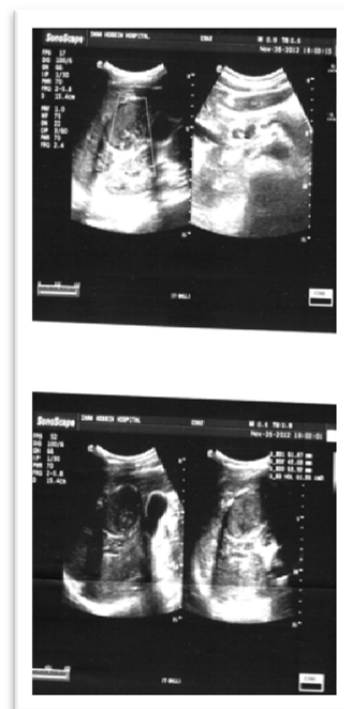

Figure 1. Ultrasound images showed liver hydatid cyst and dilated CBD.

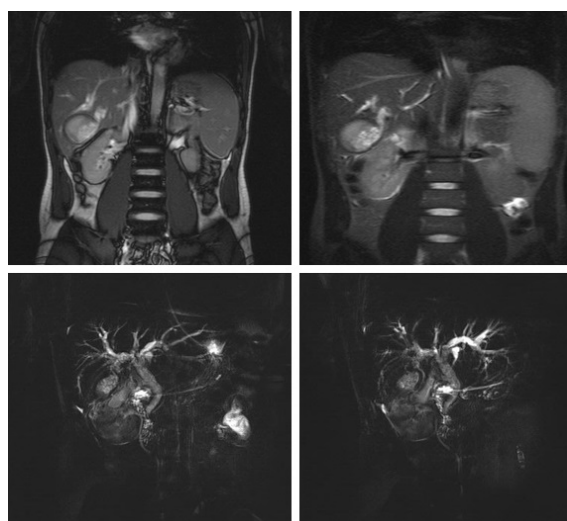


Figure 2. MRCP images are showing Cystobiliary fistula

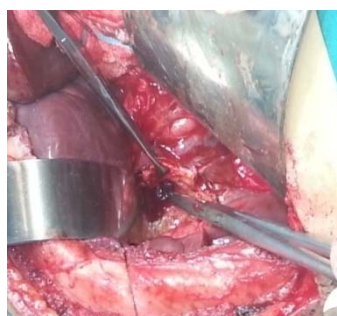

Figure 3. Hydatid cyst communicating with bile duct

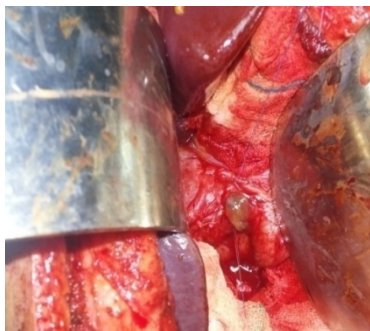

Figure 4. Daughter cyst in CBD

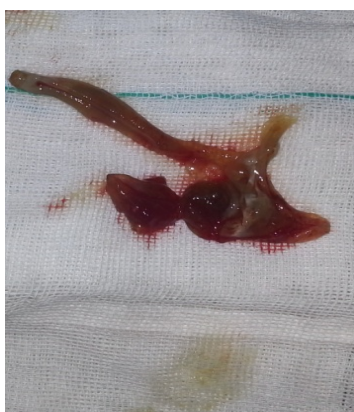

Figure 5. Daughter cyst and debris

Discussion

Cystic lesion of the liver includes simple cysts, cystadenocarcinomas, abscesses, polycystic liver disease, and hydatid cysts. Individuals with hydatid cyst are often asymptomatic, but sometimes the cyst can rupture into the peritoneum, biliary tree, or pleura (8). The communicating intra biliary rupture may occur with occult (10-37%) or frank (3-17%). Occult rupture is usually silent; but in frank rupture, daughter vesicle, and fragmented membranes cause obstruction, cholangitis or septicemia (9).

Ultrasonography can reveal complicated hydatid cyst, communication of the cyst with the duct, dilatation of biliary tree, thickened and doubled layered bile duct wall as an expression of cholangitis. MRCP may show daughter cyst (10).

ERCP provides more comprehensive information. It can show impacted daughter cyst in the ampulla of Vater, displacement and distortion of the intra hepatic duct, differentiated cholestasis due to ruptured cyst from the other causes. ERCP is an alternative treatment for the patient with biliary hydatid disease. In the case of

cystobiliary fistula, a surgical cure of the cyst is mandatory. The most common type of cure is partial cystectomy with primary closure, suture of the cystobiliary fistula, CBD exploration, and IOC. If the biliary tract is clean, T-tube drainage is sufficient if not, or stenosis of Oddi is present, choledochoduodenostomy should be considered (2,11).

Although it is not frequent to have a rupture of the liver hydatid cyst into the bile duct, but in patients with the evidence of liver hydatid cyst and sign and symptom of acute cholangitis, it must be considered. It seems that the most effective treatment for this condition is open surgical intervention as we performed.

References

1. Laing A, Mantry P. A case of hepatic hydatids causing biliary obstruction: a case report and review of the literature. *Pract Gastroenterol* 2006;69-73.
2. Elhamel A, Murthy BS. Hepatic hydatid disease in Libya. *Br J Surg* 1986;73(2):125-7.
3. Spâchez Z, Osian G, Onica A, et al. Ruptured hydatid cyst of the liver with biliary obstruction: presentation of a case and review of the literature. *Rom J Gastroenterol* 2004;13(3):245-50.
4. Vignote ML, Mino G, de la Mata M, et al. Endoscopic sphincterotomy in Hepatic hydatid disease open to the biliary tree. *Br J Surg* 1990;77(1):30-1.
5. Dadoukis J, Gamvros O, Aletras H. Intrabiliary rupture of the hydatid cyst of the liver. *World J Surg* 1984;8(5):786-90.
6. Paksoy M, Karahasanoglu T, Carkman S, et al. Rupture of the hydatid disease of the liver into the biliary tracts. *Dig Surg* 1998;15(1):25-9.
7. Ovnat A, Peiser J, Avinoah E, et al. Acute cholangitis caused by ruptured hydatid cyst. *Surgery* 1984;95(4):497-500.
8. Greulich T, Kohler B. Obstructive jaundice caused by spontaneous rupture of an *Echinococcus granulosus* cyst into the bile duct system. *Z Gastroenterol* 2000;38(4):301-6.
9. Lewall DB, McCorkell SJ. Rupture of echinococcal cyst: diagnosis, classification, and clinical implications. *AJR Am J Roentgenol* 1986;146(2):391-4.
10. von Sinner WN. Ultrasound, CT and MRI of ruptured and disseminated hydatid cyst. *Eur Radiol* 1990;11(1):31-7.
11. Koksall N, Muftuoglu T, Gunerhan Y, et al. Management of intrabiliary ruptured hydatid disease of the liver. *Hepatogastroenterology* 2001;48(40):1094-6.