

Primary Disseminated Hydatid Cysts in a 14-Year-Old Girl: A Case Report

Nazanin Fallah¹, Soghra Rabiee², and Mohammad Fallah³

¹ Department of Anesthesiology, Besat Hospital, Hamadan University of Medical Sciences, Hamadan, Iran

² Department of Obstetrics and Gynecology, Fatemeh Hospital, Hamadan University of Medical Sciences, Hamadan, Iran

³ Department of Parasitology and Mycology, School of Medicine, Hamadan University of Medical Sciences, Hamadan, Iran

Received: 18 Sep. 2016; Accepted: 25 Nov. 2017

Abstract- Hydatid cysts in humans usually located in the liver or lungs primarily and some case in the other organs. Sometimes, because the trauma or medical manipulating, the cyst may be rupture and protoscoleces spillage resulted in secondary hydatid cyst. Primary dissemination of cyst to multiple organs is a rare phenomenon. Herein, we reported a 14-year-old teenage female patient with symptoms of abdominal pain with an unusual ultrasonographic and computed tomographic presentation mimicking polycystic ovarian syndrome PCOS. Due to numerous masses in the retrovesical region, she was admitted for surgical treatment in the gynecology ward, and after laparotomy, more than 50 cysts removed her internal organs.

© 2017 Tehran University of Medical Sciences. All rights reserved.

Acta Med Iran 2017;55(11):726-729.

Keywords: Hydatid cyst; Human; Disseminated

Introduction

Hydatidosis is an endemic parasitic disease distributed throughout the world. *Echinococcus granulosus*, a tiny canine intestinal tapeworm, is the cause of human hydatid cysts. This parasitic infection is more common in countries with sheep-rising dominance and agriculture that facilitate people in close contact with dogs and sheep-dogs contacts as well (1).

These countries include Mediterranean region, South America, East Africa, and Australia, the Middle East including Iran as well (2). Liver and lungs are most frequently involved although hydatid cyst has seen in any organ due to hematogenous spread of parasite embryo. Primary disseminated hydatid cysts are rare, except in the fertile cysts if these cysts manipulate without caution or a sharp instrument trauma causes the rupture, and opening surgery without precaution and aspiration of cyst content may hydatid fluid spillage and causes seeding protoscoleces in viscera and produce secondary cysts.

Case Report

A 14-year-old girl, the resident of Asad Abad, a small city in Hamadan Province in the west of Iran, presented with chronic abdominal distention and pain with big abdomen mass in the lower abdomen in the

physical examination referred to our hospital. Her primary diagnosis was PCOS by radiologist. The abdominal swelling had been gradually increasing in size. She had no history of abdominal operation, car accident or fall of height.

After exploratory laparotomy, we found multiple cysts (over 50) with the different sizes in her ovaries, pelvic cavity (over 20 cysts), peritoneum, mesentery, omentum, and a cyst in the left lobe and 3 in the right lobe of liver with invasion to the diaphragm (Figure 1).



Figure 1. Multiple hydatid cysts removed by surgical excision from abdominal and pelvic cavities and related organs in a 14-year-old girl

The size of some cysts on the retroperitoneum was about 88 x 59 mm (Figure 2) and in the intrapelvic was 84 x 55 mm. After removing the cysts and pathological study, masses identified as hydatid cysts that all of them

Corresponding Author: S. Rabiee

Department of Obstetrics and Gynecology, Fatemeh Hospital, Hamadan University of Medical Sciences, Hamadan, Iran
Tel: +98 918 1111050, Fax: +98 81 38283939, E-mail address: rabiei@umsha.ac.ir

were fertile and contained thousands of viable protoscolecemes (Figure 3).

The patient had no any history of surgery for hydatid cyst or other abdominal problems. She had not also any history of car accident, falling from height and also any type of sharp trauma to the abdomen area. However, her mother mentioned tow main risk factors of *E. granulosus* infection for this patient: eating raw

vegetable without washing frequently, when her mother was cleaning the vegetables, and performing resuscitation for a newly expired puppy by mouth-to-mouth breathing! The patient released from the hospital after surgery and removing various cysts from pelvic and abdominal cavities, with the good general condition. We diagnosed this case as a primary disseminated hydatidosis.

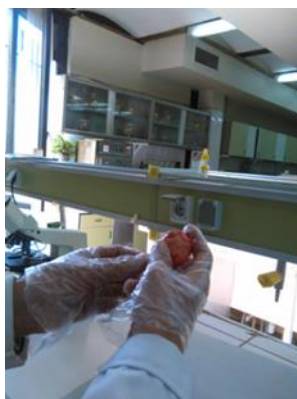

Figure 2. A large cyst removed from omentum. This cyst was fertile, contained thousands of protoscolecemes

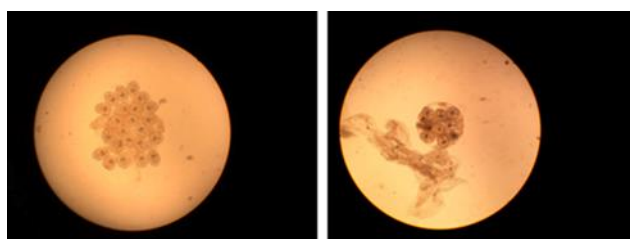


Figure 3. Multiple protoscolecemes showed fertile cysts in the patient (left), a brood capsule contained protoscolecemes from the cyst removed of omentum (right)

Discussion

raising areas of the world, that is endemic, even hyperendemic in southern Brazil, Argentina, Uruguay, Chile, and Peru; in Bulgaria, Sardinia, Cyprus, Turkey, in Lebanon, Iran; in scattered parts of Africa such as Kenya; in central Asia and northern China; and in New Zealand and southern Australia.

Hydatidosis is an endemic disease in all parts Iran, mostly seen in peoples who have had close contacts with dogs and sheep, usually for a long time. Hamadan is a sheep rising province, and previous studies indicated high infection rates of *E. granulosus* in the stray dogs in this city. In the first study it was 48.2% (1995), and in a recent study (2015) it reports about 37.9% (3,4). Many cases of hydatid cyst operated annually in the local hospitals (5,6).

Hydatid cysts can appear in any part of the human

anatomy, but, up to 70% are located on the liver, usually on the right lobe, and lungs involve up to 20% of cases and less than 10% in the other sites such as bones, spleen, heart, and CNS (7). The ovary and the pararectal regions are very rare locations for the hydatid cyst (8,9,10).

Primary disseminated extrahepatic abdominal or pelvic cyst is a rare phenomenon. The rate of incidence of mesenteric and omental cysts has been previously reported from one case per 27,000 hospital admissions to one per 100,000 admissions (11). These lesions are generally reported to be more common in females and in the ages ranged 20-50. The larvae (hydatid cyst) is a slow growing lesion that takes many years produce symptoms, especially if locates in the cavities such peritoneal, pelvic or chest cavity. Unfortunately, there are no specific signs or symptoms for hydatid cysts located in the pelvic area and the disease usually

Primary disseminated hydatidosis

remains asymptomatic for years (12).

More often, intraperitoneal hydatid cysts usually develop secondary to spontaneous, traumatic or iatrogenic rupture of hepatic, splenic or mesenteric cysts. Primary disseminated cysts that involving multiple organs, peritoneal or pelvic, without evidence of traumatic accidents is very rare. Usually, pelvic cyst most often is secondary to the hematogenous and lymphatic distribution of the protoscoleces from the hepatic hydatid cysts surgery and or accidentally micro ruptures. Ovarian, tubal and uterine cysts have reported in the literature. We report the primary disseminated multiple cysts throughout the abdominal cavity and also pelvic region hydatid cyst mimicking OPCS and endometriosis, in addition to liver involvement that didn't diagnose before surgery.

Pelvic hydatid disease can present with vague abdominal pains due to irritation, swelling, menstrual irregularities, infertility and pressure symptoms involving the adjacent organs (vascular structures, ureters, bladder, and rectum). In our case-patient had severe abdominal and pelvic pain in the vaginal and abdomen examination, ultrasonographic and tomographic examination reported pararectal and adnexal multiple solid oval masses so that polycystic ovarian syndrome and endometriosis was thought firstly. Radiography, ultrasound (US) and CT studies are important for the diagnosis of hydatid disease, but by these tools also HC diagnosis may miss, however, according to some reports imaging tools are important because of the lack of specific clinical signs. Ultrasound is the primary diagnostic tool because of its low cost and high sensitivity (12). The US are cost-effective in endemic areas and when the diagnosis of hydatid cyst is certain. However, ultrasonography is less accurate in localizing and delineating the extent of the cyst. The US are particularly useful for the detection of cystic membranes, septa, and hydatid sand within the cyst. Unfortunately, in the present case, the imaging methods could not help correct diagnosis of disease in the primary admission of the patient.

There is no serological and immunological test pathognomonic for hydatid disease. A negative serological test does not rule out echinococcosis, as our case was also sero-negative.

Therefore, the test result must always be compared with the radiological findings. The role of plain X-ray in the diagnosis of disseminated abdominal hydatidosis is very limited and nonspecific.

The risk of rupture and anaphylaxis increases at exploration if the diagnosis is not made preoperatively,

especially in the ovarian cysts. Unfortunately, we have some dramatic experiences in this field. Cyst puncture with the aspiration of fluid, which is helpful in diagnosis, should be avoided as it may cause acute anaphylaxis and seeding protoscoleces and secondary hydatidosis.

Surgical treatment can be either radical or conservative. Whenever possible, total cystectomy is the gold standard for hydatid cyst treatment. For peritoneal cysts firmly attached to intraperitoneal viscera, uncovering and drainage with high cautiousness have been proven to be a safe method. It is important that the abdominal cavity is isolated with gauze soaked in 20% hypertonic saline solution to avoid secondary hydatosis and allergic reaction.

Retrovesical hydatidosis refers to the rupture of a primitive intraperitoneal cyst (hepatic or splenic) with its later growing in the pouch of Douglas (13). In this case, we could not find any pieces of evidence of rupture of already present cysts in other abdominal organs, as the reason for secondary cysts production. Primary localization of retrovesical cyst is an unusual entity even in endemic areas and accounts for only 0.1-0.5% of hydatid cases (14).

Primary disseminated hydatid disease is a very rare entity. Multiple pelvic masses with abnormal radiologic findings, primary ovarian and pelvic cyst; hydatid cyst should be strongly considered in the differential diagnosis of masses in endemic regions (15). HCs should be considered by the gynecologist in the differential diagnosis of all pelvic masses, especially in the ovarian cysts and also in areas where hydatid disease is endemic. Although ultrasound is the primary imaging diagnostic tool, it must accompany another para-clinic tests. A chest radiograph and an abdominal ultrasound scan should always be requested to look for probable HCs in the liver or lung that cysts probability. Extra-hepatic primary abdominal disseminated cysts are mimicking malignancy or poly cystic ovarian syndrome, or even endometriosis and adnexal cystic mass (16,17,18), is a rare presentation and should be kept in mind during the diagnosis of chronic pain and masses detections in the abdomen or pelvis.

References

1. Dakkak A. Echinococcosis/hydatidosis: A severe threat in Mediterranean countries. *Vet Parasitol* 2010; 174: 2-11.
2. Otero-Abad B, Torgerson PR. A Systematic Review of the Epidemiology of Echinococcosis in Domestic and Wild Animals. *PLoS Negl Trop Dis* 2013;7:e2249.

3. Fallah M, Taherkhani H, Sadjjadi M. Echinococcosis in the stray dogs in Hamadan, west of Iran. *Iranian J Med Sci* 1995; 20:170-2.
4. Rahmati Kh, Maghsood A, Matini M, Motavalli Haghi M, Fallah N, Fallah M. Study of intestinal helminthes of stray dogs and their public heath importance in Hamadan, 2015. *Sci J Hamadan Univ Med Sci* 2016; 23: 214-20.
5. Fallah M, Fashandaki F, Valadan M. Operated hydstatid cysts in Hamadan hospitals during 10 year (1979-1989). *Daru Darman* 1992; 9:27-3.
6. Fallah N, Fallah, M Rahmati Kh, Rabiee S. A retrospective study on 182 cases Human Hydatidosis Based on Hospital Records in Hamadan West of Iran in 2006 to 2013. *Iran J Parasitol* 2015; 20:108.
7. Budke CM, Carabin H, Ndimubanzi PC, Nguyen H, Rainwater E, Dickey M. et al. A Systematic Review of the Literature on Cystic Echinococcosis Frequency Worldwide and Its Associated Clinical Manifestations. *Am J Trop Med Hyg* 2013; 88:1011-27.
8. Milano CT, Deppe G, Moshirpur JA. Disseminated pelvic Echinococcosis simulating ovarian carcinomatosis: case report and review of pelvic hydatid disease. *Obstet Gynecol Surv* 1981;36:535-40.
9. Ben Adballah R, Hajri M, Aoun K, Ayed M. Retrovesical and retroperitoneal extrarenal hydatid cyst: descriptive study of 9 cases. *Prog Urol* 2000;10: 424-31.
10. Halefoglul AM1, Yasar A. Huge retrovesical hydatid cyst with pelvic localization as the primary site: a case report. *Acta Radiol* 2007;48:918-20.
11. AR Walker, Putnam TC. Omental, mesenteric, and retroperitoneal cysts: a clinical study of 33 new cases. *Ann Surg* 1973;178:13-9.
12. Chelli D, Methni A, Gatri C, Boudaya F, Affes M, Chennoufi MB. Pelvic hydatid (echinococcal) disease; *Int J Gynecol and Obstet*; 2010; 109: 45–48
13. Senarriaga Ruiz de la Illa N, Loizaga Iriarte A, Iriarte Soldevilla I, Lacasa Viscasillas I, Unda Urzaiz M. Pelvic hydatid disease as an example of pelvic masses of uncertain aetiology. *Actas Urol Esp* 2009; 33:1129-32.
14. Kushwaha JK, Sonkar AA, Verma AK, Pandey SK. Primary disseminated extrahepatic abdominal hydatid cyst: a rare disease. *BMJ Case Rep* 2012;2012.
15. Mosca F, Portale TR, Persi A, Stracqualursi A, Puleo S. Uncommon abdominal sites of hydatid disease. Our experience with the surgical treatment of 15 cases. *Chir Ital* 2004; 56:333-44.
16. Ozat M, Kanat-Pektas M, Gungor T. Pelvic hydatid disease mimicking ovarian malignancy. *Arch Gynecol Obstet* 2011;283:921-3.
17. Bozkurt M, Bozkurt DK, Çil AS, Karaman M. Primary ovarian and pararectal hydatid cysts mimicking pelvic endometriosis. *Acta Med Iran.* 2012; 50(12):839-42.
18. Alimohamadi S, Dehghan A, Neghab N. Primary bilateral intrapelvic hydatid cyst presenting with adnexal cystic mass: a case report. *Acta Med Iran.* 2011; 49(10):694-6.