

Warfarin-Induced Breast Necrosis: A Case Report

Aghygh Heidari¹, Feridoun Sabzi²

¹ Department of Anesthesiology, Imam Ali Hospital, Kermanshah University of Medical Sciences, Kermanshah, Iran

² Department of Cardiovascular Surgery, Imam Ali Hospital, Kermanshah University of Medical Sciences, Kermanshah, Iran

Received: 2 Feb. 2016; Accepted: 6 Oct. 2016

Abstract- Warfarin-induced Breast necrosis (WIBN) is an exceedingly rare sequel to warfarin therapy. A close relationship was confirmed between congenital deficiency of protein C and S and warfarin usage. A predilection for this complication has been reported in fatty middle-aged women who are managing by warfarin. The sudden eruption of the bullous lesion, within mean three days after starting of warfarin therapy with or without echymous or petechia is the first sign of WIBN. The maintenance of INR in the low normal range, reducing the loading doses, especially in fatty cases may be a preventive measure in reducing risk and incidence of breast necrosis in the high-risk subjects. Early diagnosis and management are important to prevent significant tissue loss. A rare case of warfarin-related necrosis of the left breast following a mitral valve replacement is reported. Current knowledge and the preventing methods and treatment of this rare complication are reviewed.

© 2018 Tehran University of Medical Sciences. All rights reserved.

Acta Med Iran 2018;56(4):281-284.

Keywords: Warfarin; Necrosis; Breast

Introduction

Skin necrosis following warfarin usage has a wide range of incidence from 0.01 in low-risk subjects to 0.1% of high-risk cases, such as the fatty woman in their 3rd decades of life that treated with warfarin. The known age range for this complication is variable and reported in teenage to 9th decades of life (1). The most common sites of affection are subcutaneous fat that has a thick and multilayer's fat. Besides to breasts, with its specific fat texture, buttocks, internal aspects of thighs, upper arms, the floor of hands, lateral digits and legs, fatty sites of the face, large fatty nose, abdominal wall fat, subcutaneous fat of flank and in the rare cases penis are involved in this complication. The involvement of multiple sites with different shape of the lesion has been found in Warkentin study, in which 35% of subjects have multiple skin lesions, and in 1/5 of cases, lesions are symmetrical. The most common organ involved with this sequel is breast (in 70% of cases) followed by the buttocks and thighs in 20% and remaining cases related to another site (2). Since from the first report by Flood in 1943, less than 40 cases of warfarin-related necrosis of the breast have been explained in English literature, careful literature search showed that this is probably the the first case report of this complication from the Iran.

Early diagnosis of this rare clinical complication of warfarin allows the cardiac surgeon and cardiologist to make a preventive measure for progression of the disease. Knowledge and recognition and early management are key measures to prevent further morbidity or mortality.

Case Report

A 65-year-old complained of breast pain, within 3 days' after an uncomplicated mitral valve replacement. She gave a history of a sudden and progressively increasing a painful mass on a in the left breast. Since the past 3 days, she was operated in a cardiac surgery ward for mitral stenosis where a prosthetic mitral valve inserted and anticoagulation starting with heparin followed by warfarin. In ICU a day after surgery she received 1000 units per hour and concomitantly oral warfarin 10 mg as a loading dose and 7.5 mg daily was consumed by the case. Two days after beginning of heparin and warfarin, INR reached to 22 and heparin was discontinued. On the 3th day after usage of warfarin, the case complained a painful lump in the nipple area of the left breast and admitted in general hospital. The patient was visited by a general surgeon that a probable diagnosis of breast carcinoma was made

Corresponding Author: F. Sabzi

Department of Cardiovascular Surgery, Imam Ali Hospital, Kermanshah University of Medical Sciences, Kermanshah, Iran
Tel: +98 918 1311896, Fax: +98 833 8360041, E-mail address: dr_sabzi@yahoo.com

Warfarin-induced breast necrosis

and a biopsy sends for pathological exam. On postoperative exam, she was anemic, tachypneic, tachycardic with high fever (39°C). Physical exam showed a midline sternal incision of previous valve surgery without any evidence of dehiscence or infection of sternum, subcutaneous or overlying skin. The left breast exam revealed a warm and tender lump underlying the subareolar area and discoloration of the outer skin with a central erosion of the skin. The lump was attached to the nipple and overlying skin, but was mobile in relation to its underlying thoracic fascia (Figure 1). A small lymph node in axillary region was palpable. In an examination of the chest wall sternal tables were stable and fixed and our finding was in the direction of an inflammatory tumor. No other skins like mass were identified in the thigh or buttocks. Her serum hemoglobin level was 10 mg%; with high WBC count 13000/mm³; and normal platelets 400,000/mm³ and INR was 3.1. A sonographic examination of the breast tissue showed a lump with variable echogenicity of tissue with absence of abscess and when we are waiting for Breast biopsy results, treatment with imipenem and gentamicin was started and the cardiologist's advice was considered, the cardiologist ordered that we continue treatment for probable breast infection, and with consideration of warfarin-induced skin necrosis, discontinue warfarin, and replaced with heparin. Warfarin was not restarted. Serum level of ant thrombin III, protein S, protein C Factor V Leiden and lupus anticoagulant was reduced. The serum values for II, VII, and X were normal. On the 3th day of diagnosis, erosion of overlying the skin necrosis, and bullae, were found overlying the diagnosed lump. A surgical debridement showed wide necrosis of the skin and breast tissue. The specimen was sent for cultures and pathology. The residual breast tissue became totally necrotic on the following 3 days. Repeated debridement lead to remaining a quadrant of the breast that in the last debridement was removed. The tissue cultures and pathology were negative for bacterial growth and malignancy consequently. The histology revealed a hemorrhagic necrosis of the breast fat (Figure 2), with concomitant capillary thrombosis, clusters of fibrin deposition and fewer invasions of inflammatory, cells (Figure 3). This clinicopathological finding was consistent with WINB. After total mastectomy, the patient's sign and symptoms recovered and clinical improvement was obtained. Due to skin pliability residual defect easily approximated without any tension was not referred to a plastic surgeon. At 6th months of follow-up, the patients' general condition was good, with the healed mastectomy site.

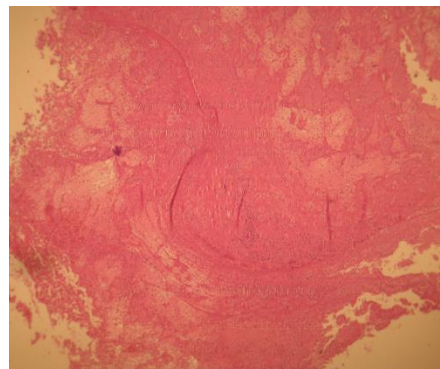


Figure 1. An area of necrotic fat, fibrin, and cellular debris
Eventually, fibrosis may replace the area of degenerated fat with a scar

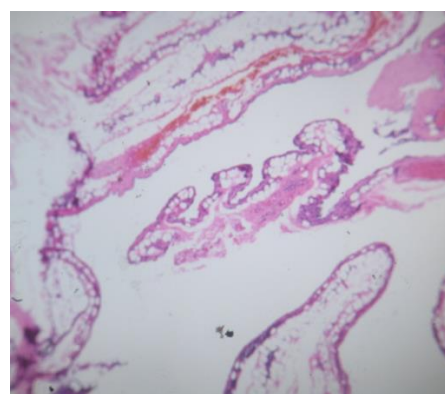


Figure 2. Disruption of fat cells where vacuoles with the remnants of necrotic fat cells are formed

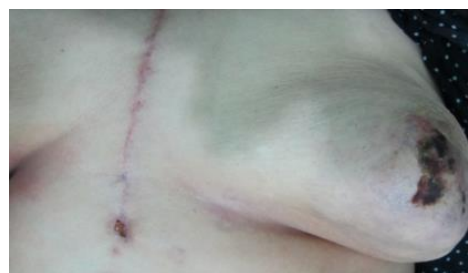

Figure 3. Left breast necrosis

Discussion

After the first report of skin necrosis by warfarin in 1943, less than 40 cases of skin necrosis was detected in the medical literature that in the most of them, WISN occurred following treatment of nonsurgical cases such as pulmonary emboli, or deep vein thrombosis (3). However, the necrosis of the breast tissue is an exceedingly rare complication of warfarin therapy, but its typical occurrence, observed in the middle-aged fatty female that may have a serious consequence. DeFranzo

AJ reports a case of breast necrosis in women receiving warfarin for lung thromboembolic that treated by partial mastectomy (4). Roche-Nagle found a case of WISN in obese females who treated with warfarin for lower extremity deep venous thrombosis, the patient, s breast necrosis was managed by skin debridement and skin graft (5). Warkentin TE reported a case of aortic valve replacement that complicated in the postoperative period by heparin-induced thrombocytopenia. Reaction to both heparin and warfarin lead to digital and breast necrosis (3). Lopez Valle CA exhibited a rare case of bilateral breast necrosis following warfarin therapy that despite warfarin discontinuation, the severity of lesion leads to a bilateral mastectomy (6). The primary sign of WIBN is a well-defined indurated and inflamed area of involved skin which may have bullae and erosion. The erythematous lesion rapidly changes into black and necrotic ecchymoses. Hemorrhagic necrosis of the breast usually continues and develop to gangrene. Typical pathology reveals skin necrosis, bleeding and leaking of small arterioles, a cluster of fibrin deposition in the interstitial tissue and breakdown of small veins, a specific absence of arteriolar thrombosis found in ischemic necrosis (as seen in LIMA harvesting) and absence of intravascular or perivascular inflammatory cells rule out the infection (7). Severe tissue necrosis usually accompanied by inflammatory exudate that appeared as a nonspecific necrosis, sometimes in long hospital stays, secondary bacterial invasion ensues, and the biopsy again showed a non-specific diagnosis. Sometimes arterial thrombosis is less extensive and may closely similar to inflammatory malignancy, and an early biopsy may be a non-exclusive diagnosis. The true etiology of this disease and the cause of its tendency for subcutaneous fat tissue remain an unknown issue but maybe having multiple clinicopathological factors. Chan YC described three local variables in the induction of WISN such as change in local breast temperature, skin injury and local perfusion defect (8). Ad-El DD believes that the history of the previous usage of warfarin is not a predisposition factor for the development of WIBN. Sometimes recurrent skin necrosis occurs despite discontinuation of anticoagulation therapy (9). A case of congenital deficiency of protein C, S was reported by David that leads to breast necrosis (10). Grimaudo reported an acquired deficiency of protein C,S in a case of hepatic failure both acquired and congenital deficiency of these proteins have been reported by others author .In other hand, in some cases , warfarin-necrosis has been occurring in patients with normal levels of these proteins. Reducing large loading doses in

the fatty female is the only preventive measure for skin necrosis following warfarin usage .The necrosis may also be prevented by recognizing high-risk subjects such as diabetes, smoking and opium usage (11). The primary management is a conservative method, discontinuation of coumadin has not been documented to change the outcome of necrosis, but it is generally suggested. Heparin should be an alternative of warfarin and must be started in 1000/unit per hour doses, and the case also received FFP to restore a low serum level of protein C and S. Withholding of warfarin and substitution of heparin, the lesions have a time for evolution so during of this course two steps of healing including fibrosis, scarring, and spontaneous healing ensued. In the recurrence case of WIBN, the clinician should start a heparin therapy via the subcutaneous method in cases of valve replacement or others long term user of warfarin. In rare cases as in the report of Haynes, warfarin was reintroduced after healing necrosis and recurrence of the lesion was not found (12). If we allow the patients to spend their natural course, the complication is accompanied by high morbidity and mortality. Typically, WIBN does not respond to medical treatment, and extensive debridement is needed in half of the cases. Final results are usually obtained by secondary fibrosis, skin grafting or myocutaneous skin flap coverage (13-17).

In conclusion, three differential diagnosis should be considered in a confrontation with a breast mass following cardiac surgery. Ischemic necrosis that is seen following Lima usage in older women with low body mass index. the second diagnosis is an infection that may be a primary lesion or overwhelmed over the previous pathologies such as fibroadenoma, fibrocystic disease or carcinoma, and the last pathology may be a WIBN.

References

1. Esmon CT. The roles of protein C and thrombomodulin in the regulation of blood coagulation. *J Biol Chem* 1989;264:4743-6.
2. Warkentin TE, Whitlock RP, Teoh KH. Warfarin-associated multiple digital necrosis complicating heparin-induced thrombocytopenia and Raynaud's phenomenon after aortic valve replacement for adenocarcinoma-associated thrombotic endocarditis. *Am J Hematol* 2004;75:56-62.
3. Isenberg JS, Tu Q, Rainey W. Mammary gangrene associated with warfarin ingestion. *Ann Plast Surg* 1996;37:553-5.

Warfarin-induced breast necrosis

4. DeFranzo AJ, Marasco P, Argenta LC. Warfarin-induced Necrosis of the Skin. *Ann Plast Surg* 1995;34:203-8.
5. Roche-Nagle G, Robb W, Ireland A, Bouchier-Hayes D. Extensive skin necrosis associated with warfarin sodium therapy. *Eur J Vasc Endovasc Surg* 2003;25:481-2.
6. Lopez Valle CA, Hebert G. Warfarin-induced complete bilateral breast necrosis. *Br J Plast Surg* 1992;45:606-9
7. Esmon CT, Vigano D'Angelo S, D'Angelo A, Comp PC. Anticoagulation proteins C and S. In: Wessler S, Becker CG, Nemerson Y, eds. *Advances in Experimental Medicine and Biology*. New York: Plenum Press, 1987:479.
8. Chan YC, Valenti D, Mansfield AO, Stansby G. Warfarin induced skin necrosis. *Br J Surg* 2000;87:266-72.
9. Ad-El DD, Meirovitz A, Weinberg A, Kogan L, Arieli D, Neuman A, et al. Warfarin skin necrosis: Local and systemic factors. *Br J Plast Surg* 2000;53:624-6.
10. David CE, Jr, Wiley WB, Faulconer RJ. Necrosis of the female breast complicating oral anticoagulant treatment. *Ann Surg* 1972;175:647.
11. Grimaudo V, Gueissaz F, Hauert J, Sarraj A, Kruihof EK, Bachmann F. Necrosis of skin induced by coumarin in a patient deficient in protein S. *Br J Med* 1989;298:233-4.
12. Haynes CD, Mathews JW, Swaltney N, Lazenby WD. Breast necrosis complicating anticoagulation therapy. *South Med J* 1983;76:1091-3.
13. Heaton RB, Wright LS, Hargraves RW, Kragel PJ. Coagulopathy and warfarin-associated breast necrosis in a patient with a primary brain tumor. *Surg Neurol* 1990;33:395-9.
14. Kagan RJ, Glassford GH. Coumadin-induced breast necrosis. *Am Surg* 1981;47:509-10.
15. Kahn S, Stern HD, Rhodes GA. Cutaneous and subcutaneous necrosis as a complication of Coumarin-congener therapy. *Plast Reconstr Surg* 1971;48:160-6.
16. Kiehl R, Hellstern P, Wenzel E. Hereditary antithrombin III deficiency and atypical localization of coumarin necrosis. *Thromb Res* 1987;45:191-3.